

The background of the slide is a light gray gradient with several realistic water droplets of various sizes scattered across it. The droplets have highlights and shadows, giving them a three-dimensional appearance.

Vascular Scanning Secrets

Janette Wybo, BAS, RDMS, RDCS, RVT

Clinical Coordinator

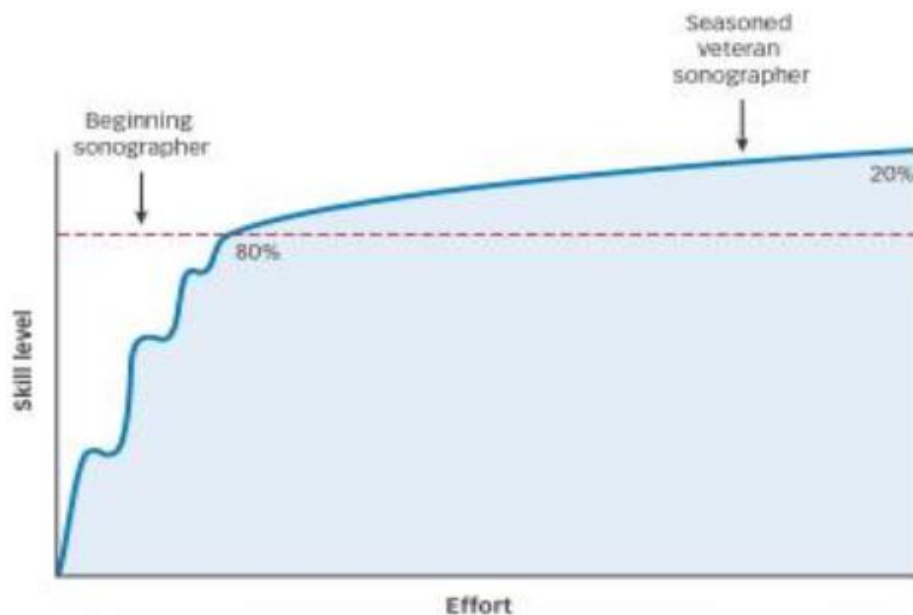
Providence Hospital School of
Diagnostic Medical Sonography

Objectives

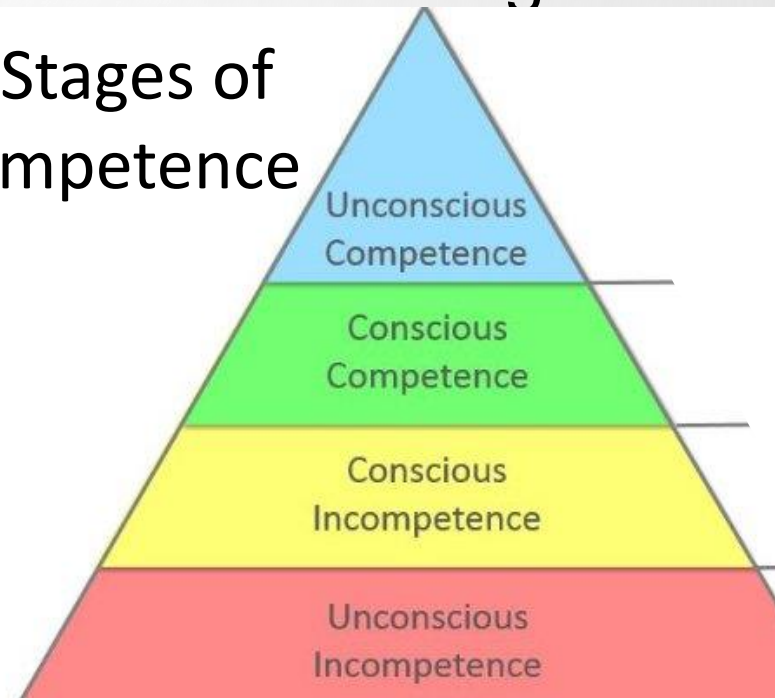
- List fundamentals of vascular scanning
- Describe optimizing scanning techniques
- How to overcome challenges
- Identification of structures used to locate vascular anatomy
- Demonstrate best practices for vascular scanning

There is a learning curve to vascular scanning!

- First 80% of skills come quickly
- Last 20% is real proficiency and often takes longer
- Often frustration comes before a breakthrough!



4 Stages of Competence

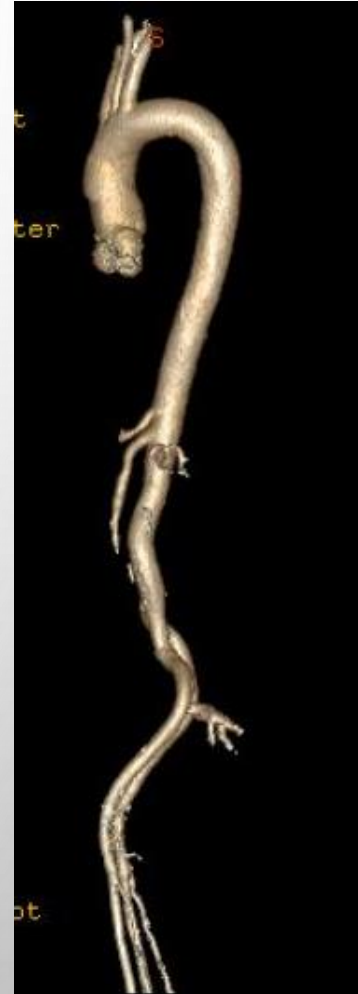

For Beginners

- Know the anatomy and physiology of arterial and venous systems, but be prepared for unique anatomy
- Know your protocol - LONG, TRANS, COLOR and DROP the DOPPLER
- Know how to optimize your images – but be prepared to push buttons outside your preset
- Know the limits of your exam

Really want to learn vascular?

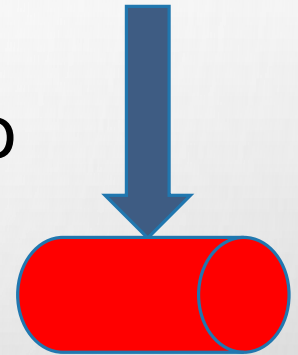
- Look up how your exams were dictated and correlate with other studies (CT, MR, x-rays and angiograms)
- Click on other imaging modalities, ask to observe in the radiology to watch exams
- Be inquisitive - watch YouTube on surgeries, angiograms and angioplasties to get the FULL picture!



Scanning Secret #1

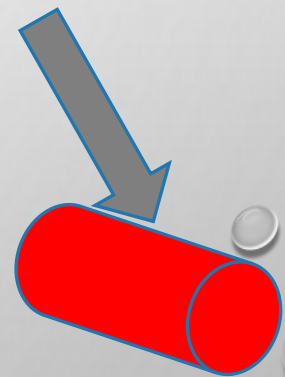
2D – Use windows!

Direct transducer more perpendicular to
area of interest



Color

Direct transducer more parallel to
area of interest and flow

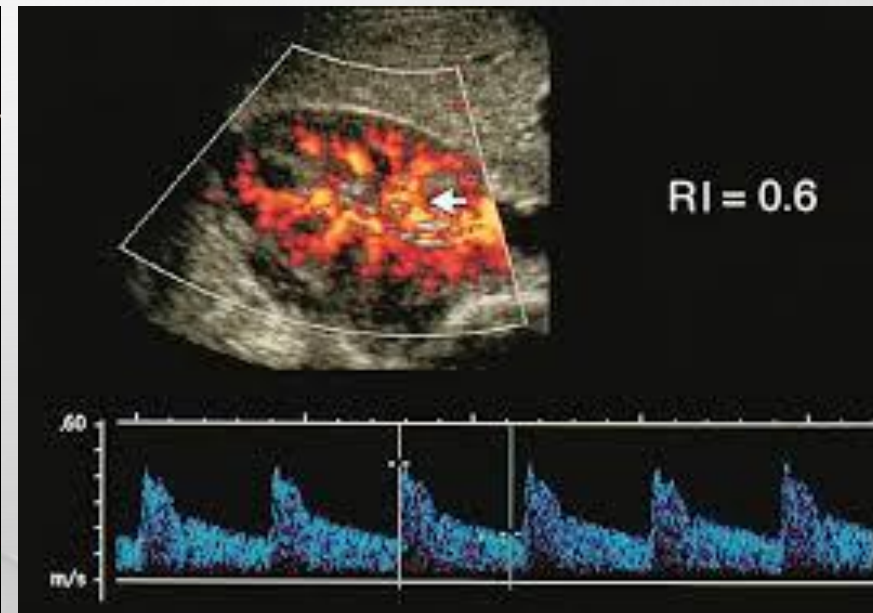
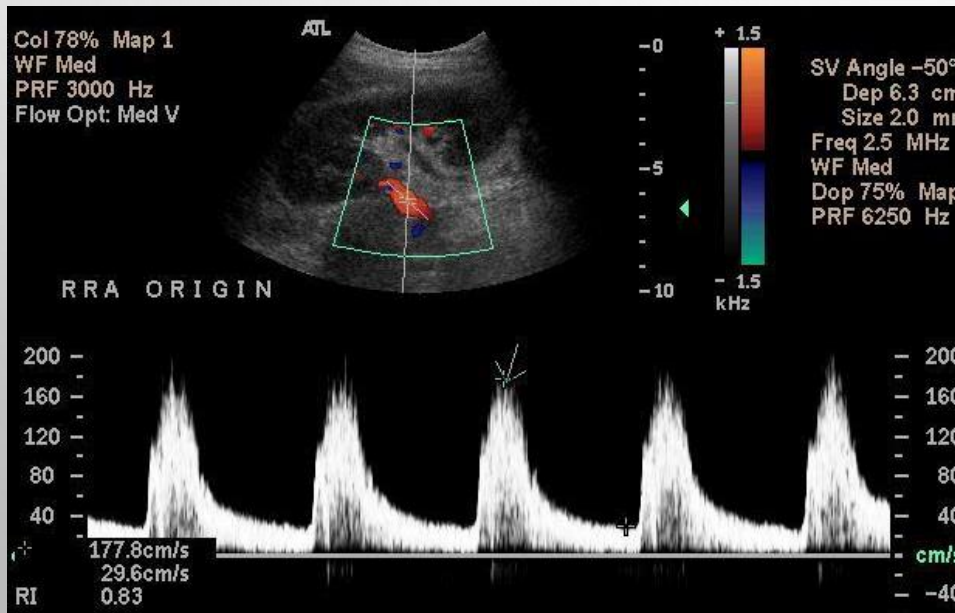


Scanning Secret #2

Doppler Spectrum

Color and Doppler spectrum should always make sense!

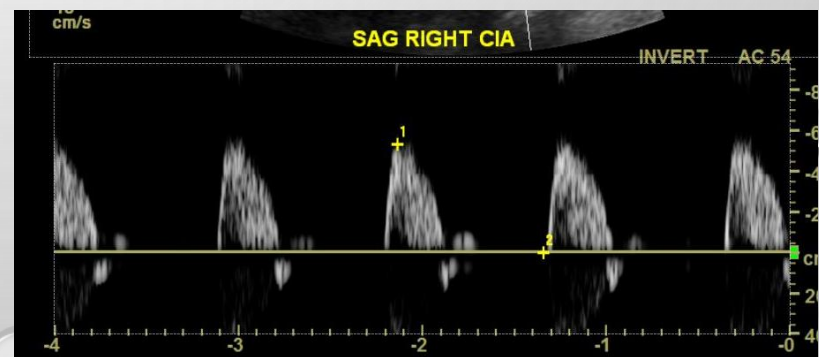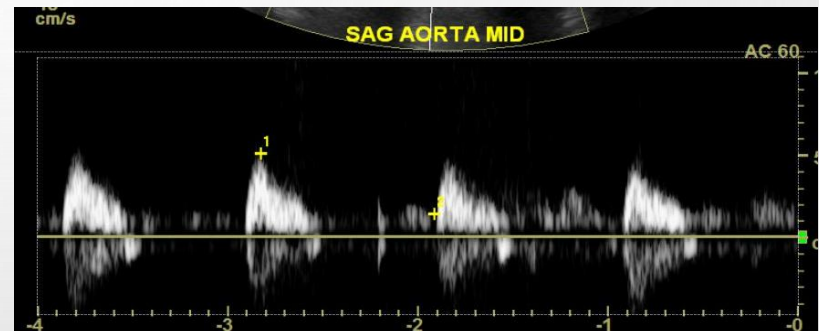
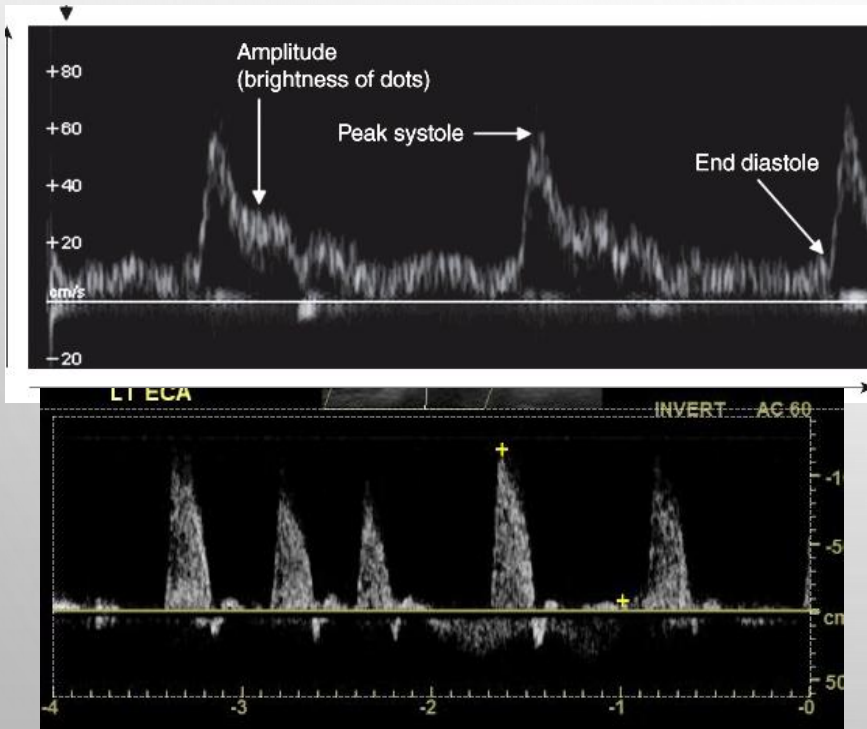
- When you need numbers (PSV, EDV) must angle correct
- When you need if low or high resistive - don't need to angle correct



Scanning Principle #3

Measure Doppler Correctly

- Measure PSV at highest point during systole
- Measure EDV just before onset of systole (never before)
- Don't measure the highest PSV with arrhythmia



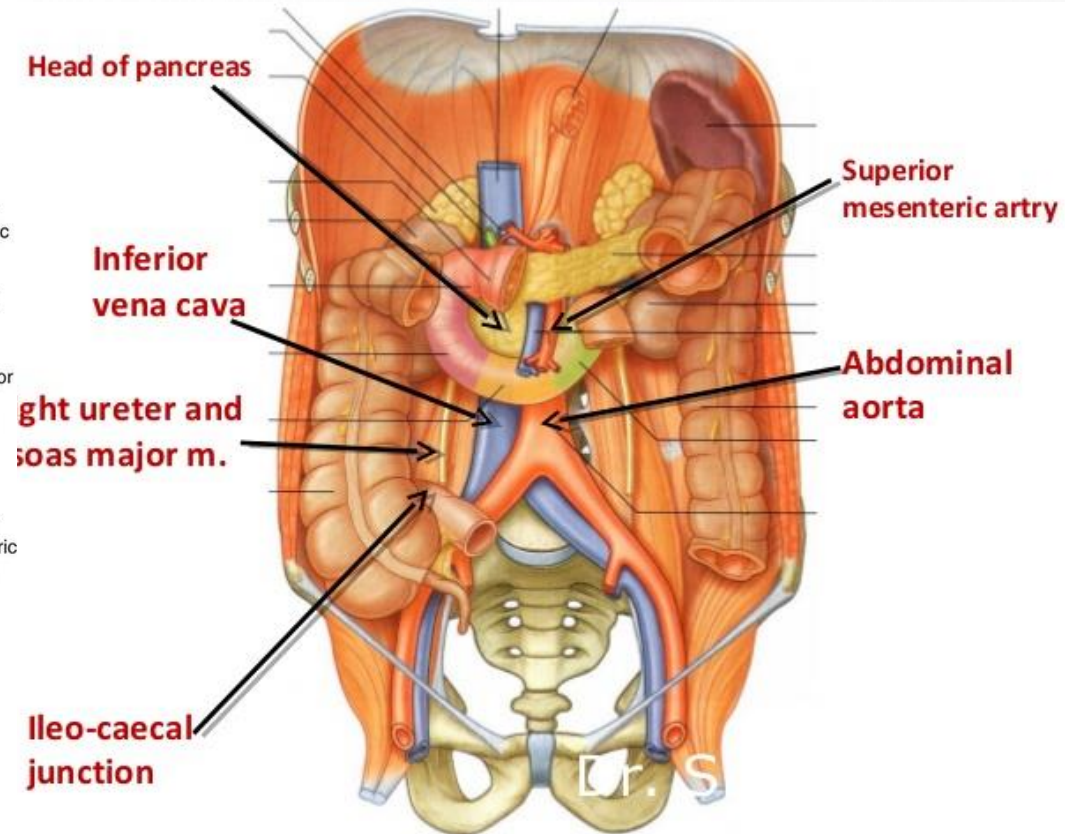
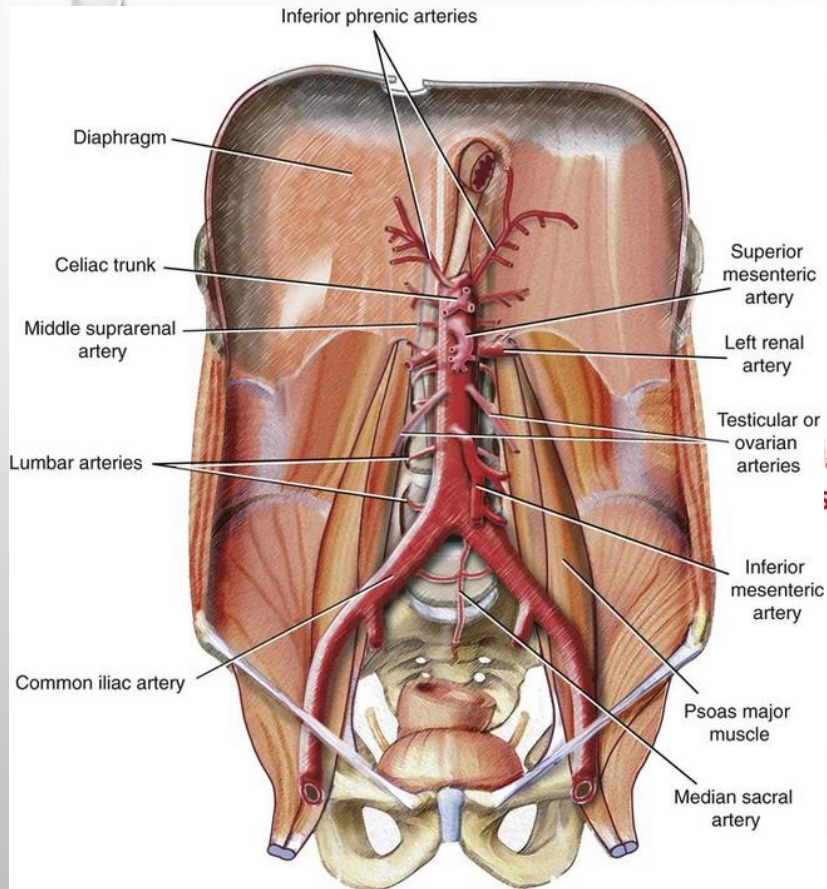
Scanning Secret #4

- If things don't make sense - let someone know!
- It is ok to let your radiologist or vascular surgeon know you are confused, but you did your best to figure it out.
- Take a cine clip, document long/trans, use color and Doppler

The background of the slide is a light gray gradient with several realistic water droplets of various sizes scattered across it. The droplets have highlights and shadows, giving them a three-dimensional appearance. The text is centered in the middle of the slide.

Let's Apply the Secrets to the Abdominal Aorta

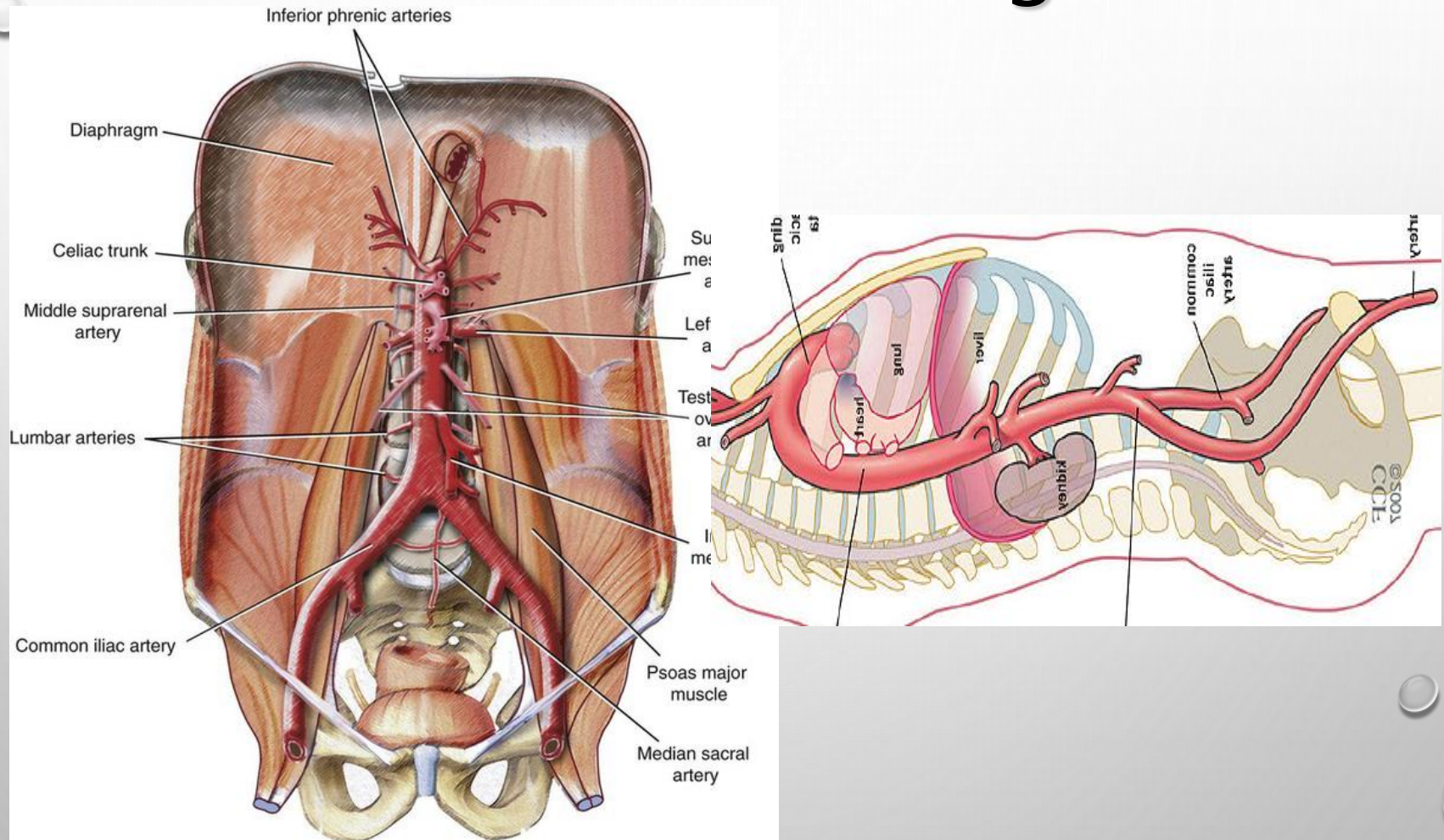
Abdominal Aorta Anatomy



<https://radiologykey.com/abdominal-aorta-and-the-inferior-vena-cava/>

<http://heritance.me/anatomy-of-jejunum-and-ileum/anatomy-of-jejunum-and-ileum-the-abdomen-3>

Look at different diagrams



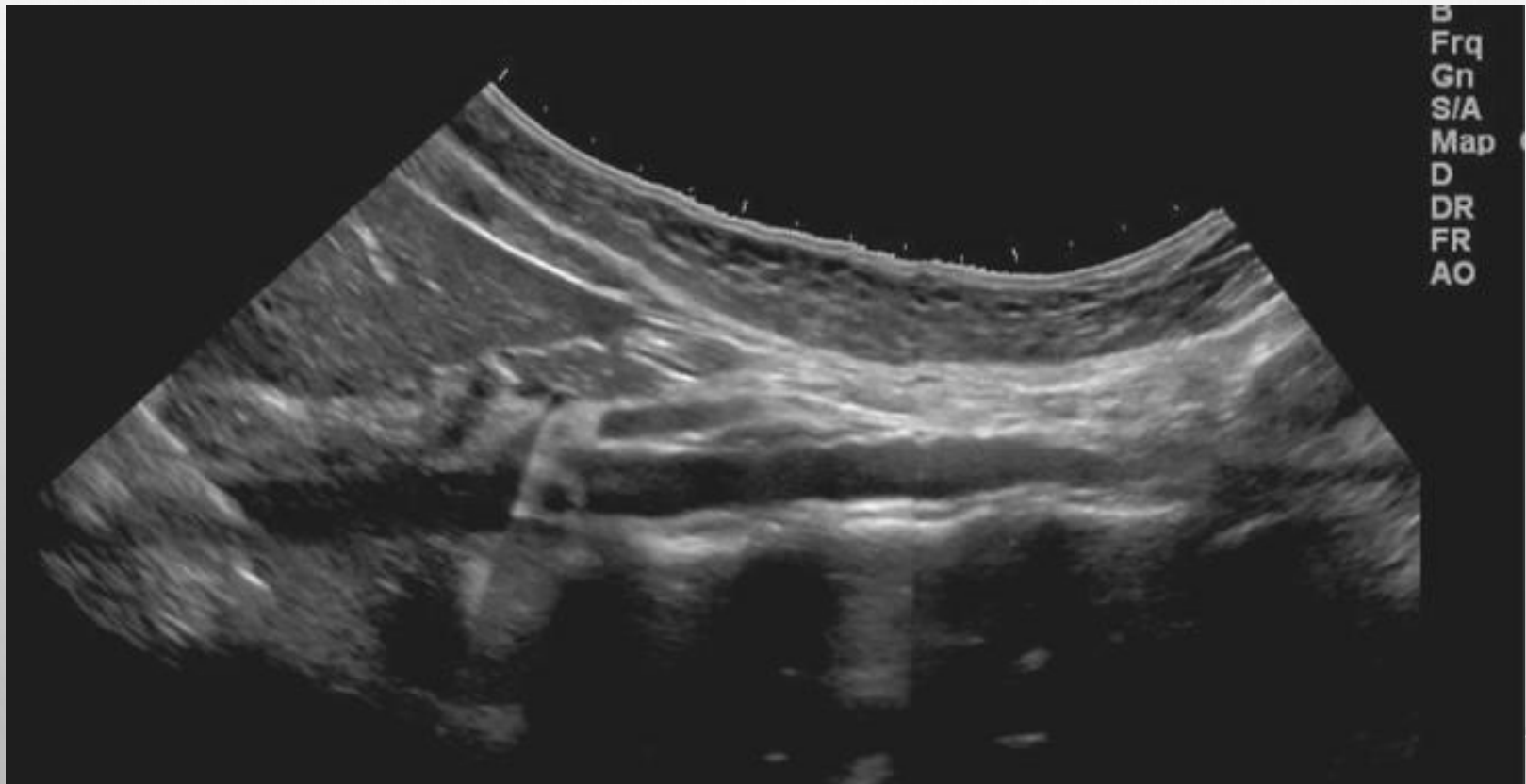
<https://radiologykey.com/abdominal-aorta-and-the-inferior-vena-cava/>

<http://heritance.me/anatomy-of-jejunum-and-ileum/anatomy-of-jejunum-and-ileum-the-abdomen-3>

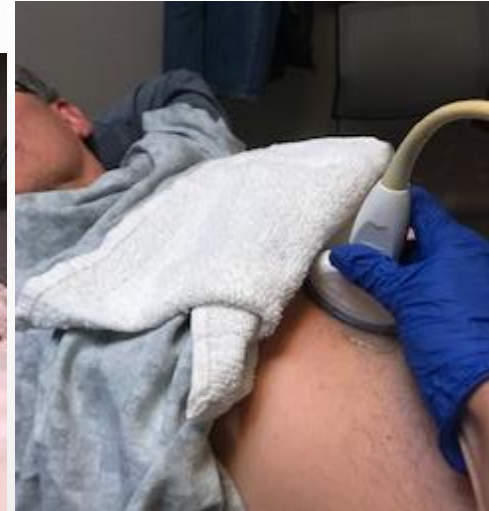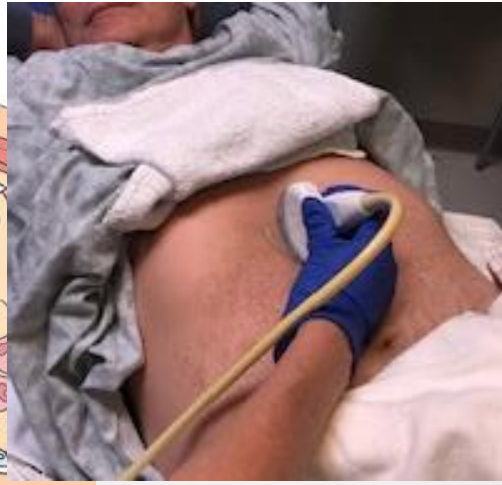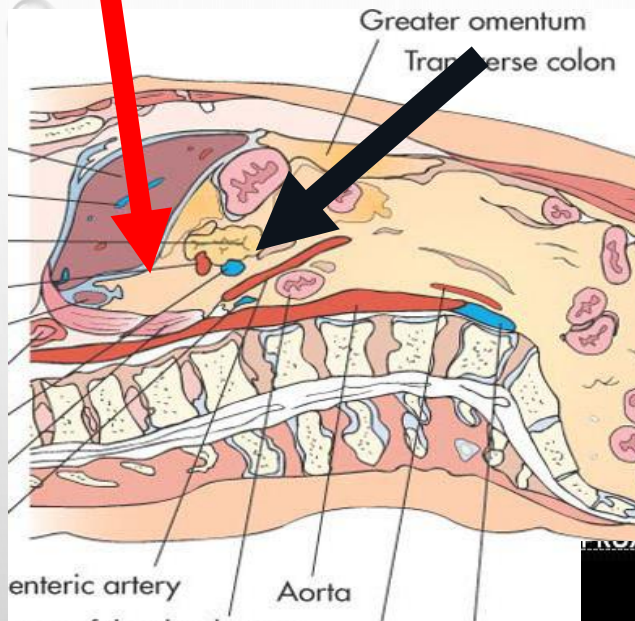
Scanning the Abdominal Aorta

Challenge to visualize all segments

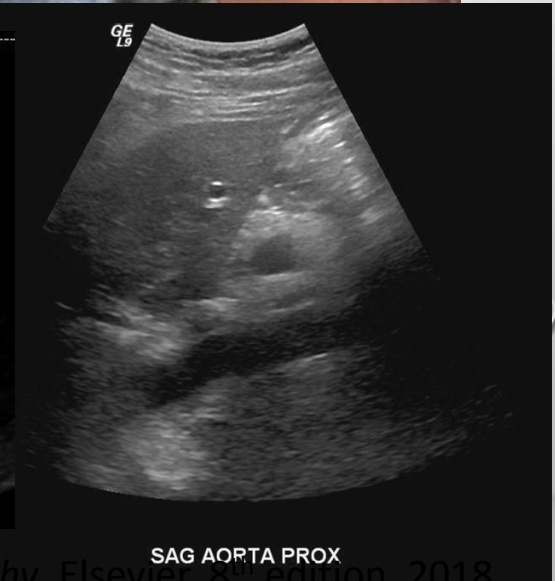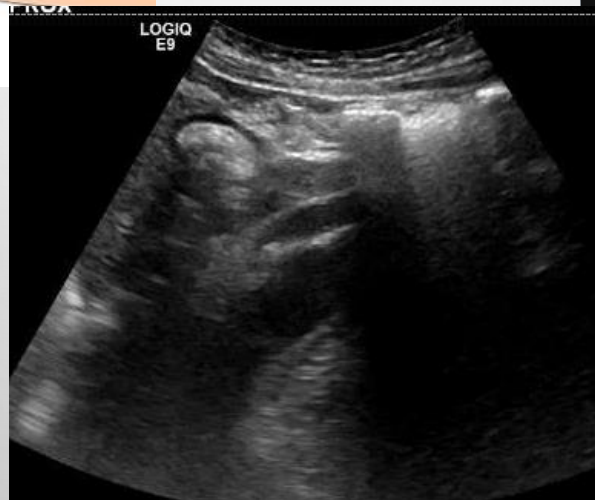Prox, mid distal and bifurcation



2D direct perpendicular to PROX aorta



Don't angle
cephalic for
Prox Ao



Sagittal Proximal Aorta without and with deep Breath

ENCE HOSPITAL
11:30:12 AM JJ

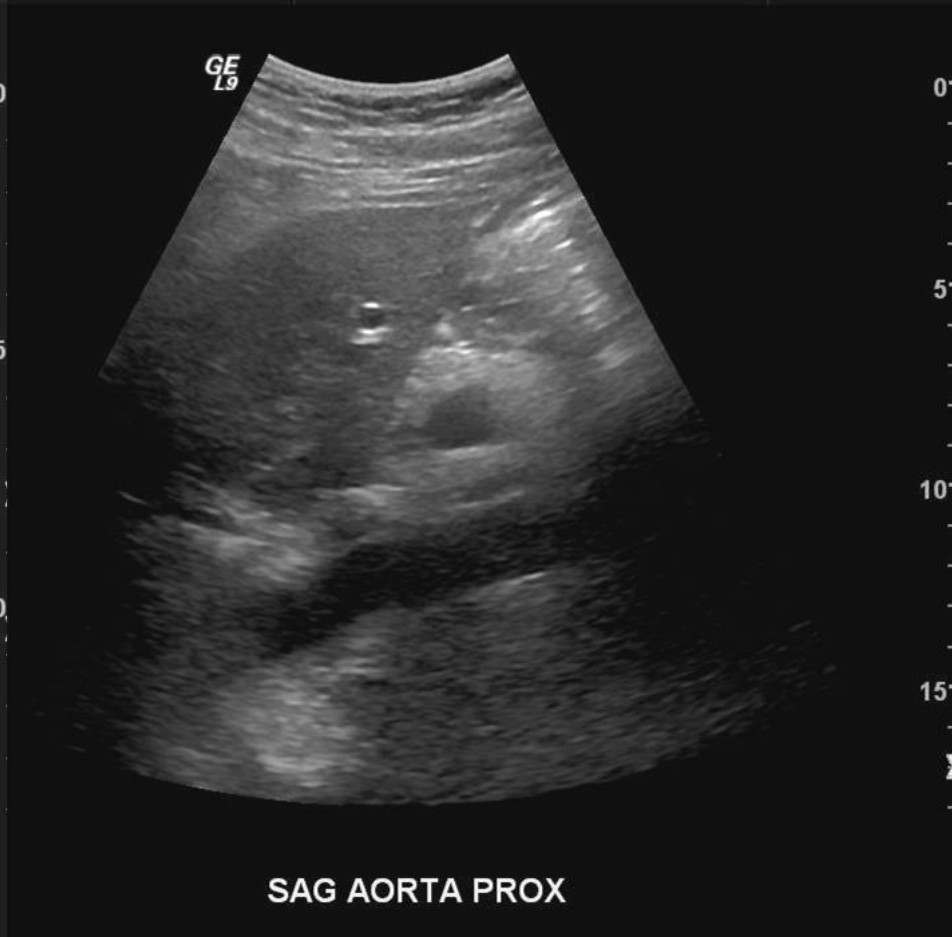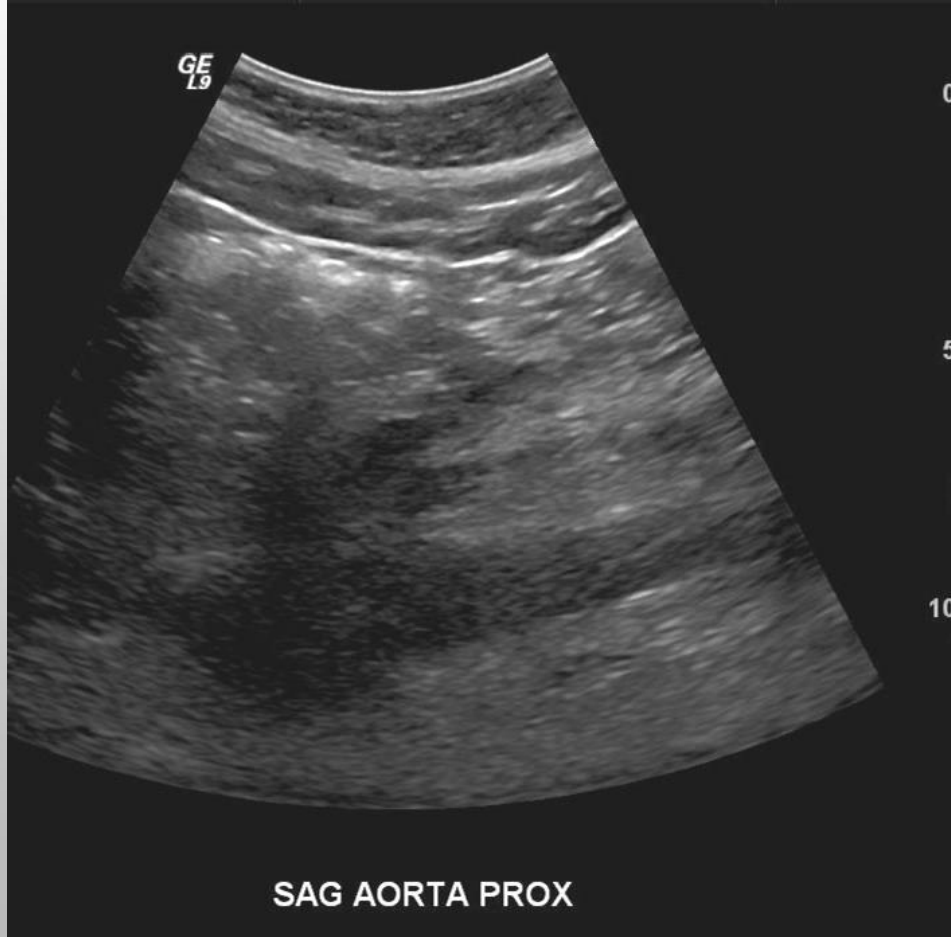WYBO, DAVID
JW123456

MI 0.4 TIs 0
--:--:--

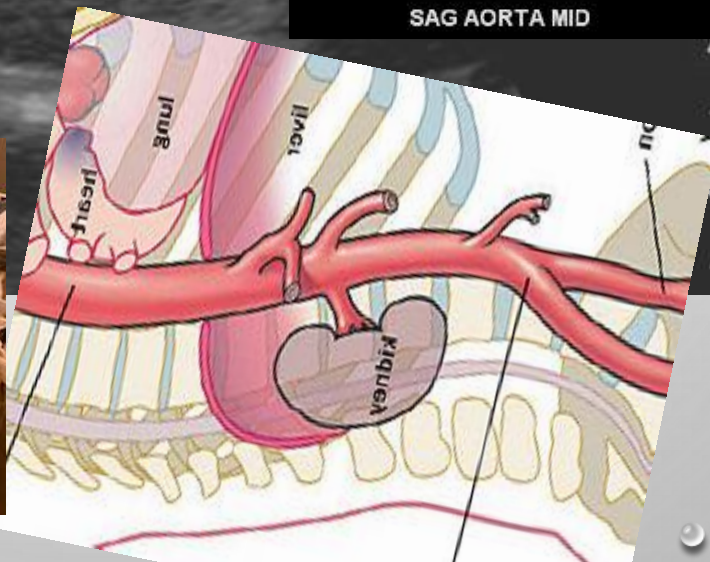
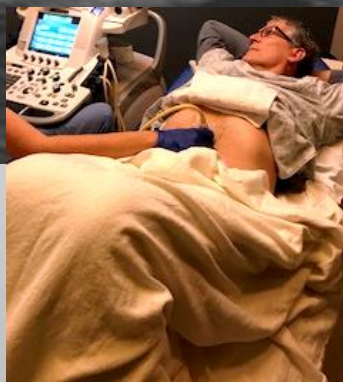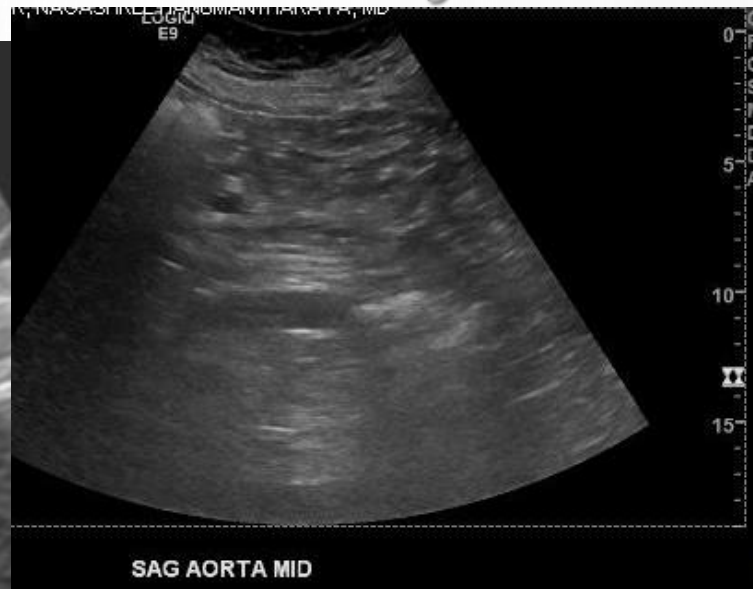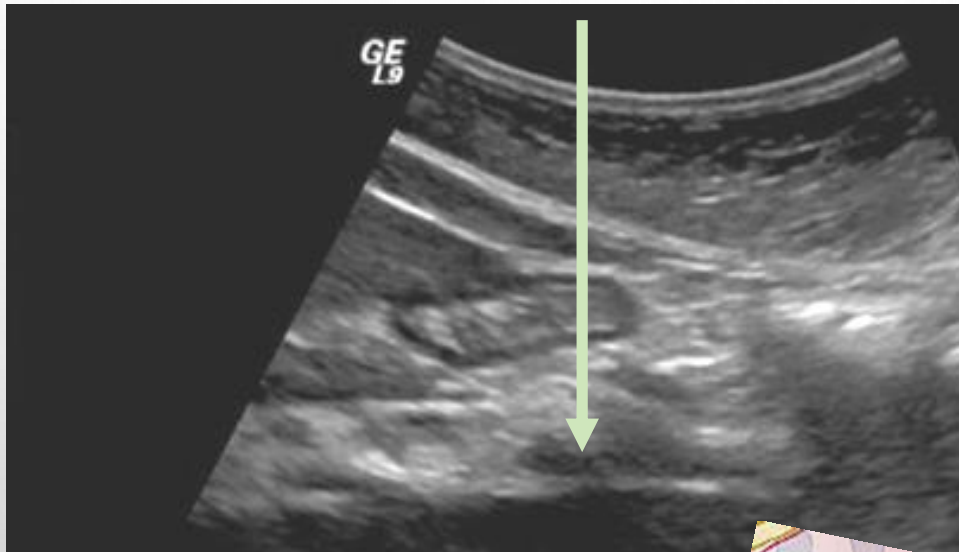
ENCE HOSPITAL
11:31:18 AM JJ

WYBO, DAVID
JW123456

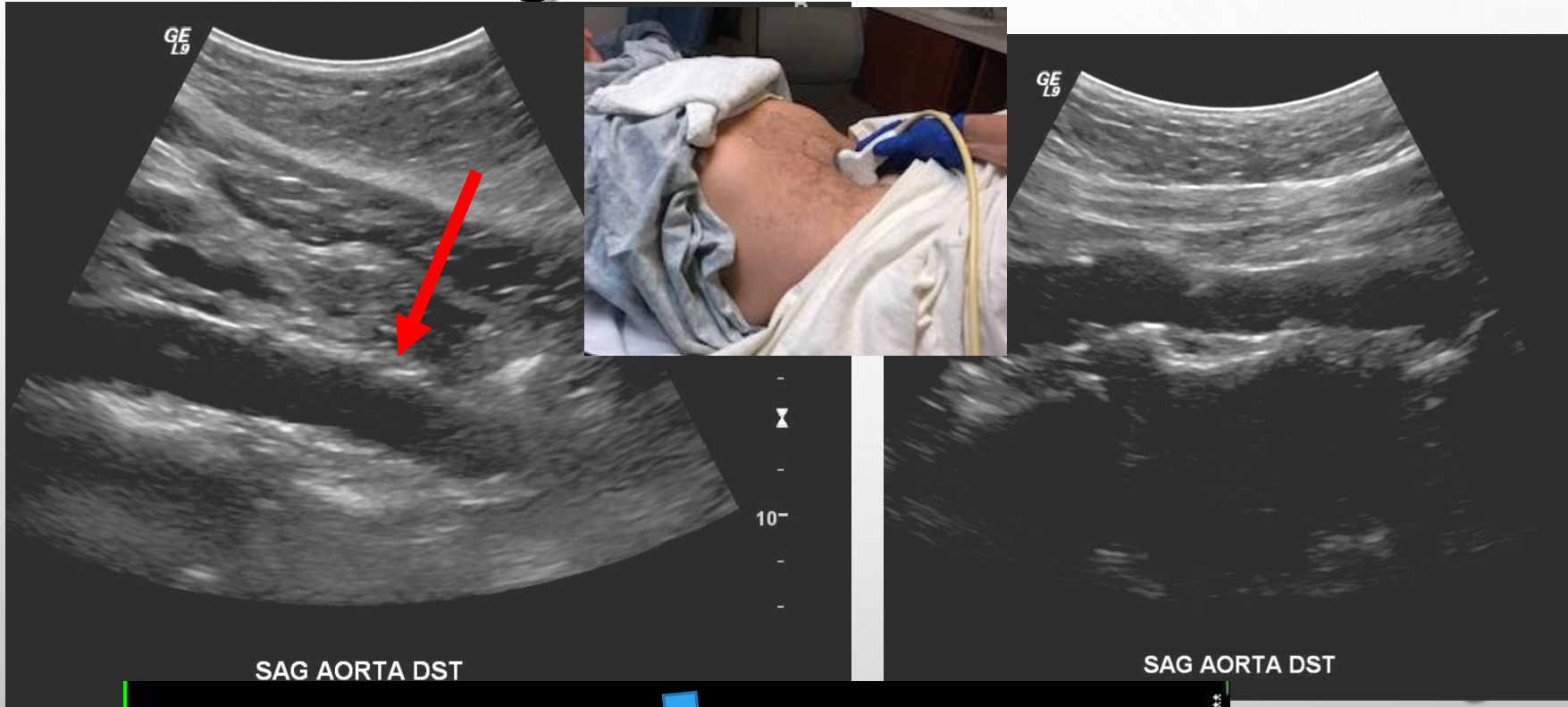
MI 0.8 TIs 0
--:--:--



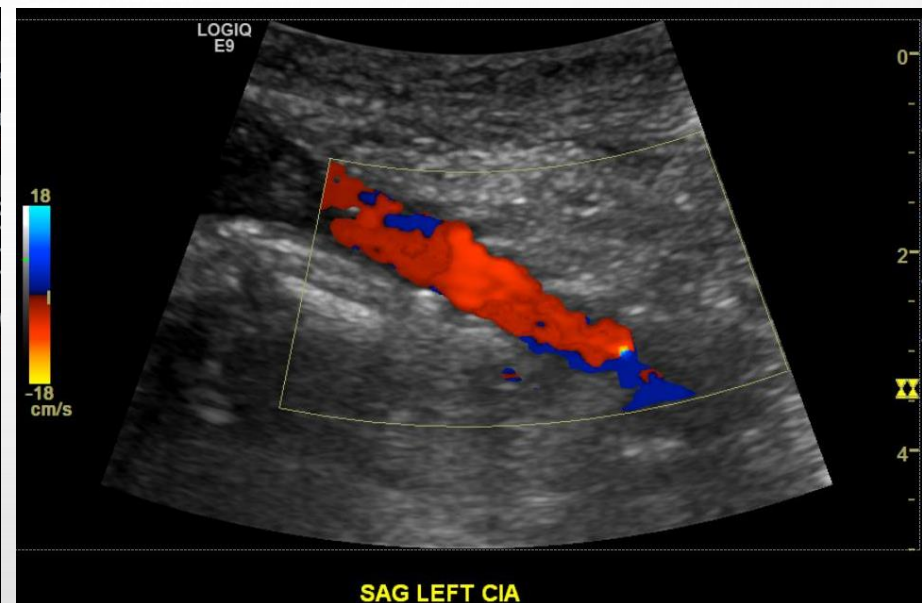
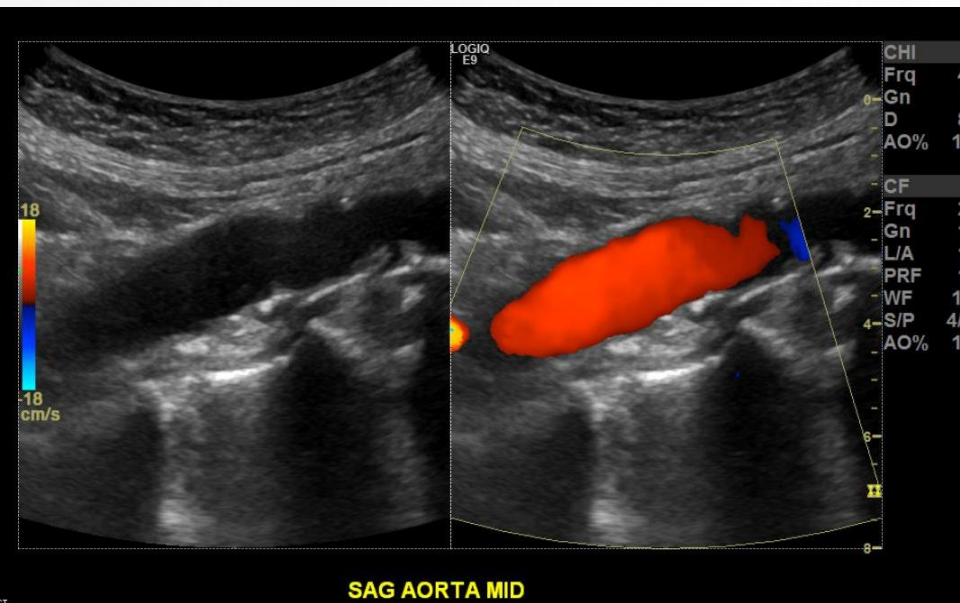Bend knees for perpendicular approach as mid Aorta curves anteriorly



Direct transducer more cephalic for 2D images of diving common iliacs

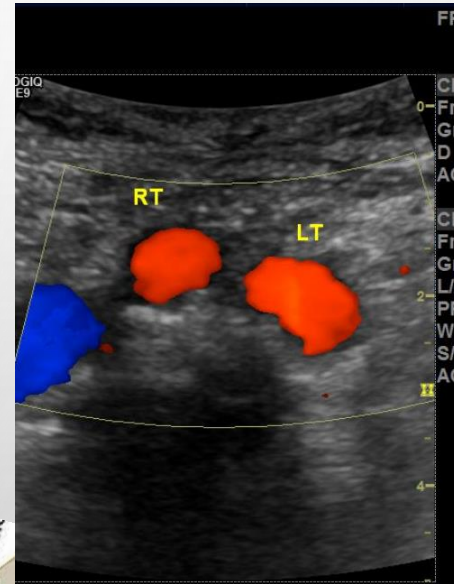
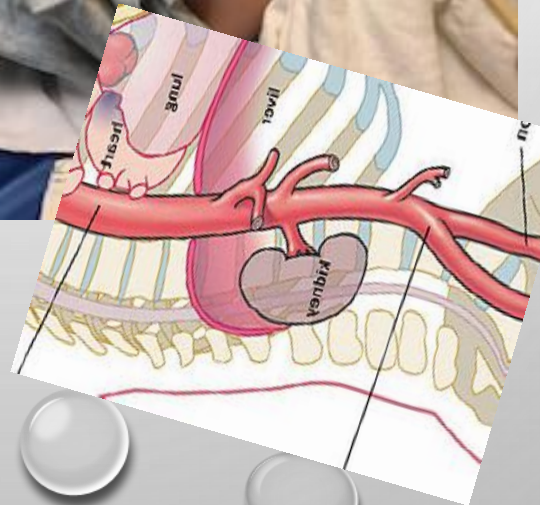
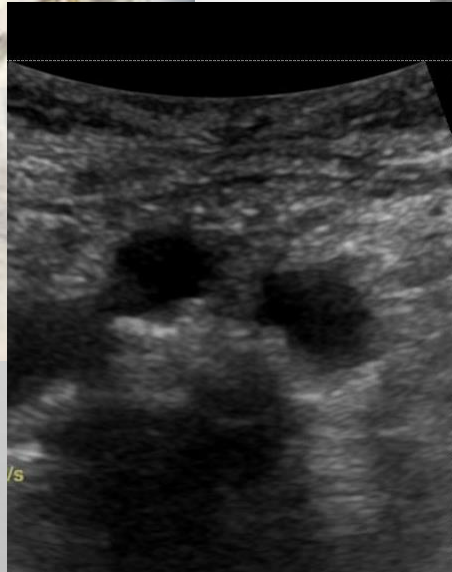
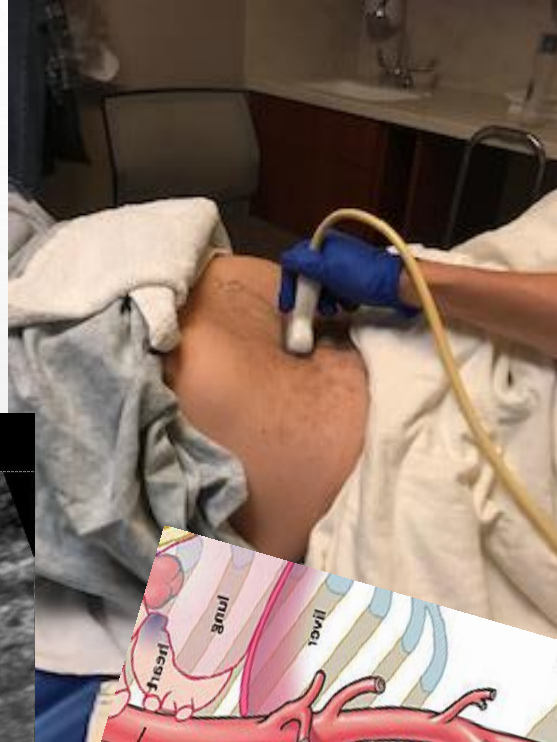
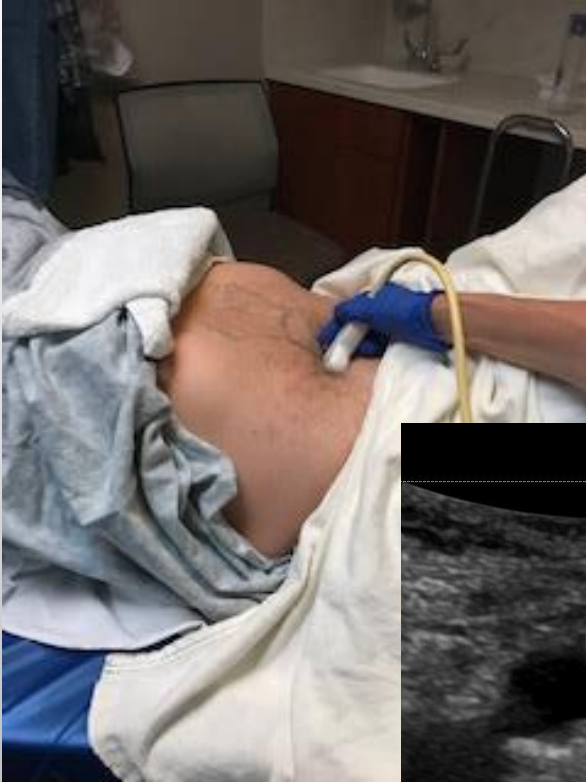
Angle into flow for color Make vessels more diagonal

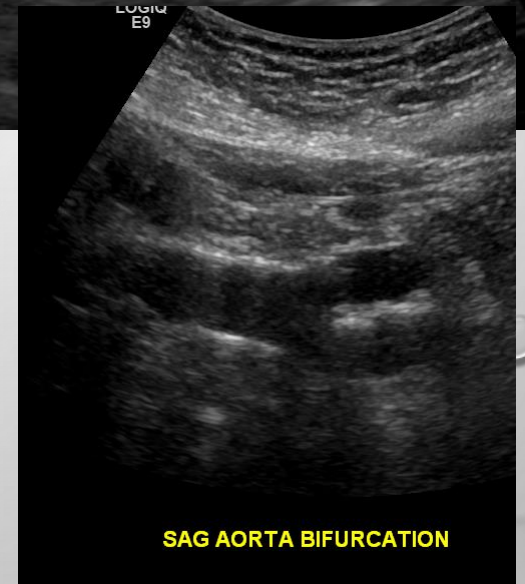
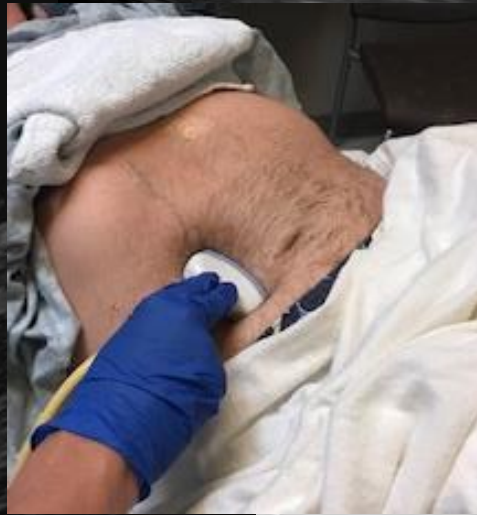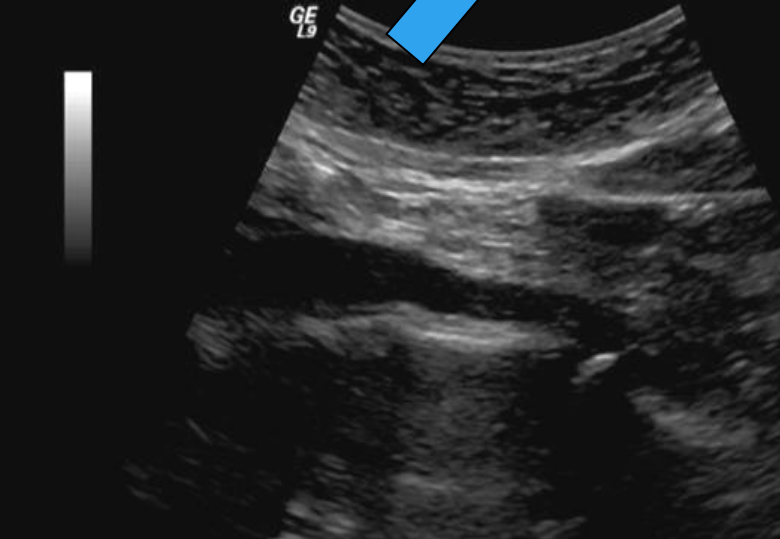
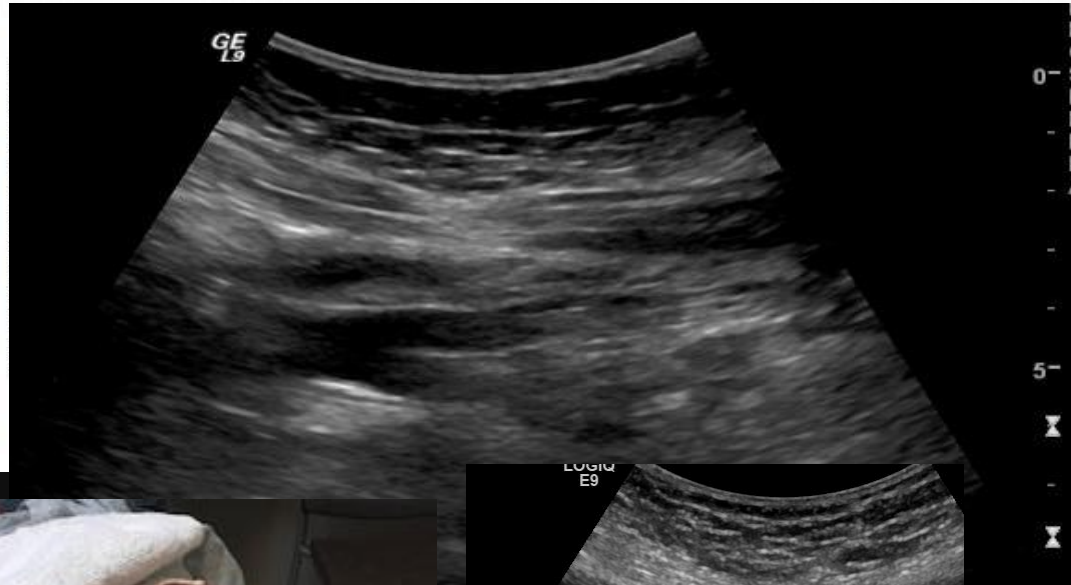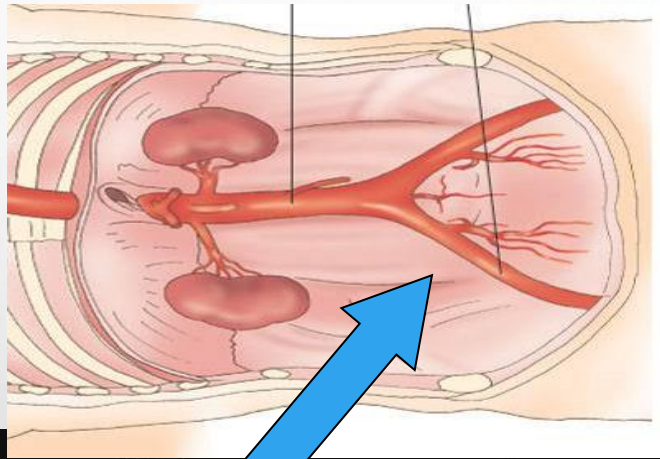


Transverse bifurcation

2D image angle towards the head
color image may angle inferiorly

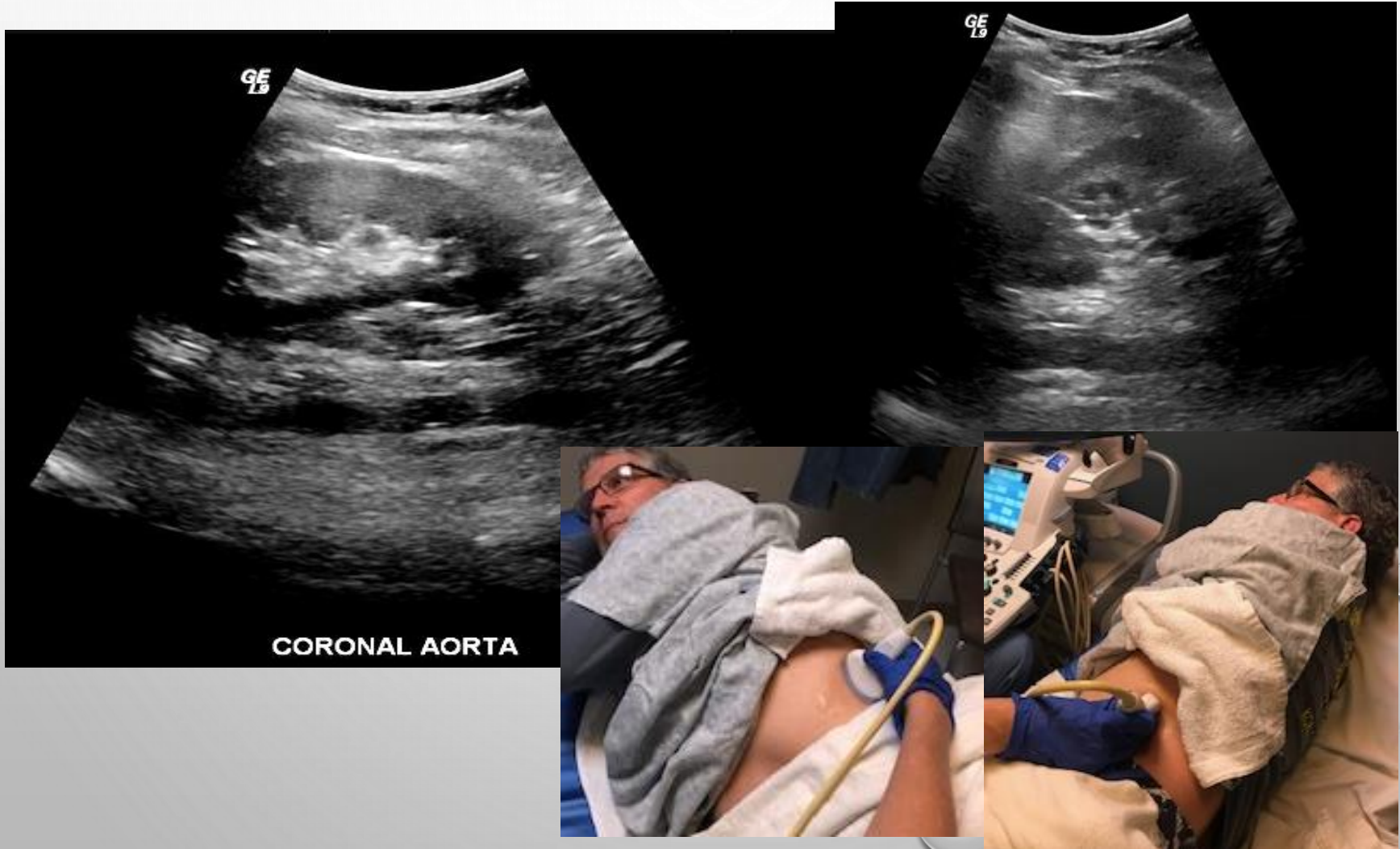

Sag oblique approach for bifurcation at level of umbilicus

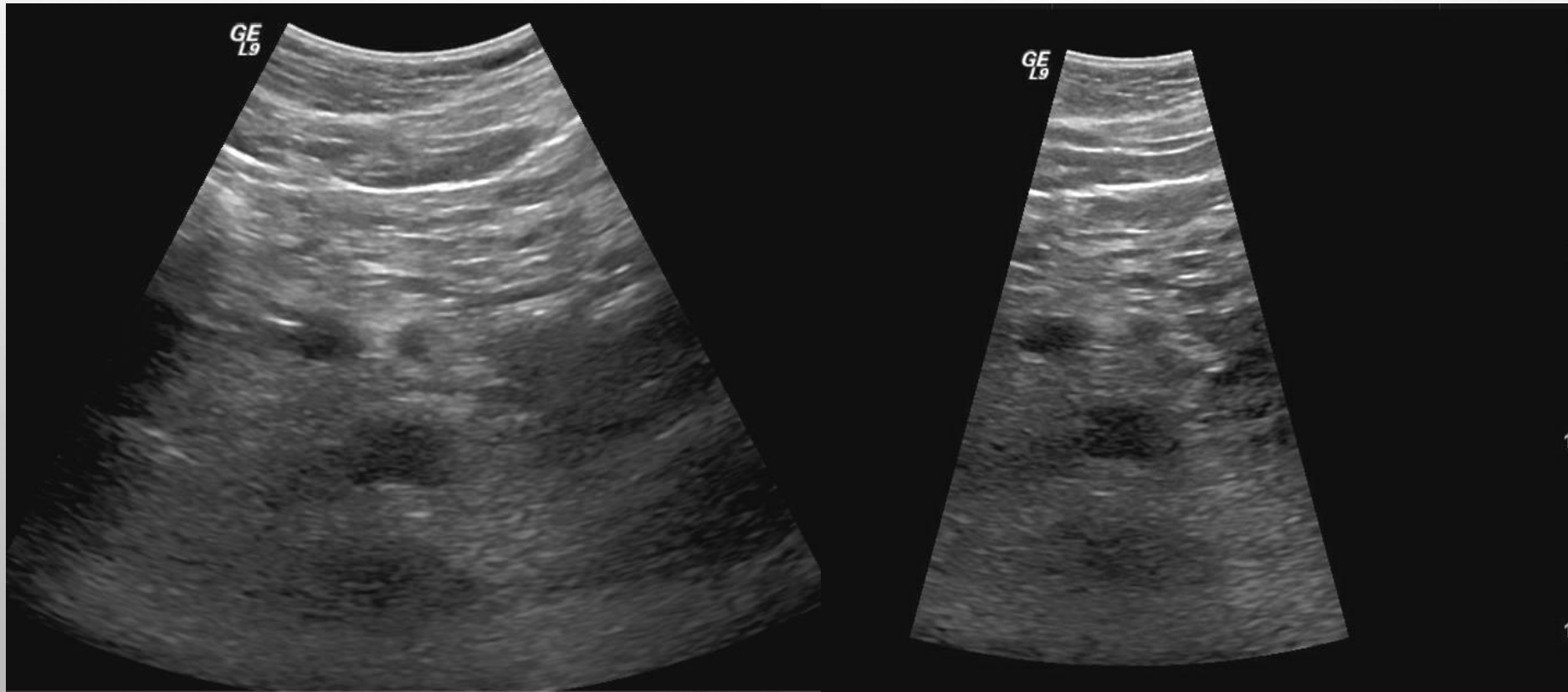
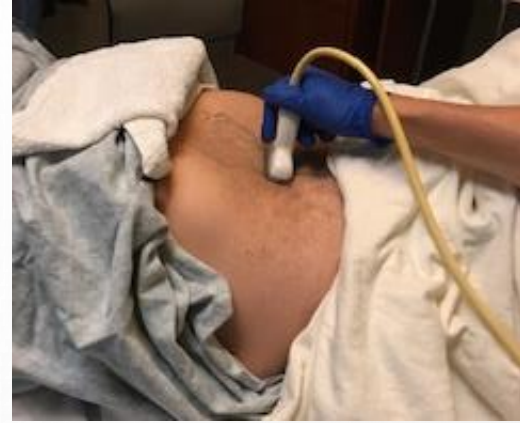

Use Lt kidney as window for Aorta

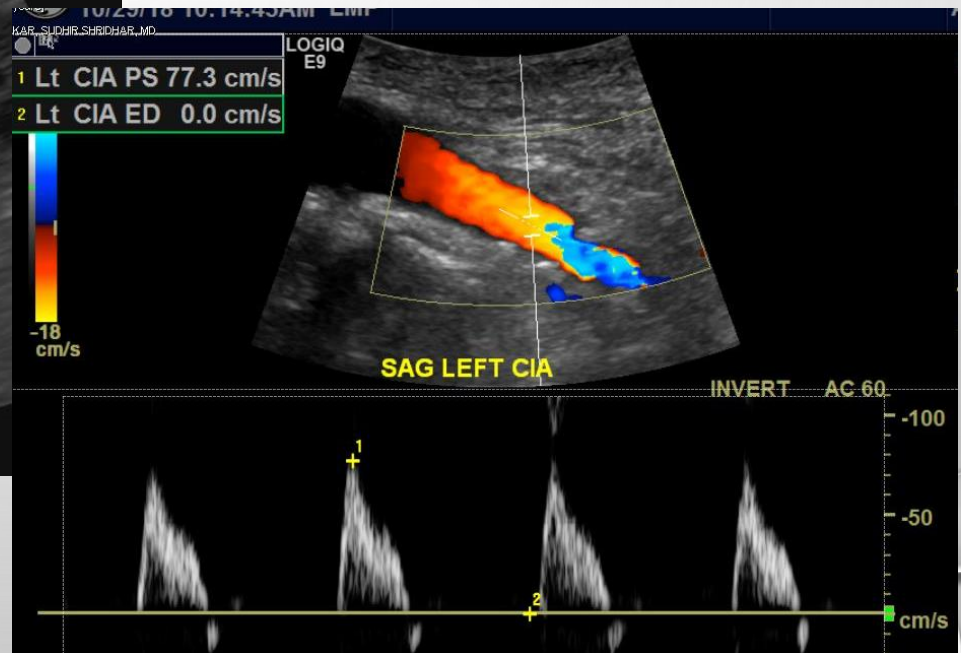
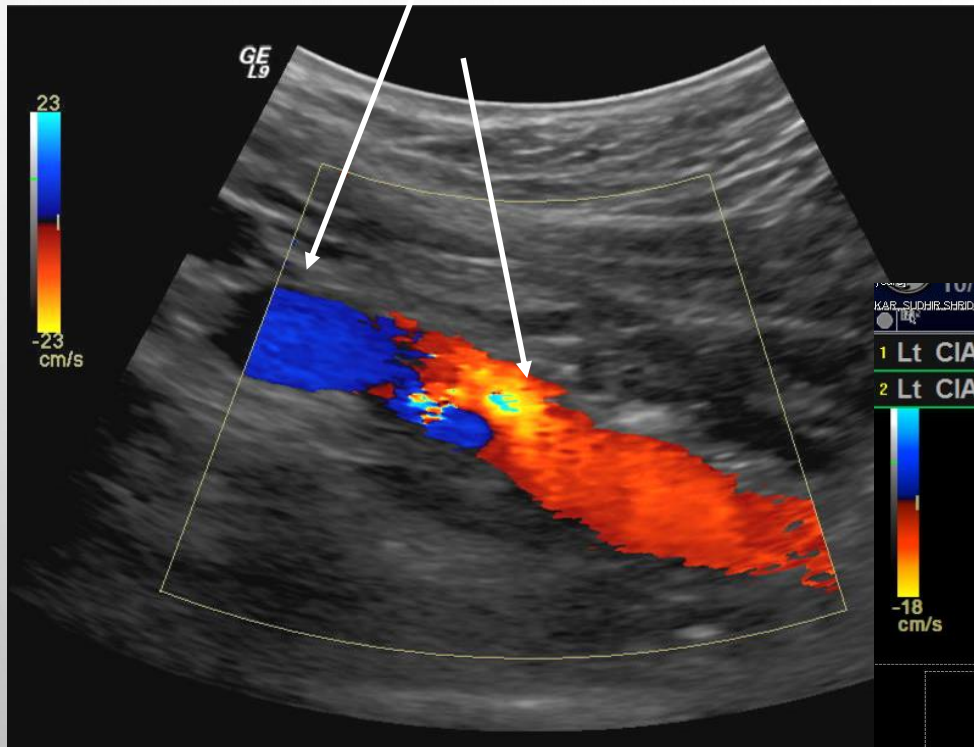
Left coronal approach with RLD position



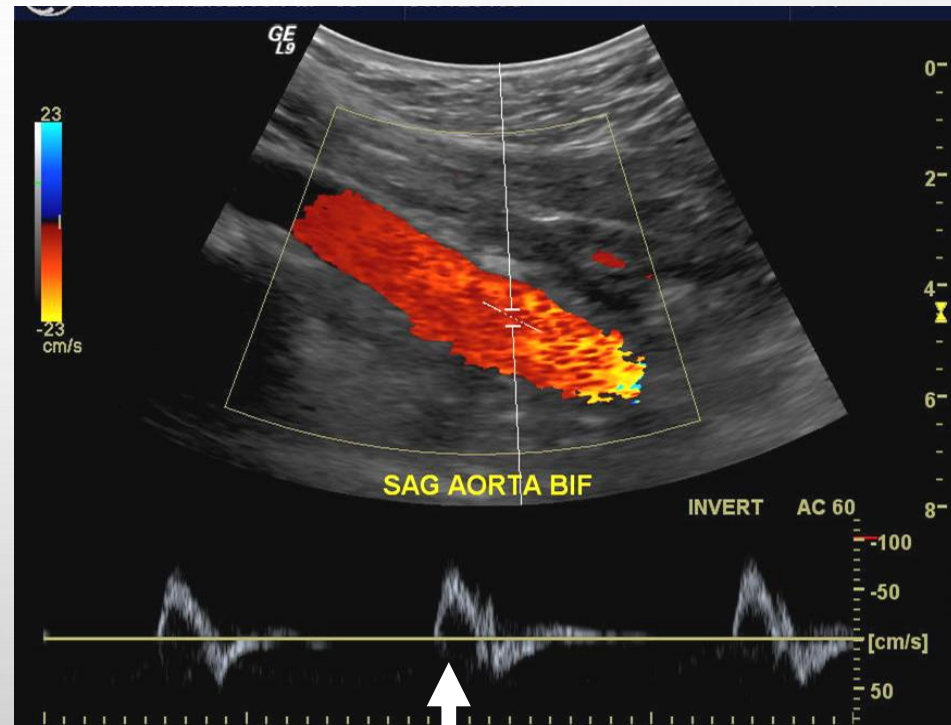
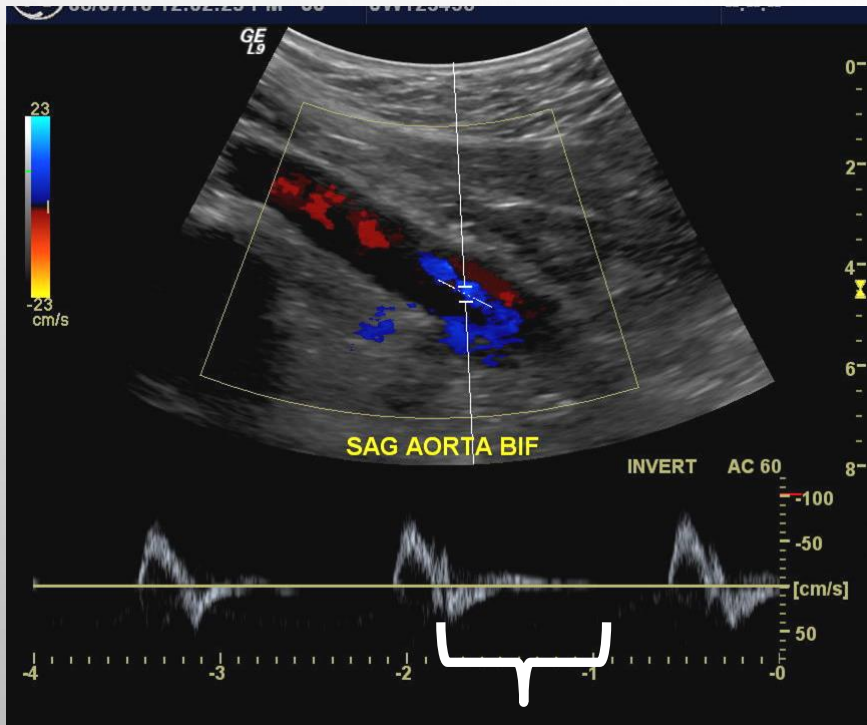
Use machine
knowledge to
optimize image



Use natural curves and oblique angles to direct more parallel to flow



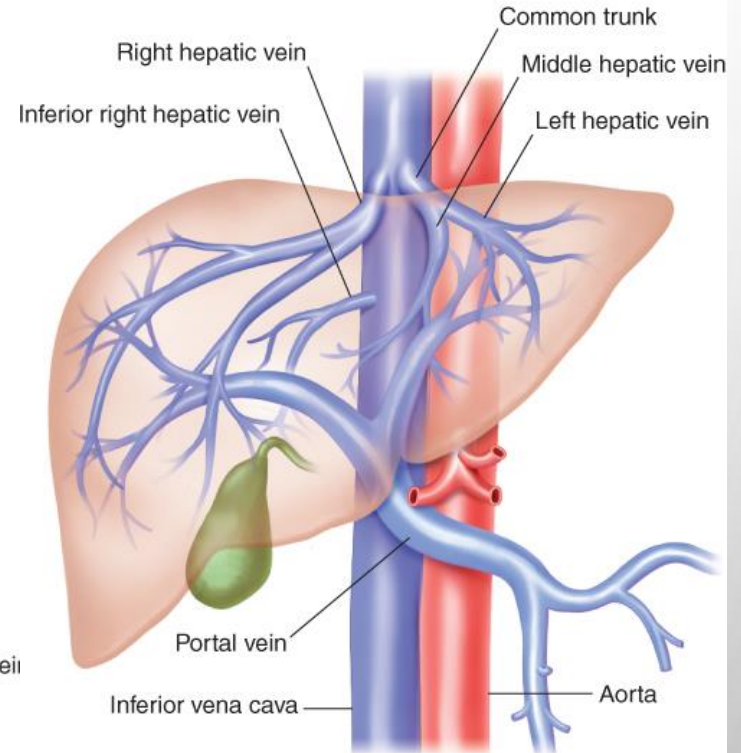
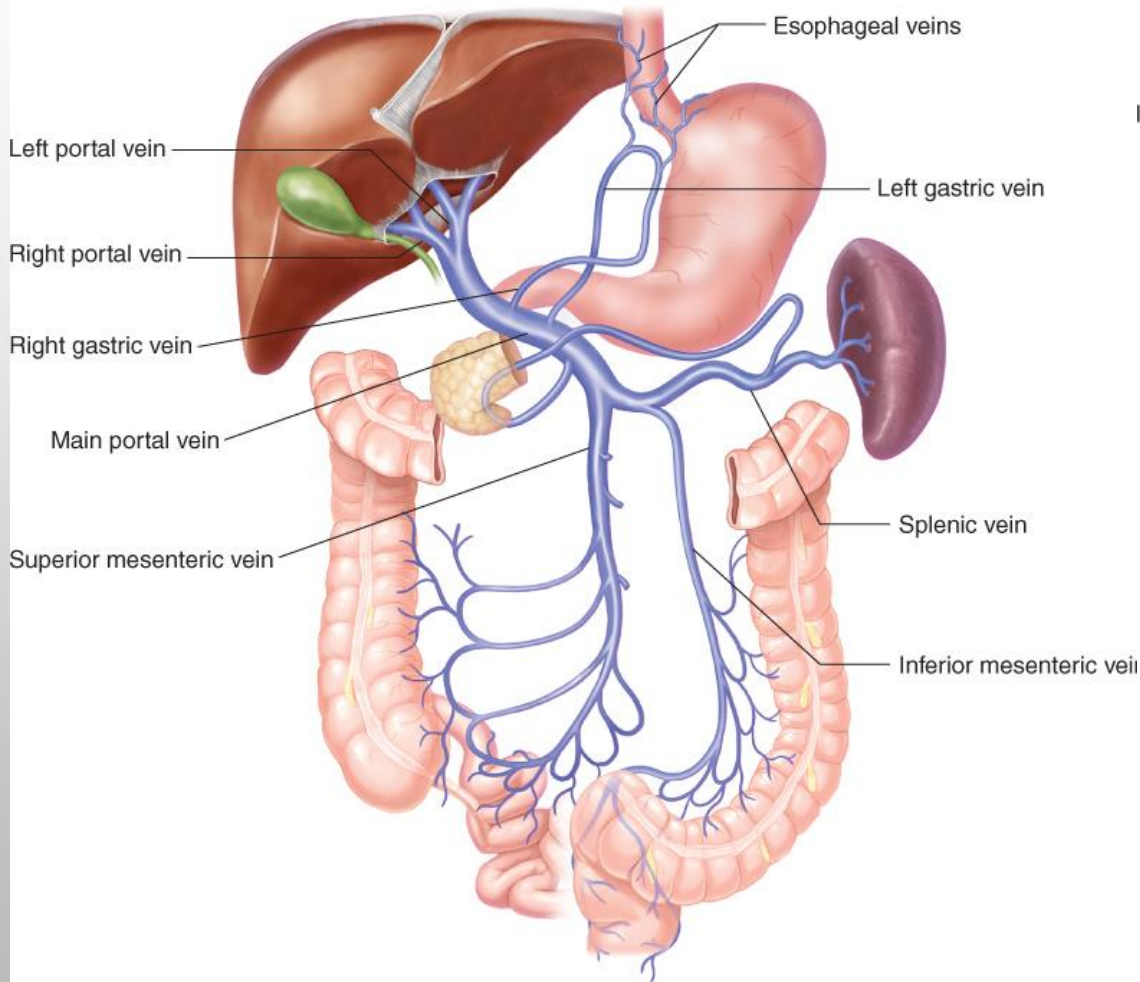
Always use cine to show color on 2D Image with Doppler Spectrum



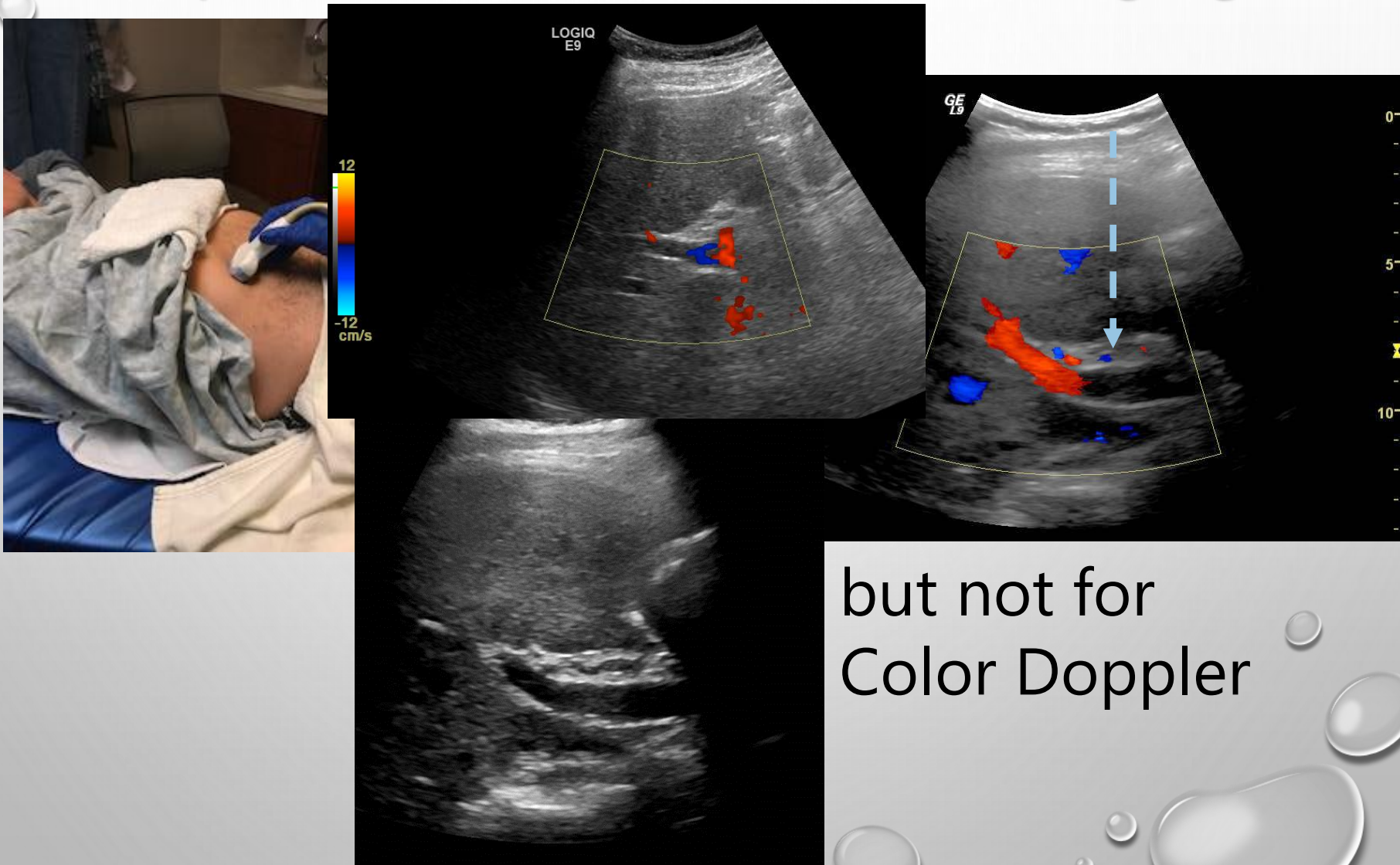
The background of the slide is a light gray gradient with several realistic water droplets of various sizes scattered across it. The droplets have highlights and shadows, giving them a three-dimensional appearance. The text is centered in the middle of the slide.

Let's look at Portal Vein Doppler

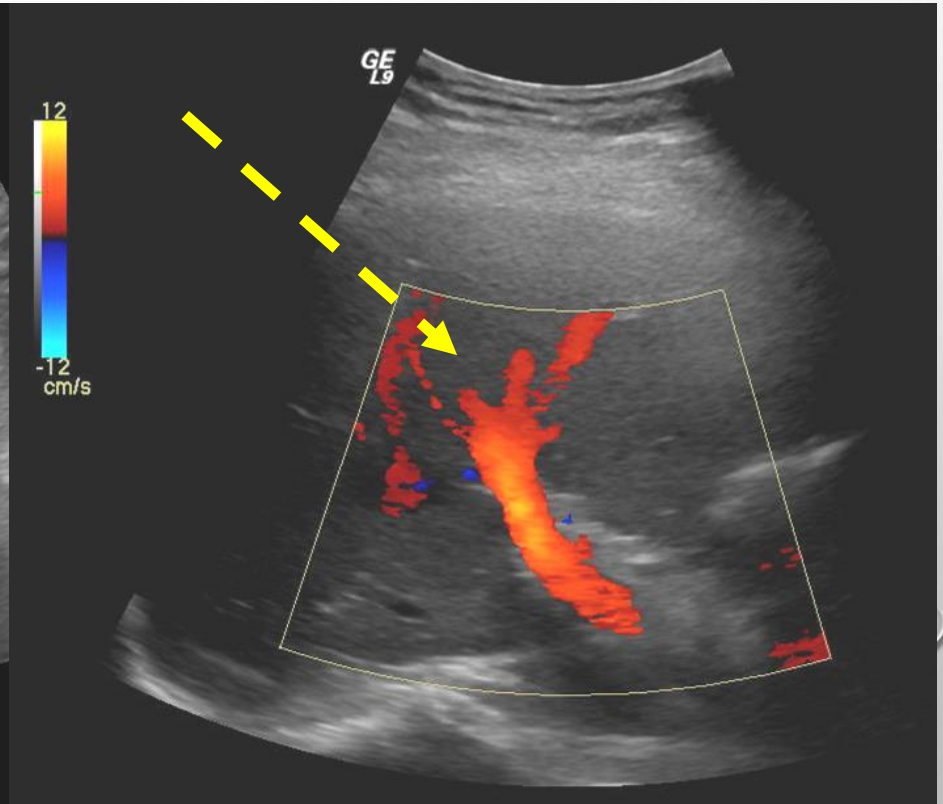
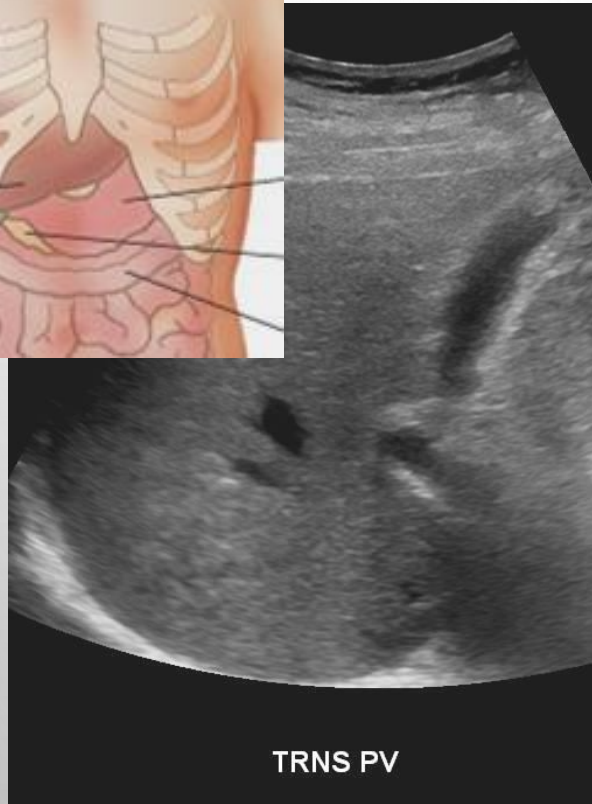
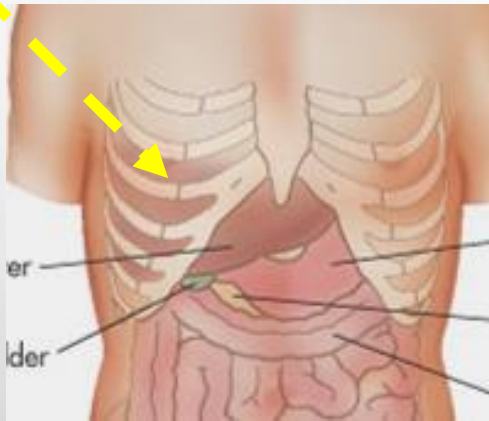
Portal System Anatomy



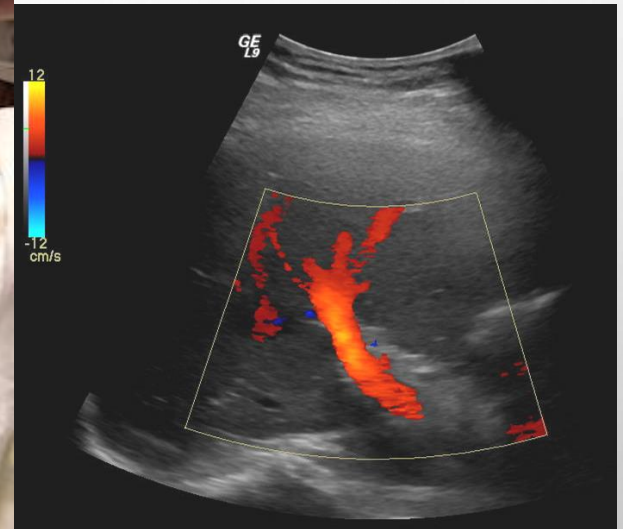
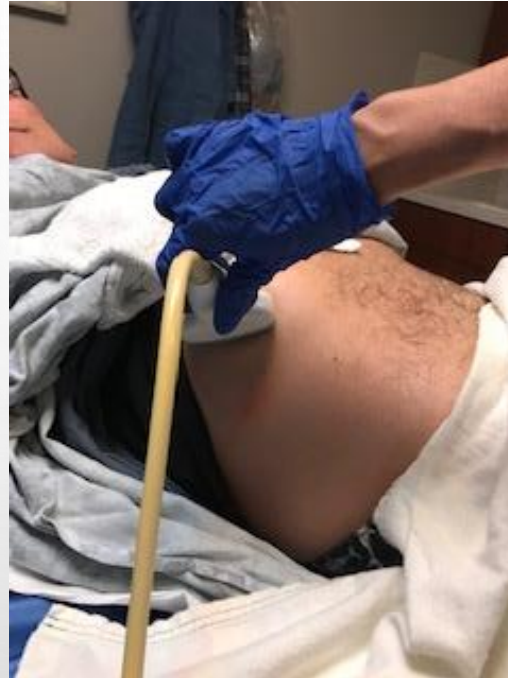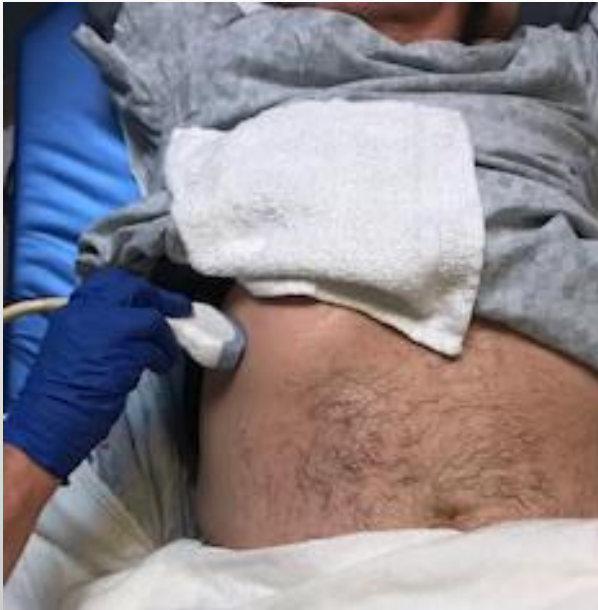Perpendicular is best for 2D imaging...



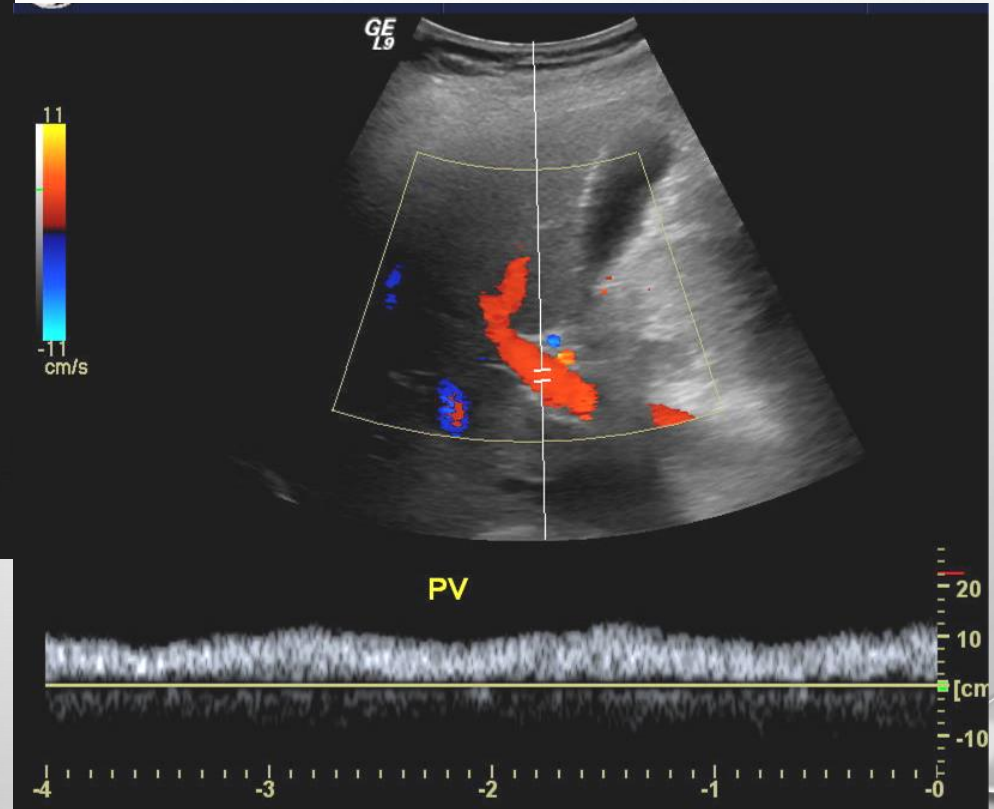
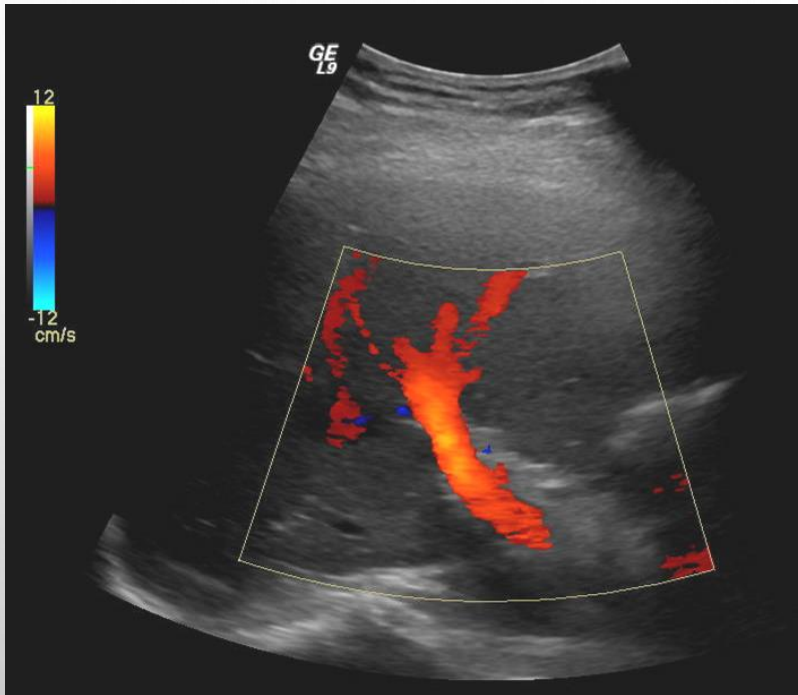
Intercostal window directs sound more parallel for MPV color



Direct sound through ribs for Portal Vein color

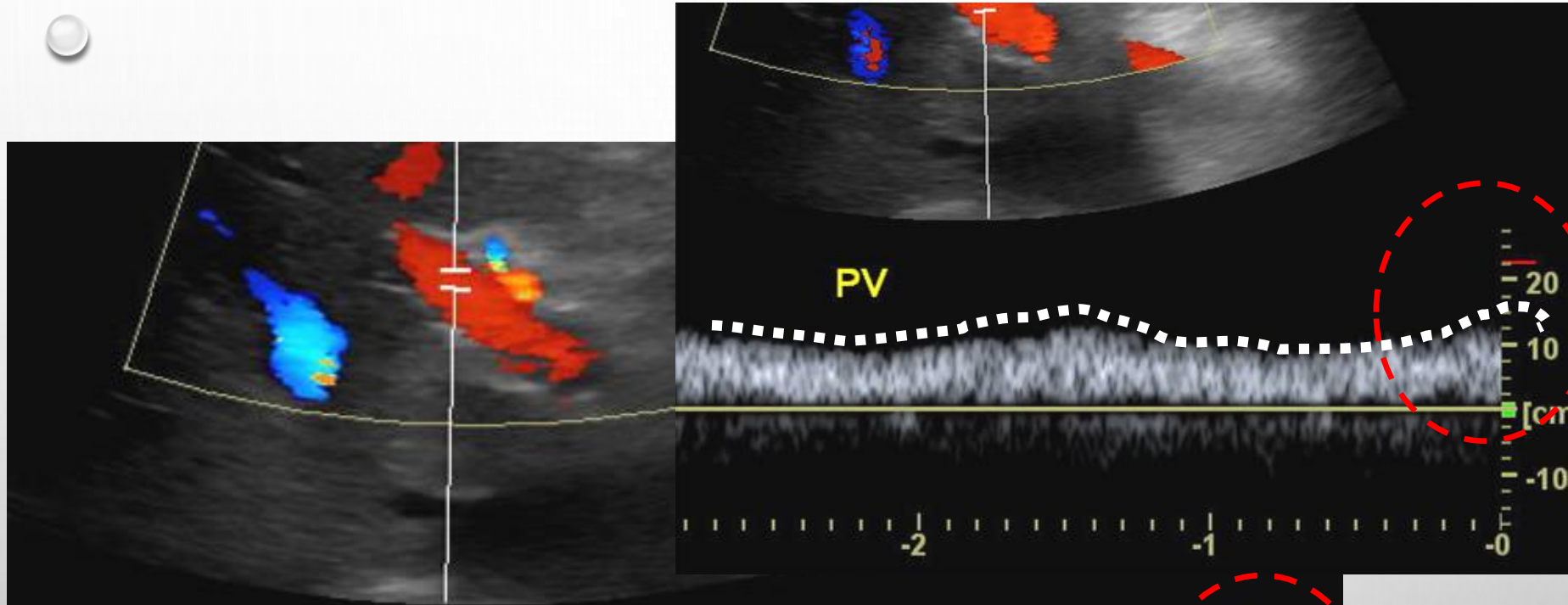


Direct Doppler Cursor More Parallel to Flow



Don't need to angle correct to MPV

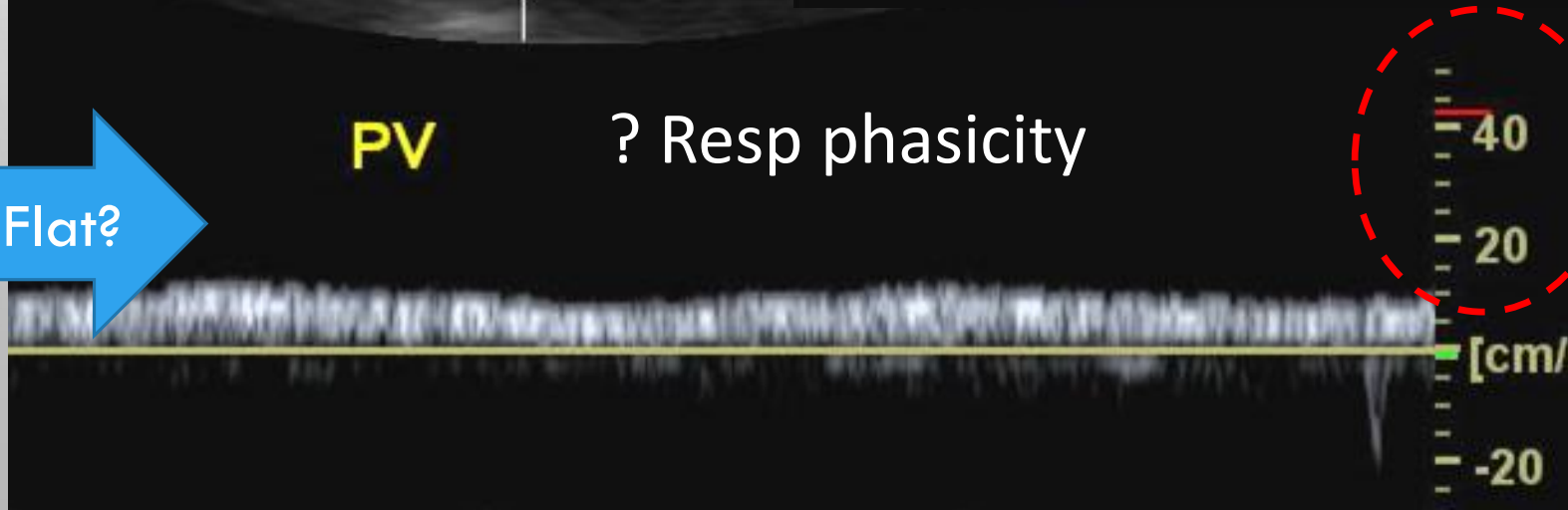
Use low PRF scale to show respiratory variations!



PV

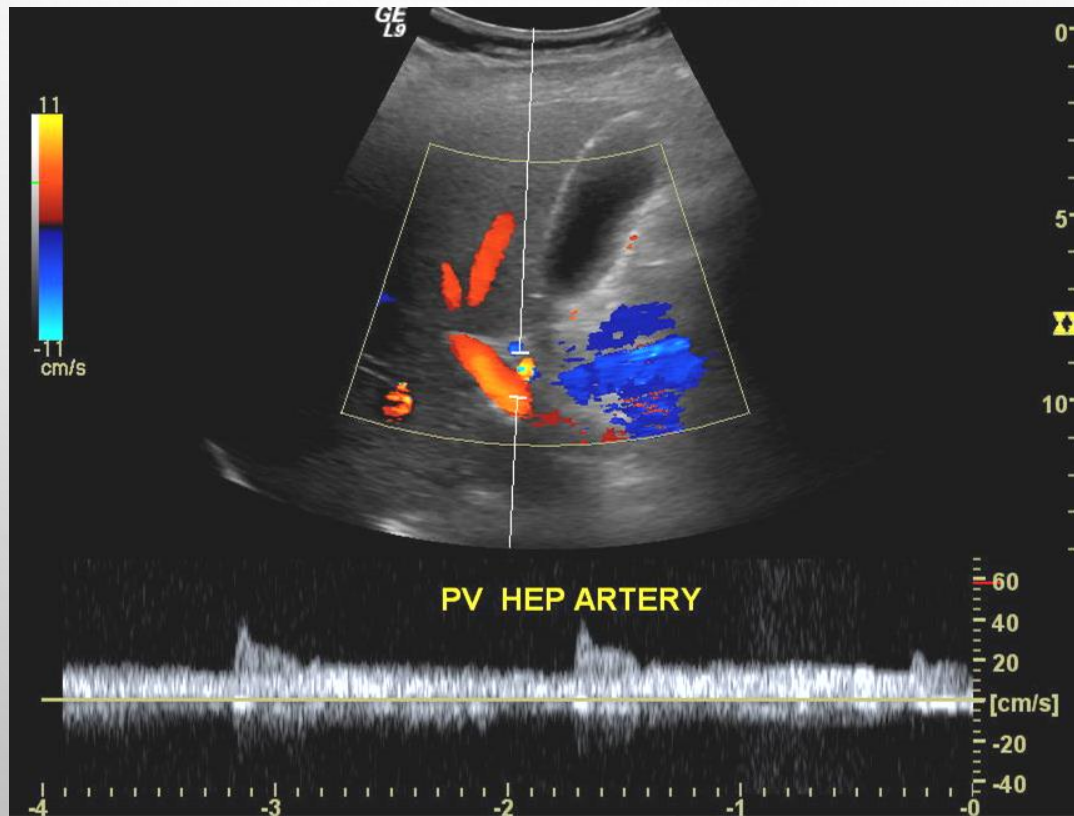
? Resp phasicity

Flat?

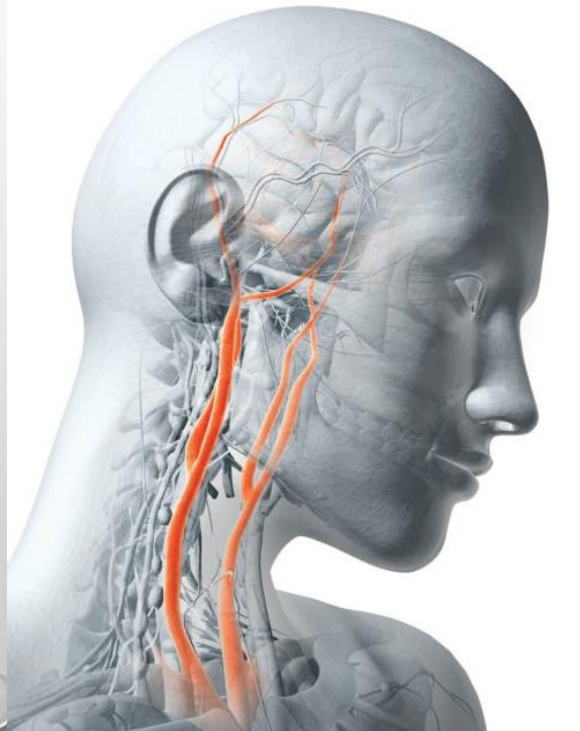


Sometimes break the Rules!

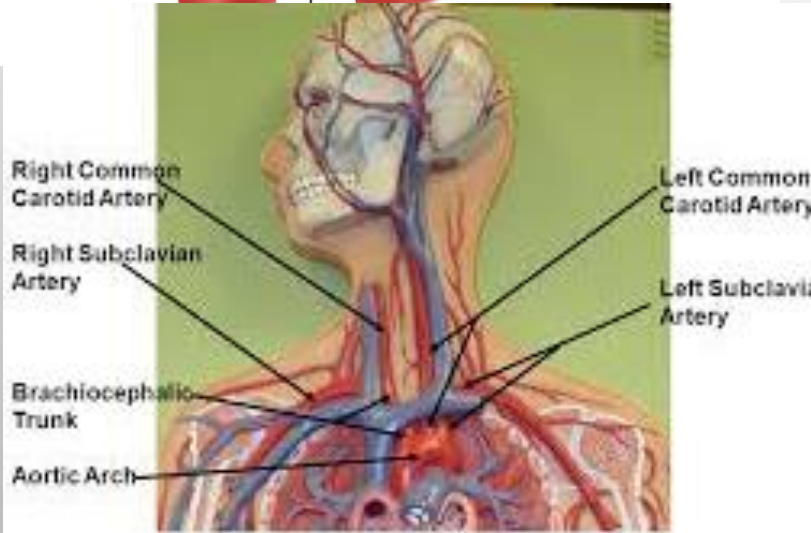
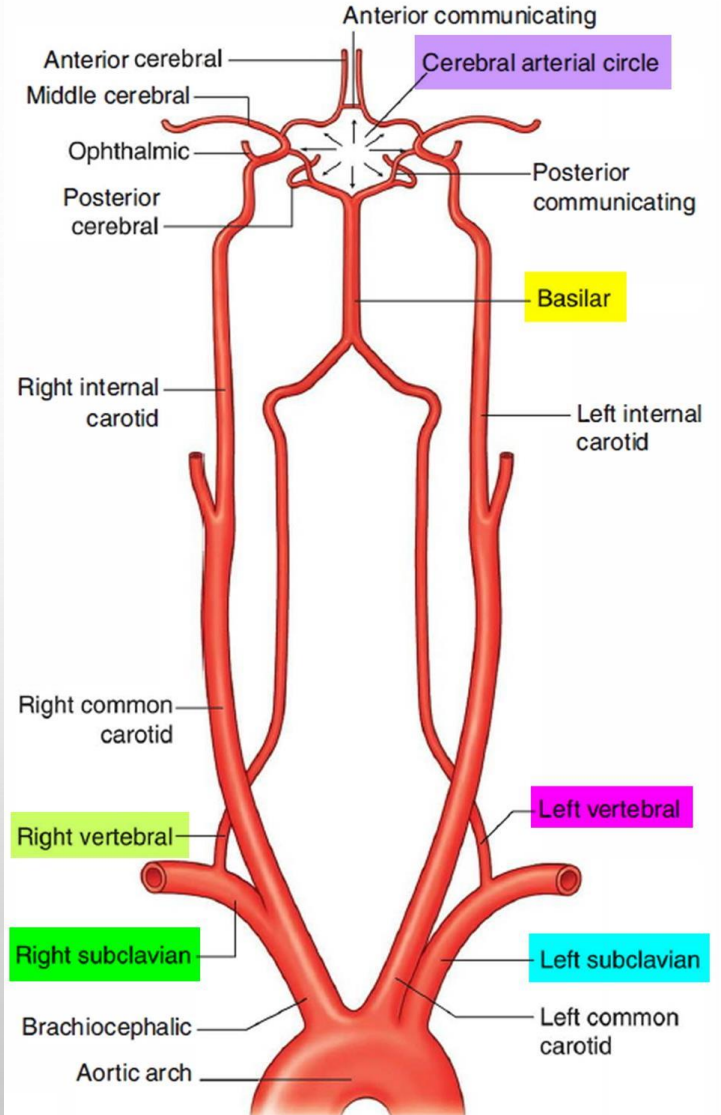
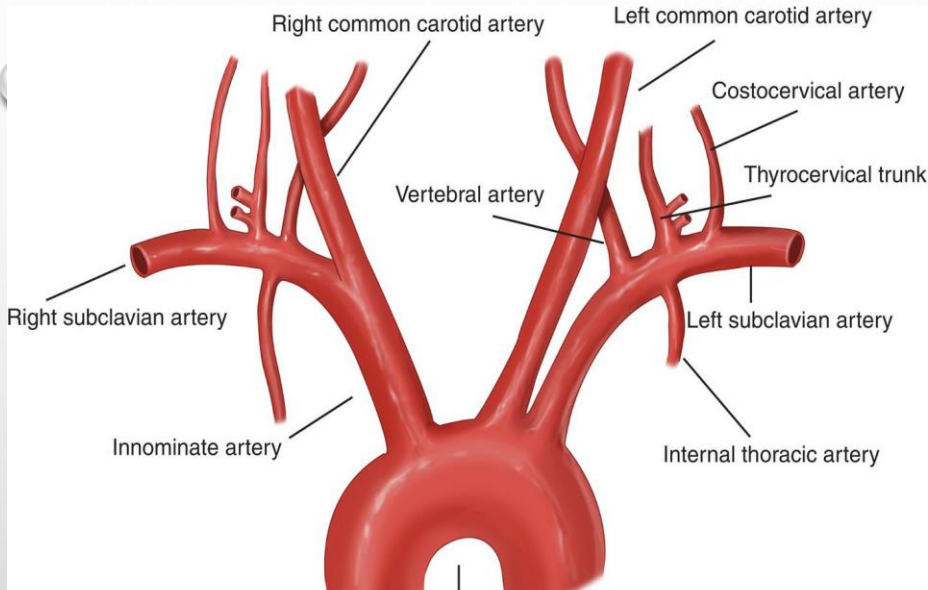
Open sample volume to get
BOTH Portal Vein and Hepatic Artery Doppler



Let's Apply Secrets to Carotid Scanning



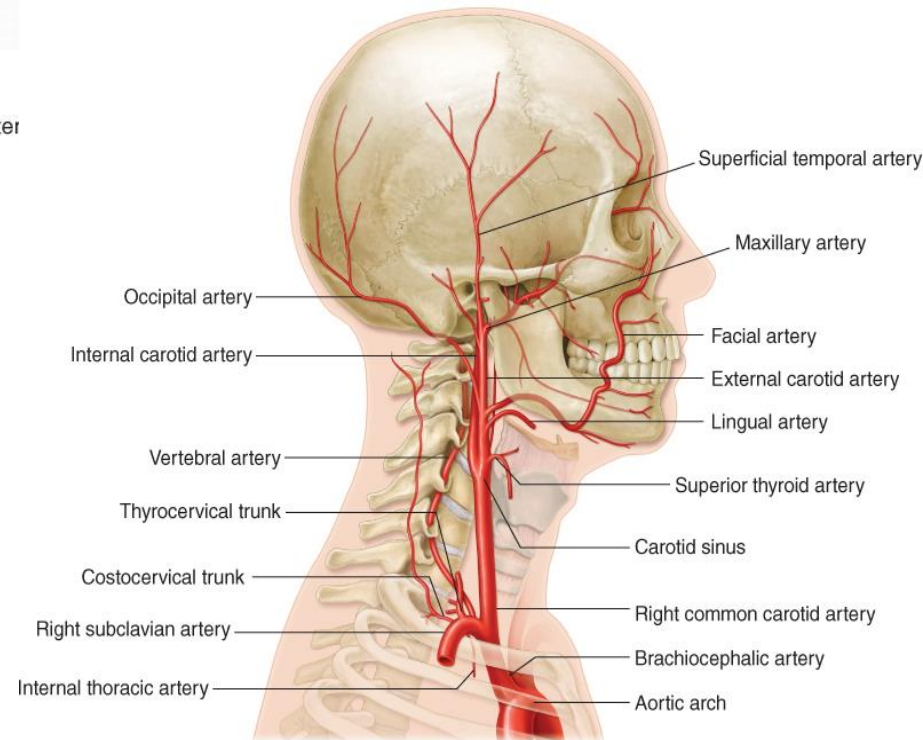
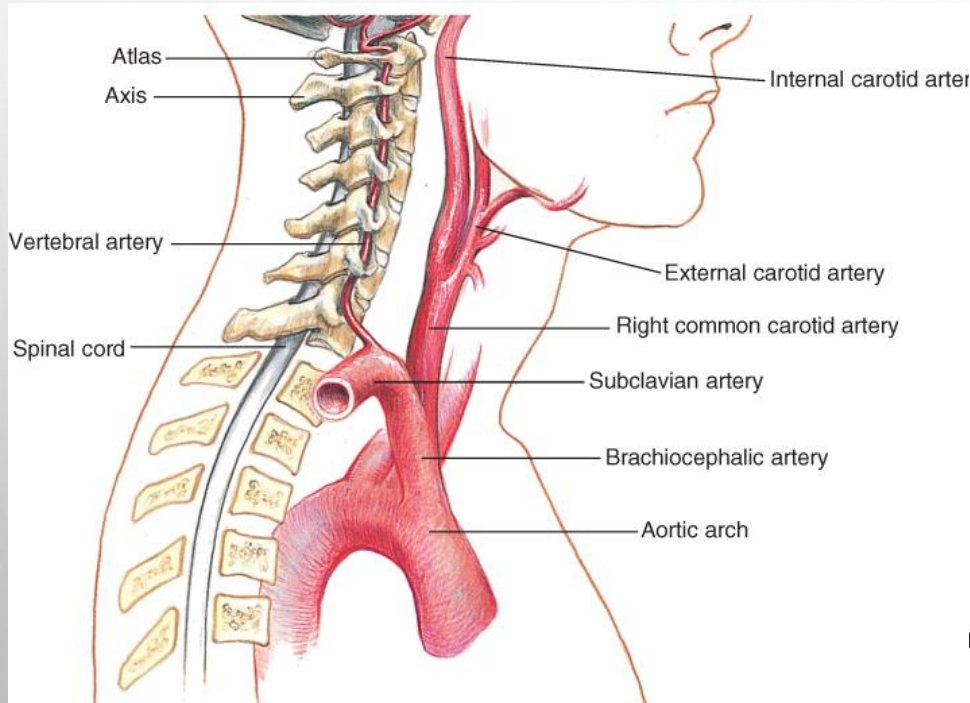
Cerebrovascular Anatomy



Extracranial Cerebrovascular Anatomy

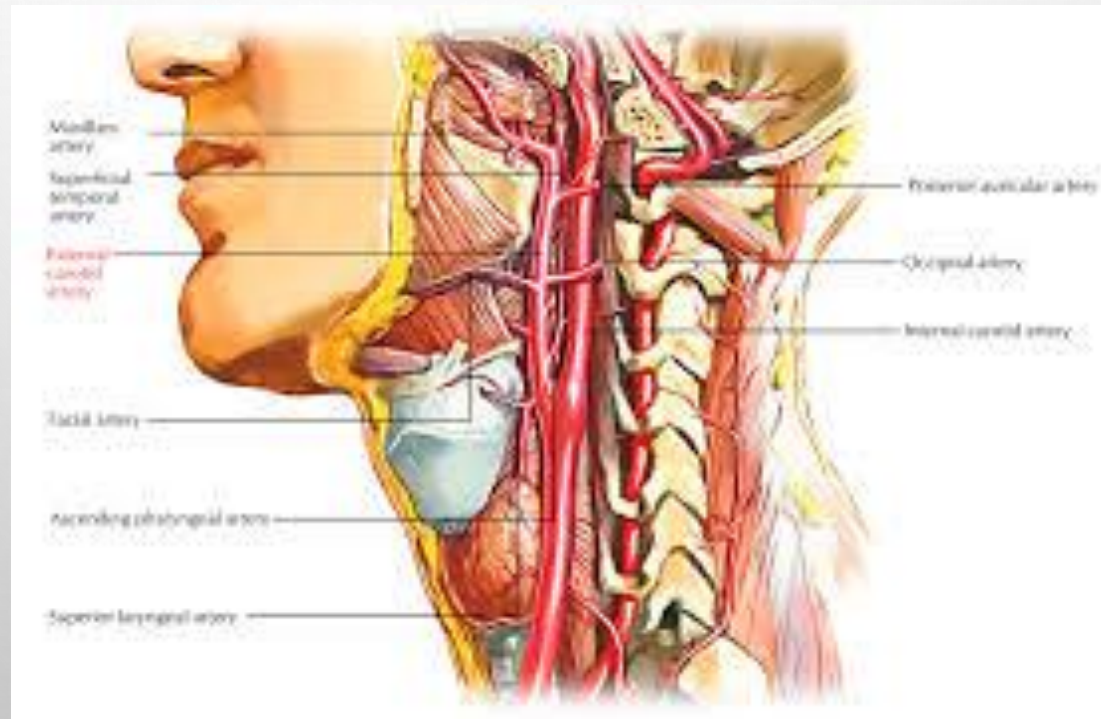
ICA usually lies posterior and lateral to ECA

ECA has 8 branches

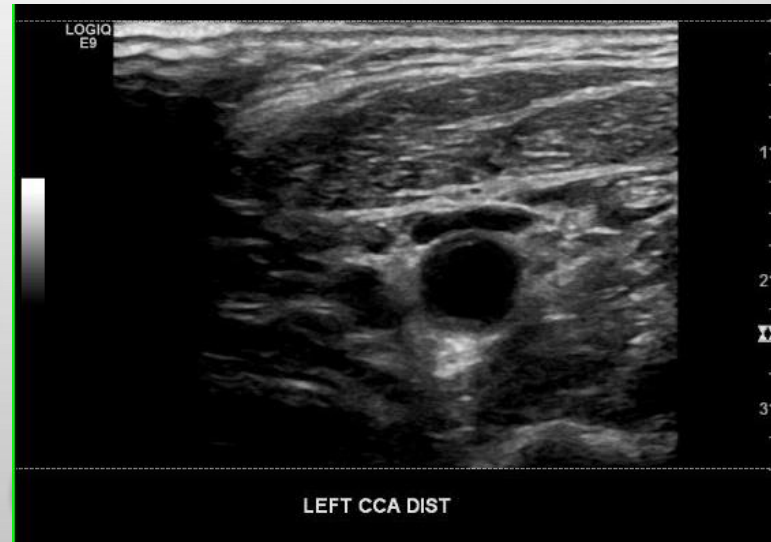
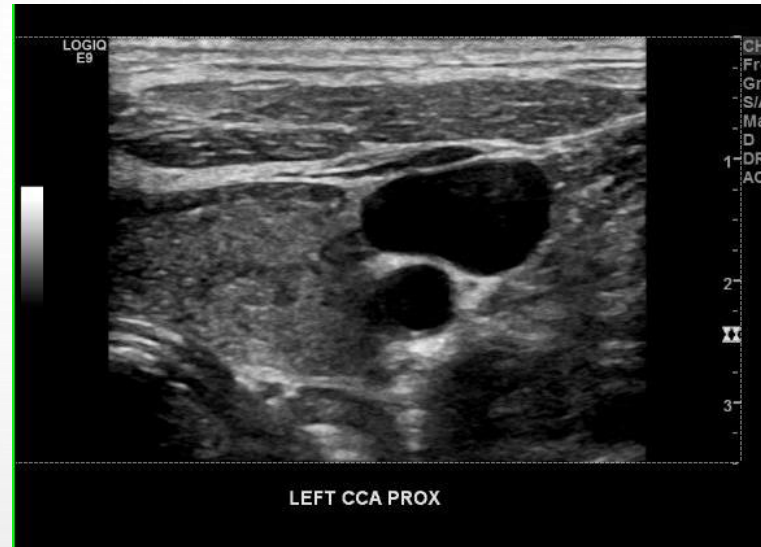
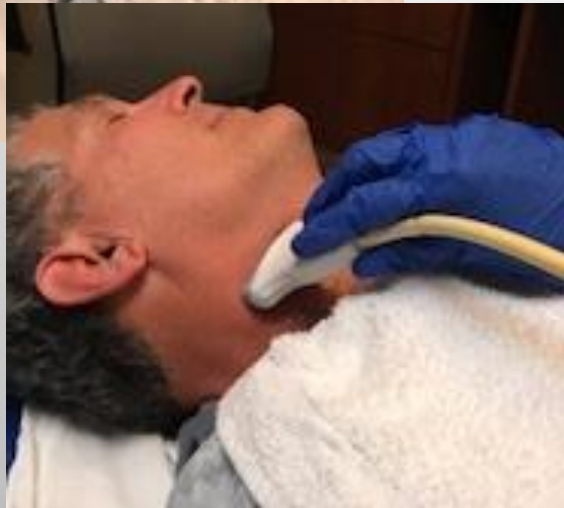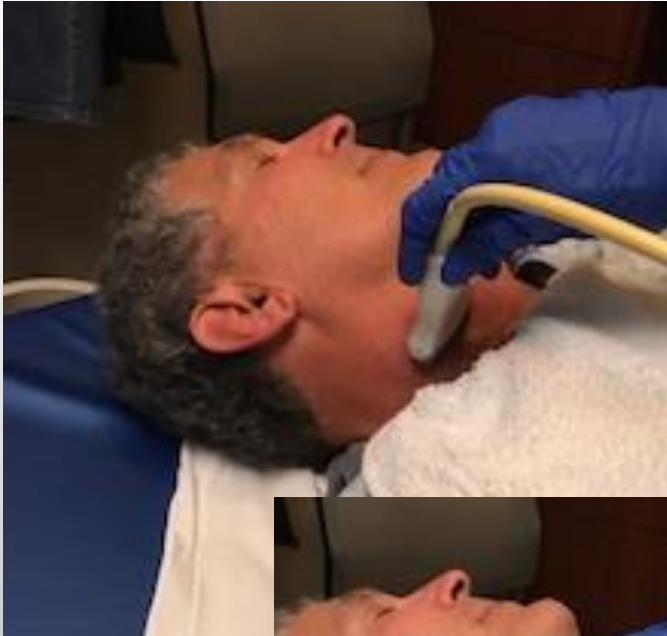Vertebral Anatomy

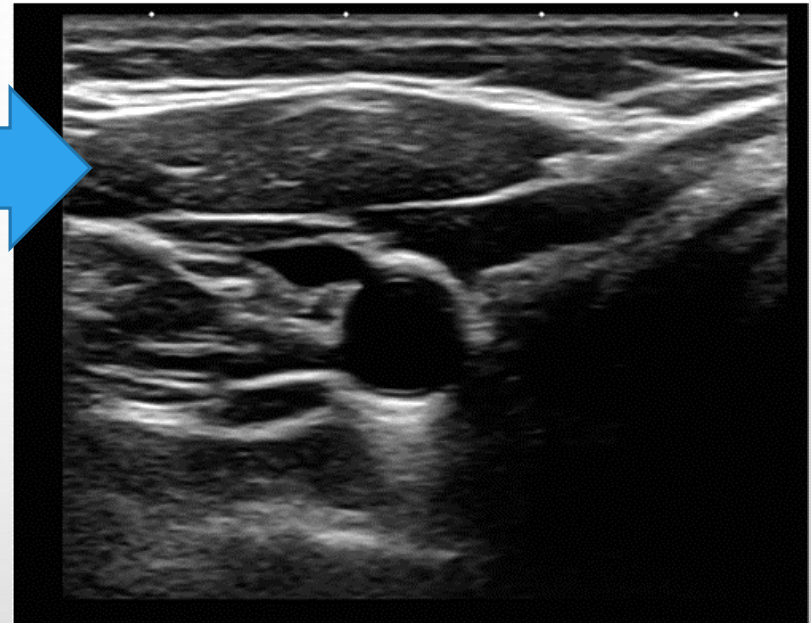
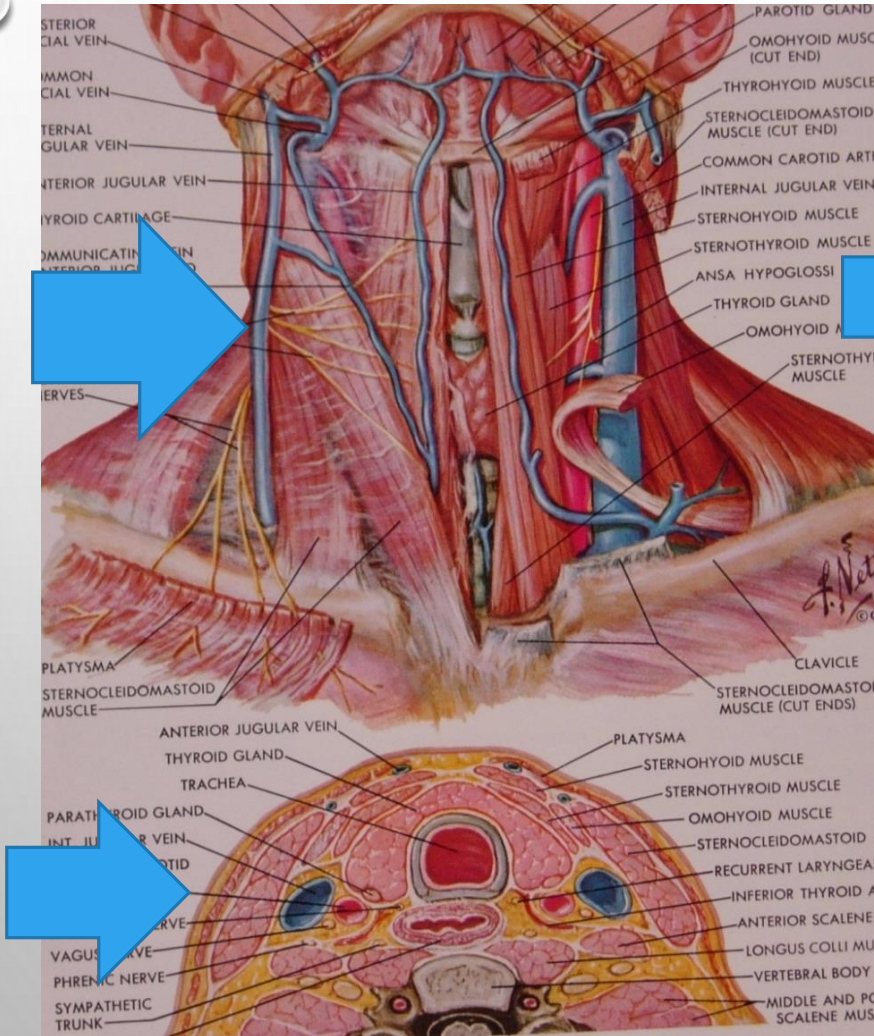
Vertebral artery enters transverse process of sixth cervical vertebra coursing through foramina of transverse process cervical vertebrae



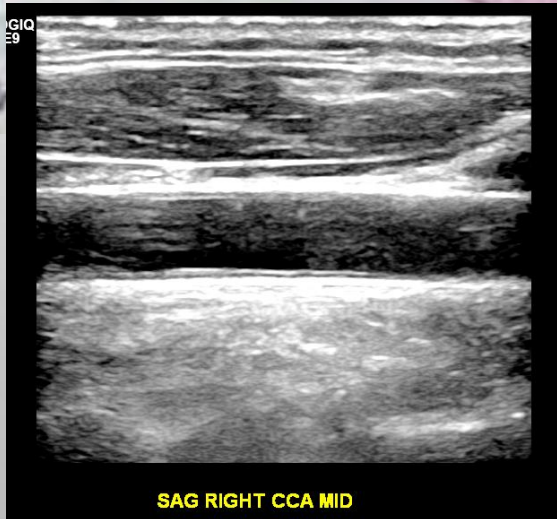
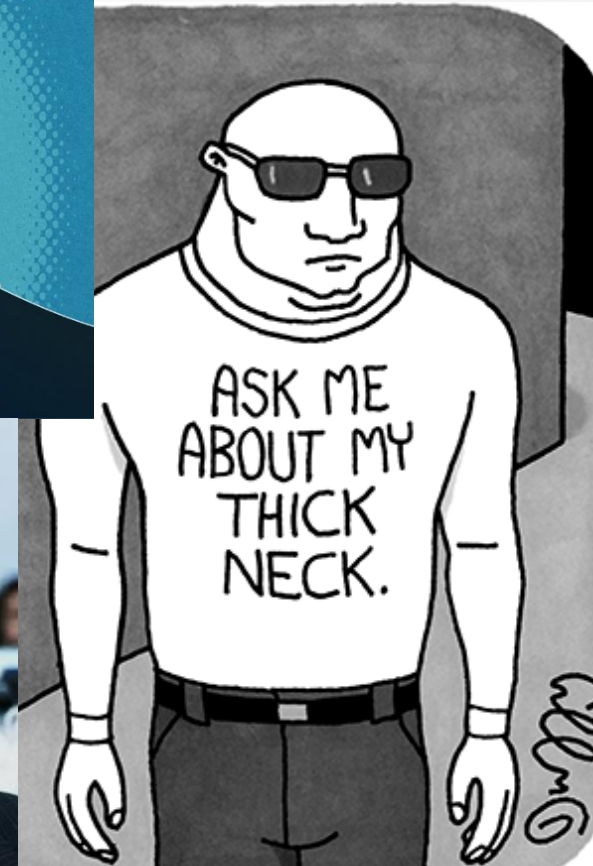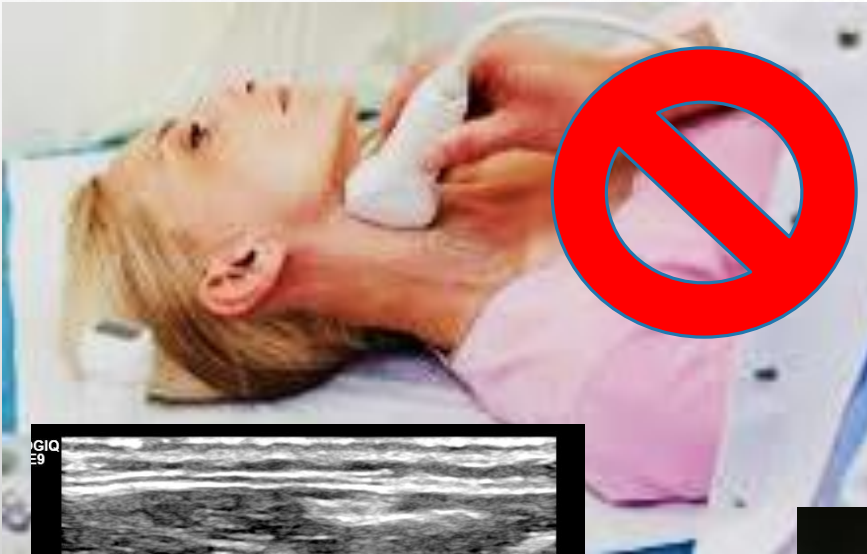Starting transverse is helpful Survey from inferior to superior



Use lateral sternocleidomastoid muscle as window



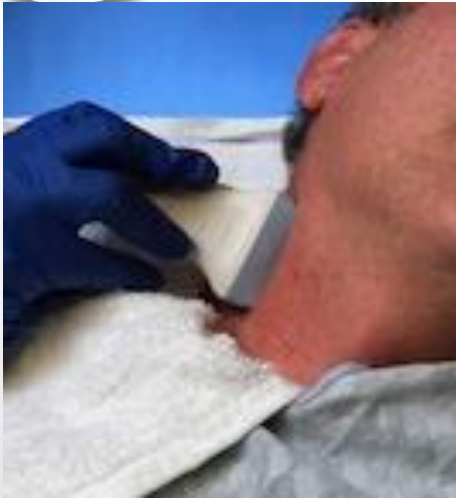Use a medial approach for carotid when...



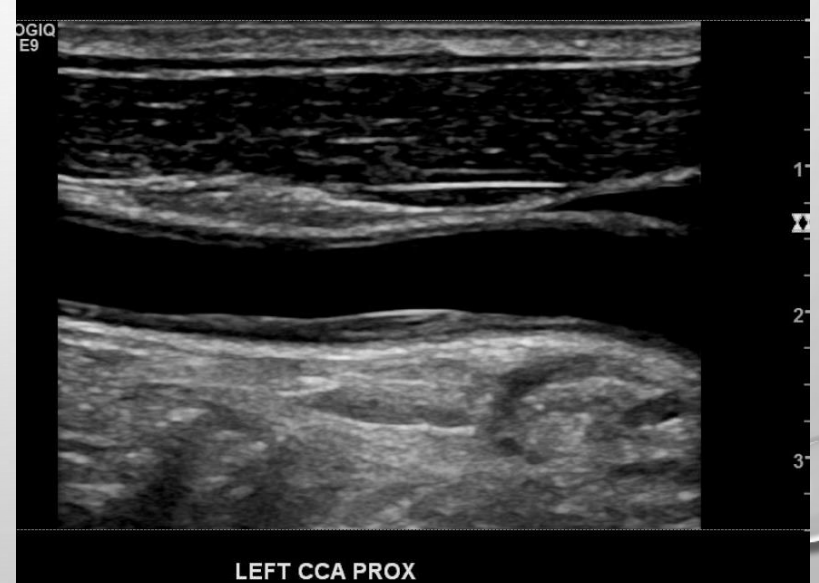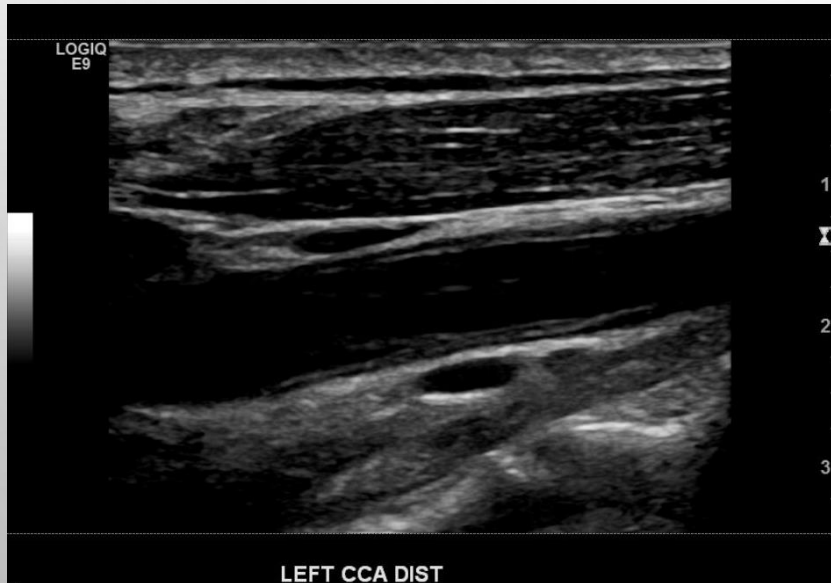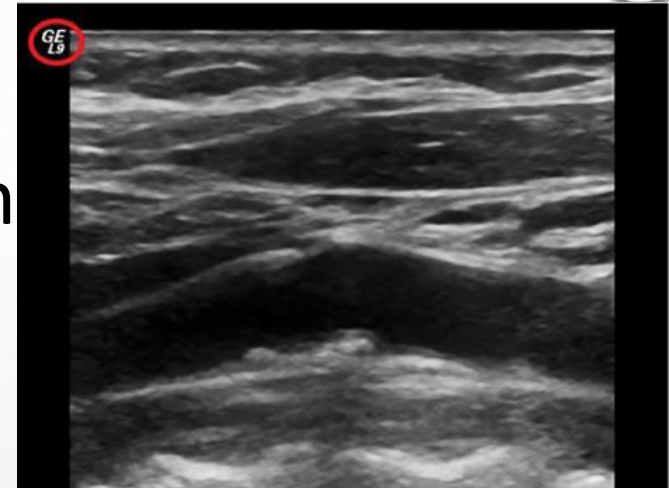
SAG RIGHT CCA MID



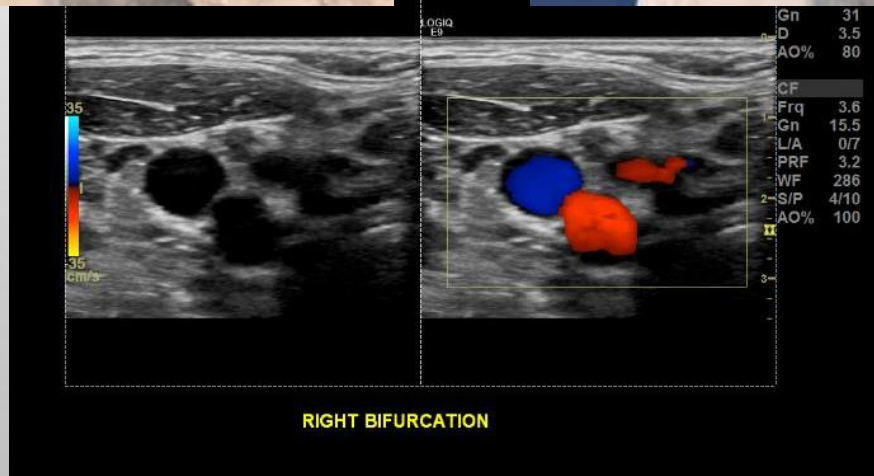
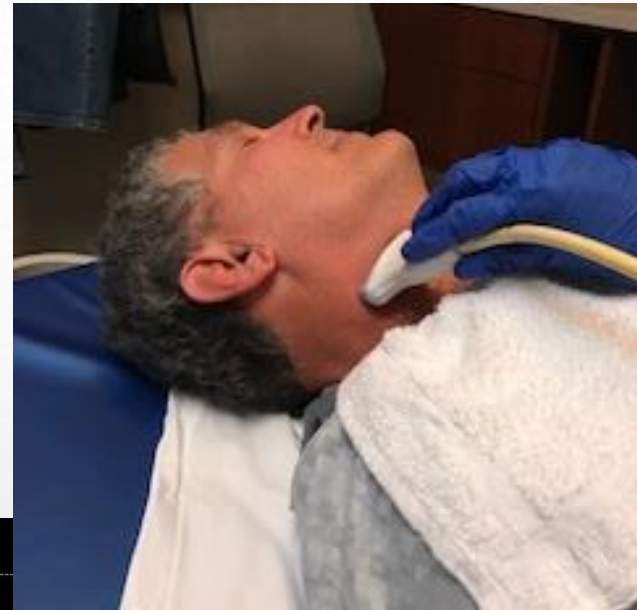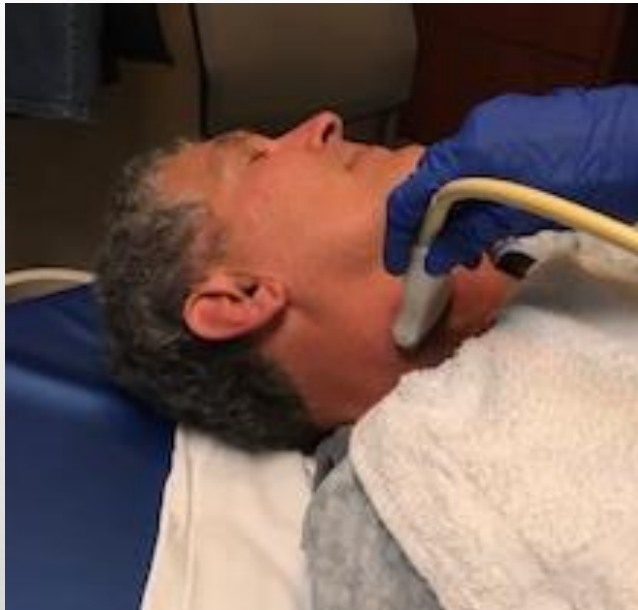Don't Under gain!



Show wall layers –
tunica intima is thin
gray-white line on
innermost wall



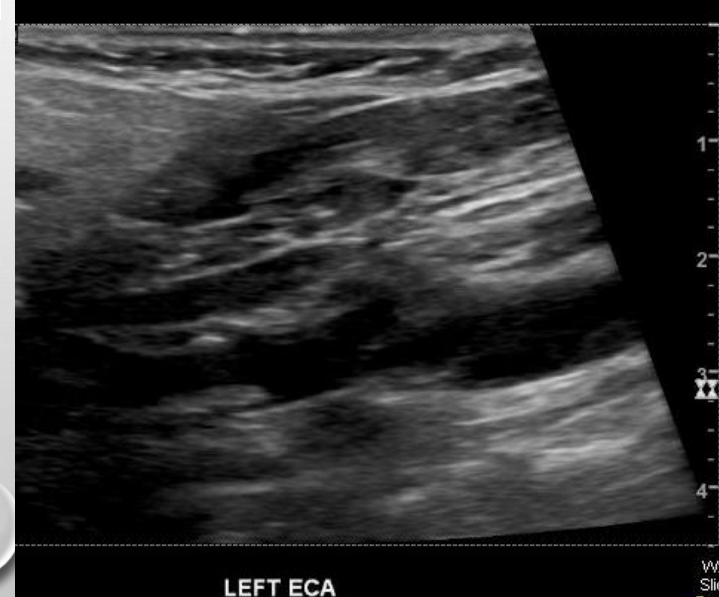
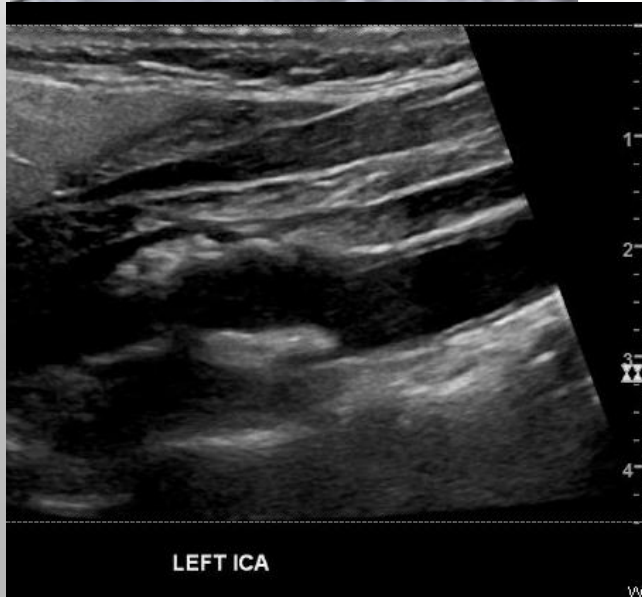
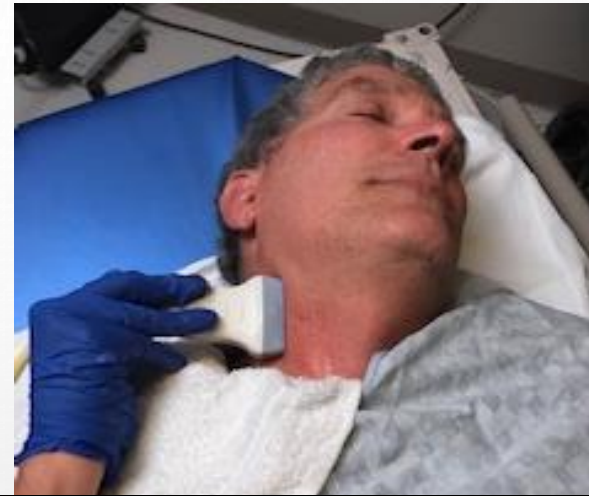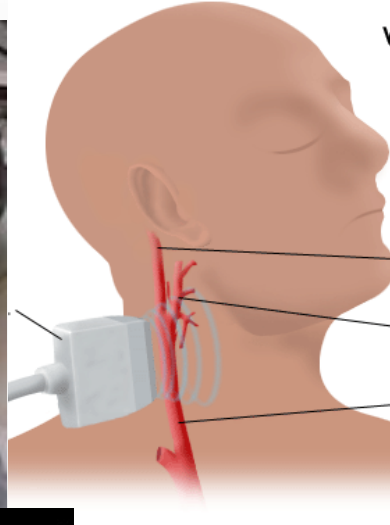
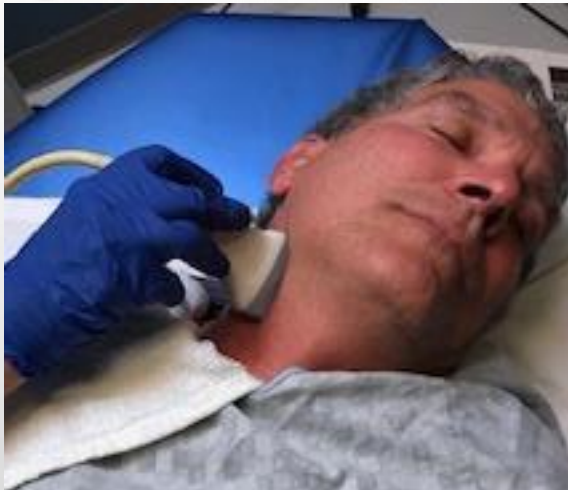Don't stay perpendicular for trans color



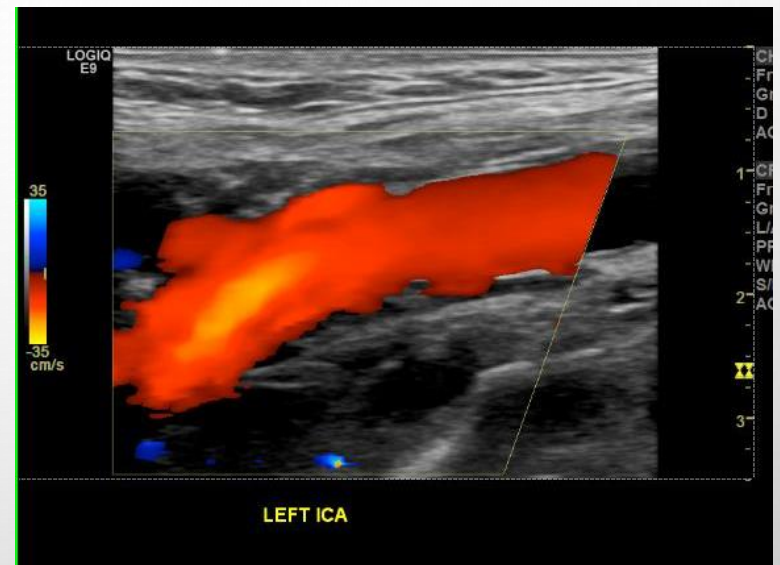
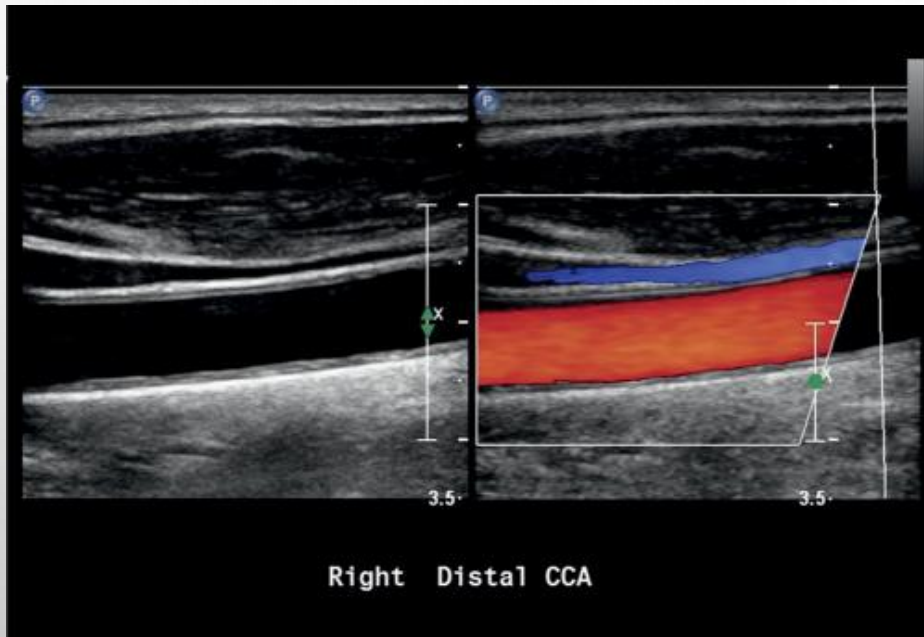
Long Carotid Bifurcation

ICA angle posteriorly

ECA angle anteriorly

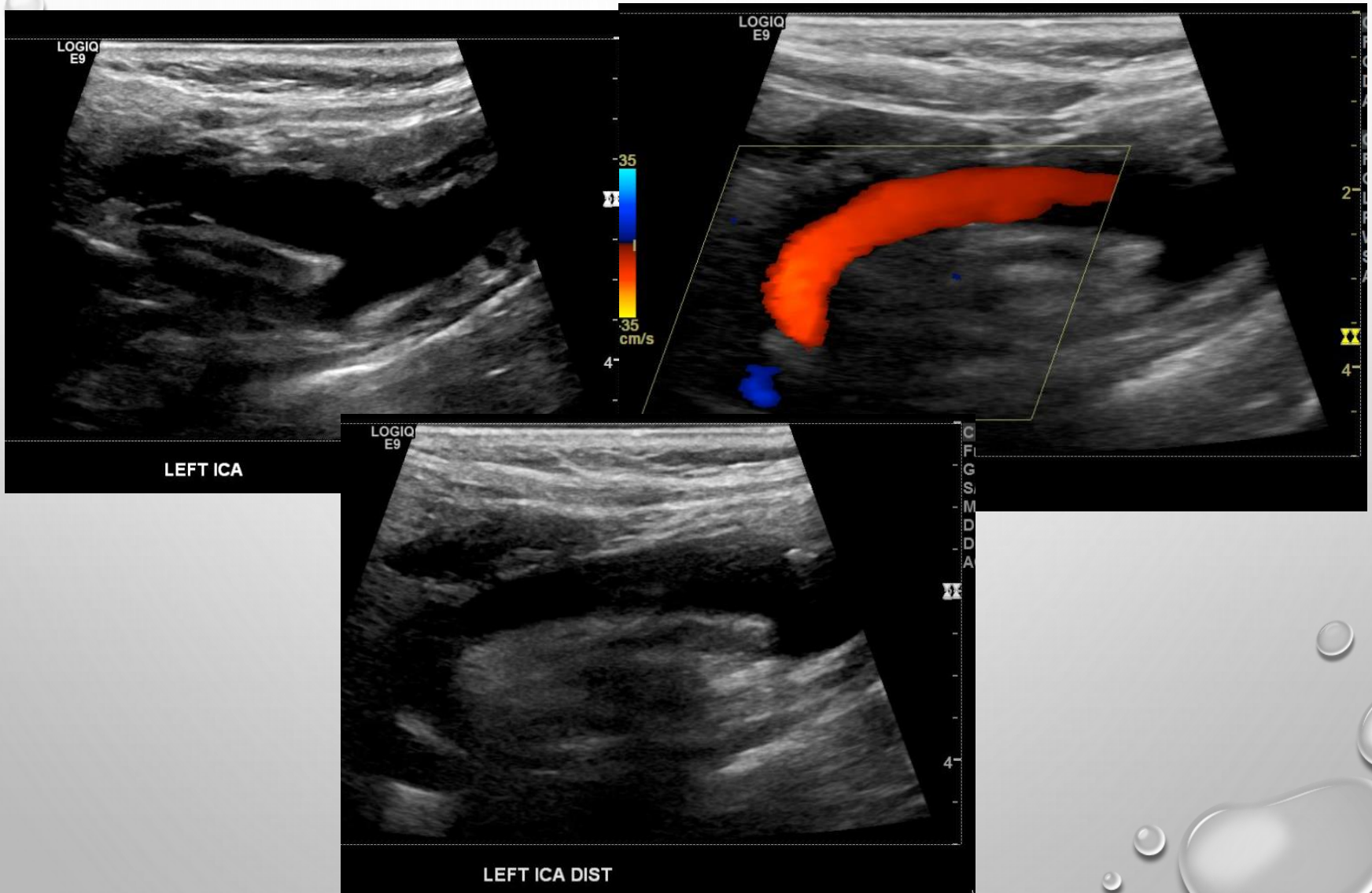


- Color Doppler should fill wall to wall

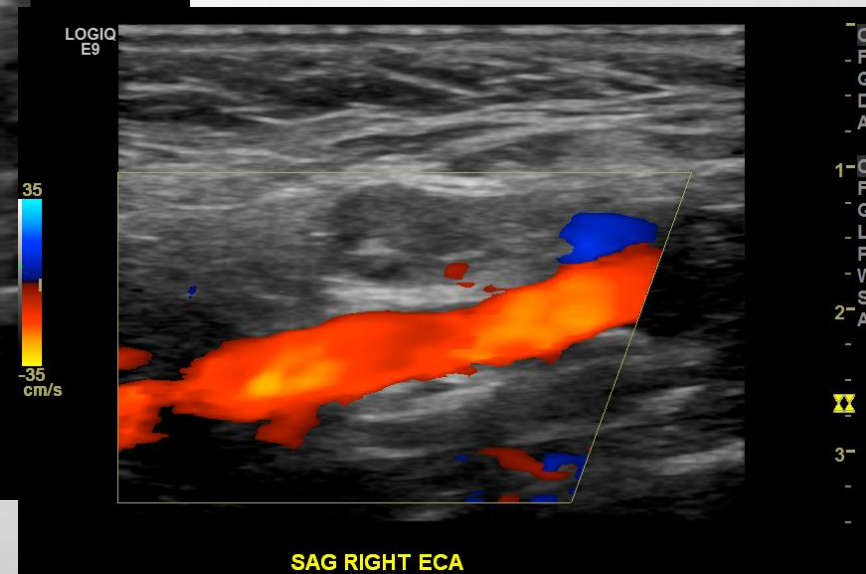
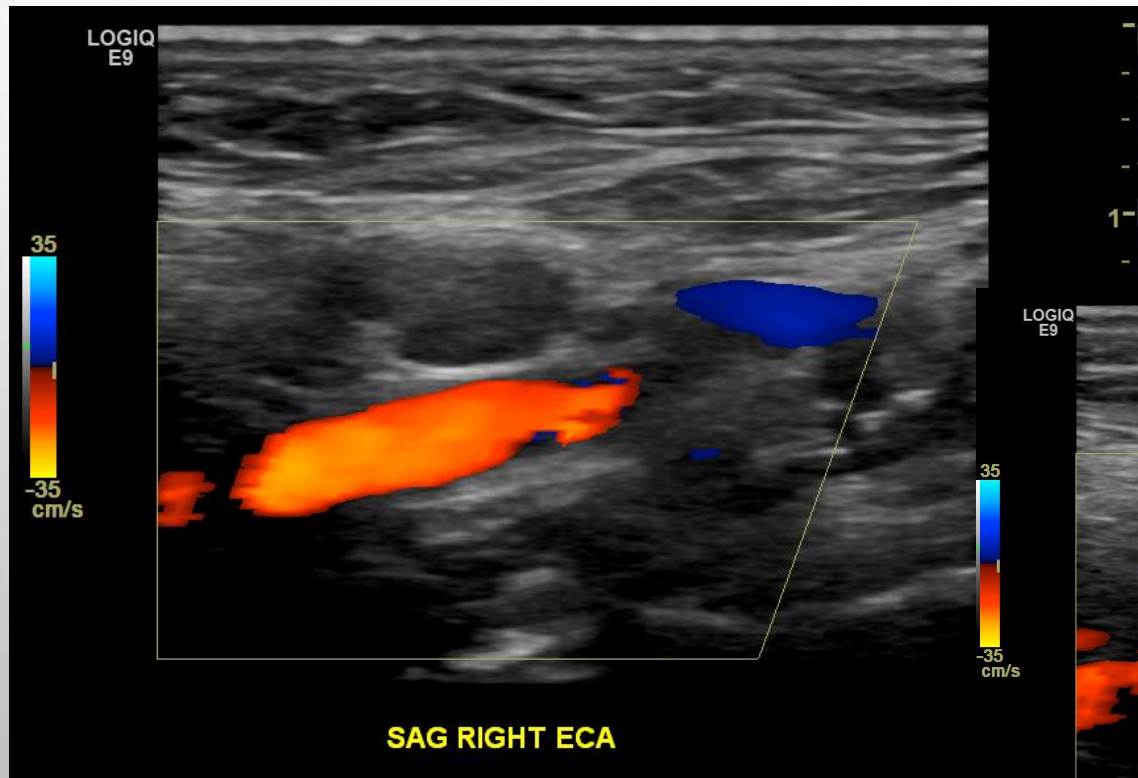


Don't let color bleed outside walls!

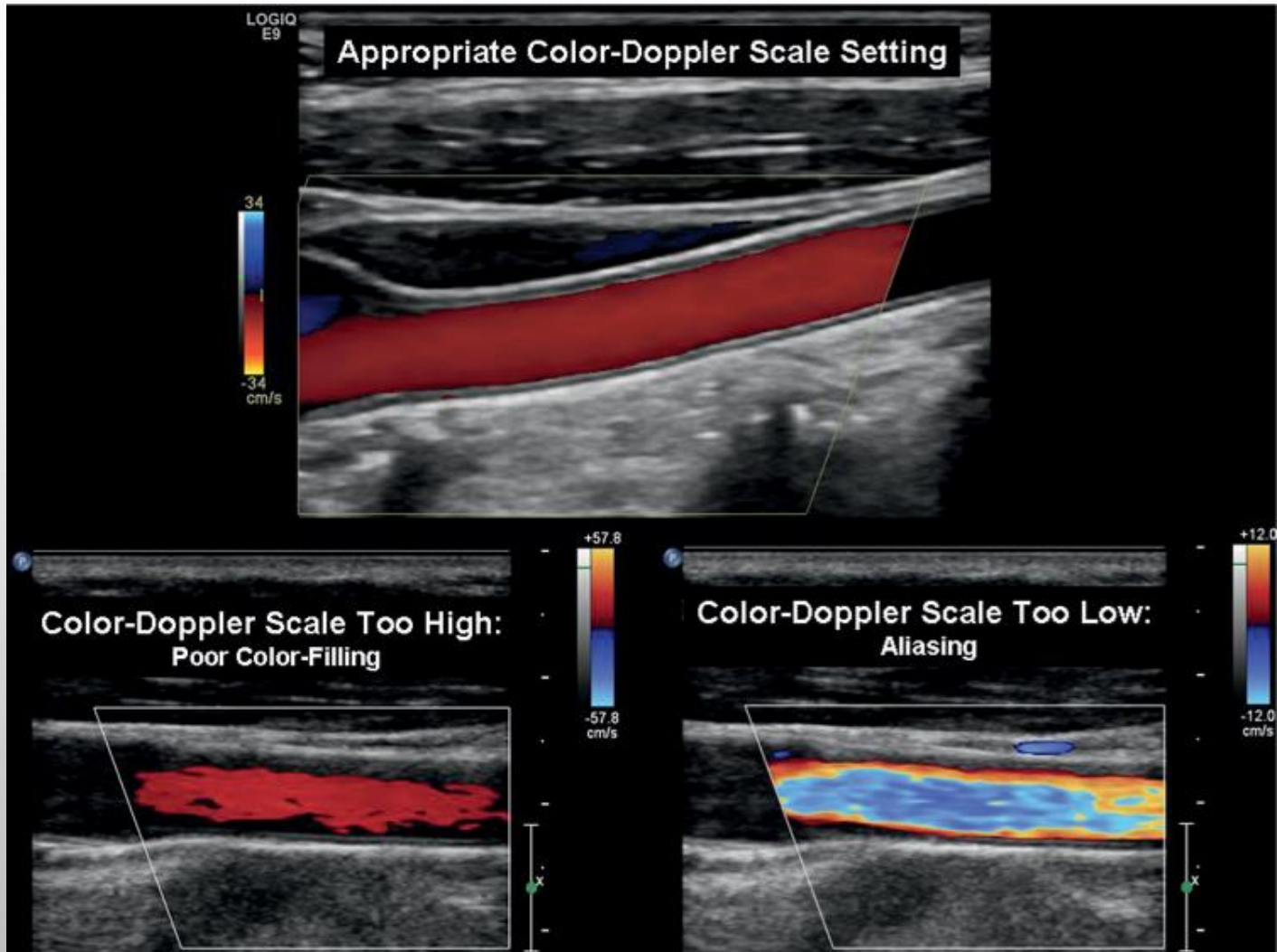
Use color to find ICA



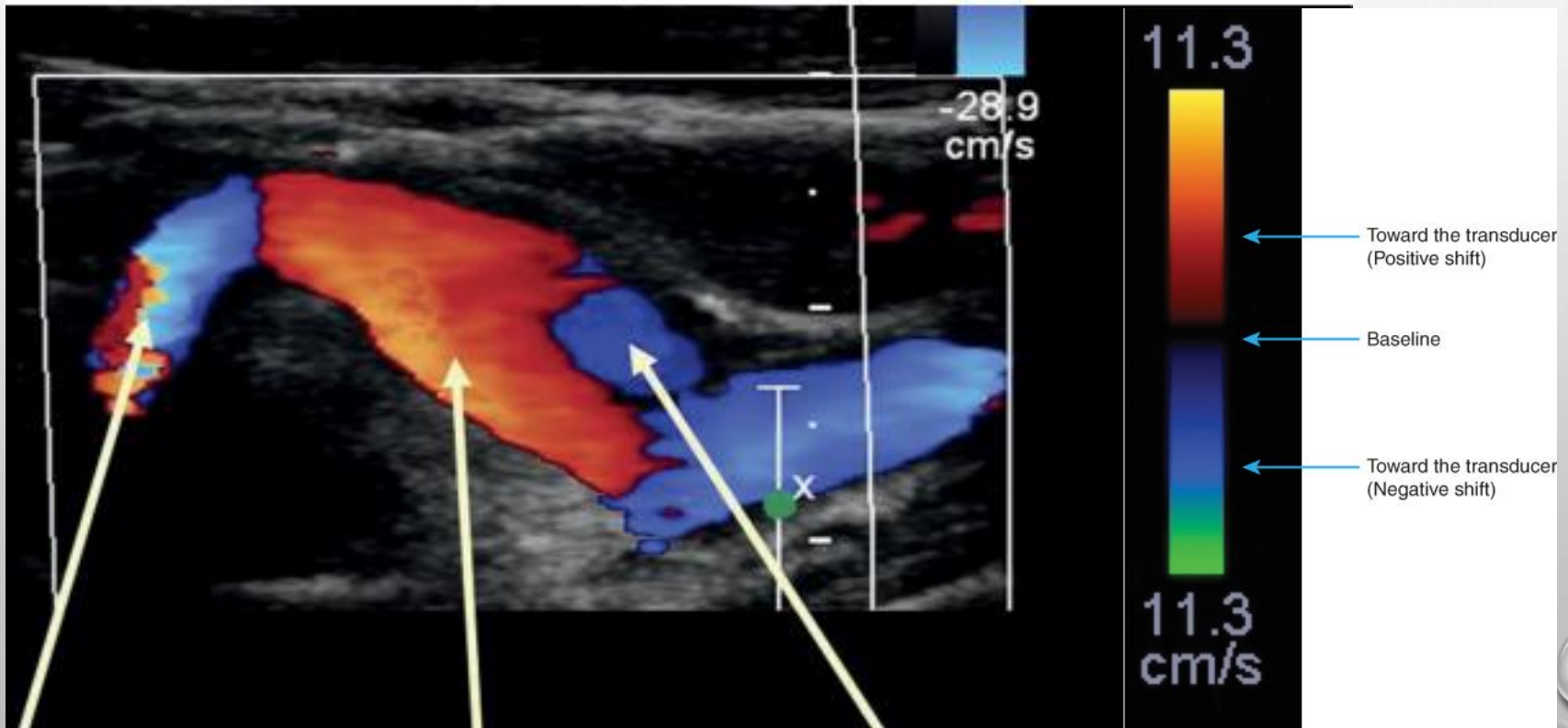
Try not to show a vessel in the middle of nowhere!



Use correct color scale

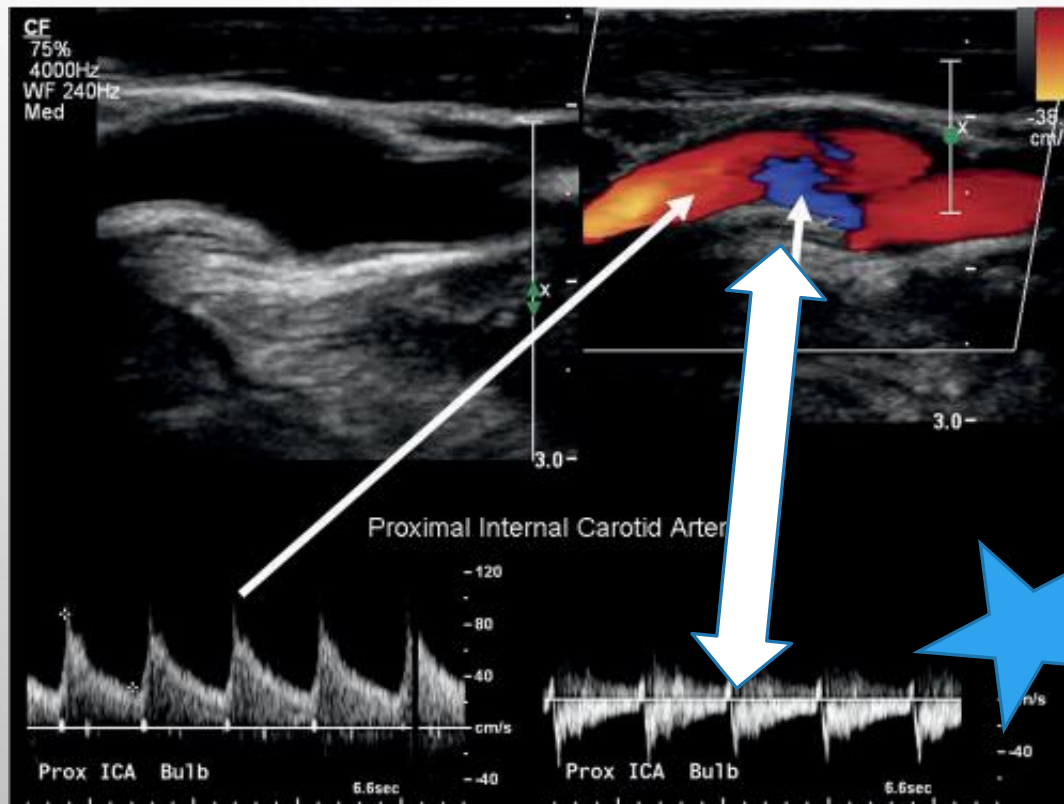


OK to use a straight box if vessel is oblique
ICA color may different colors – but all
moving in same direction

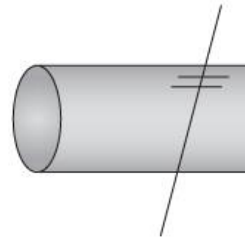
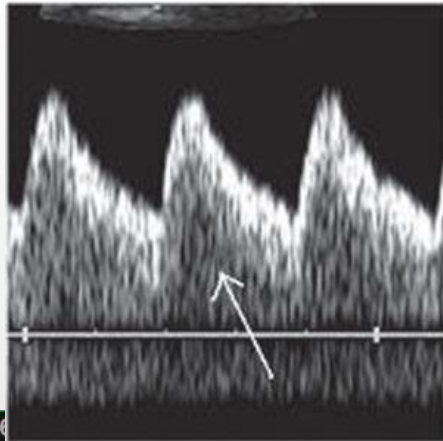


Carotid bulb flow separation

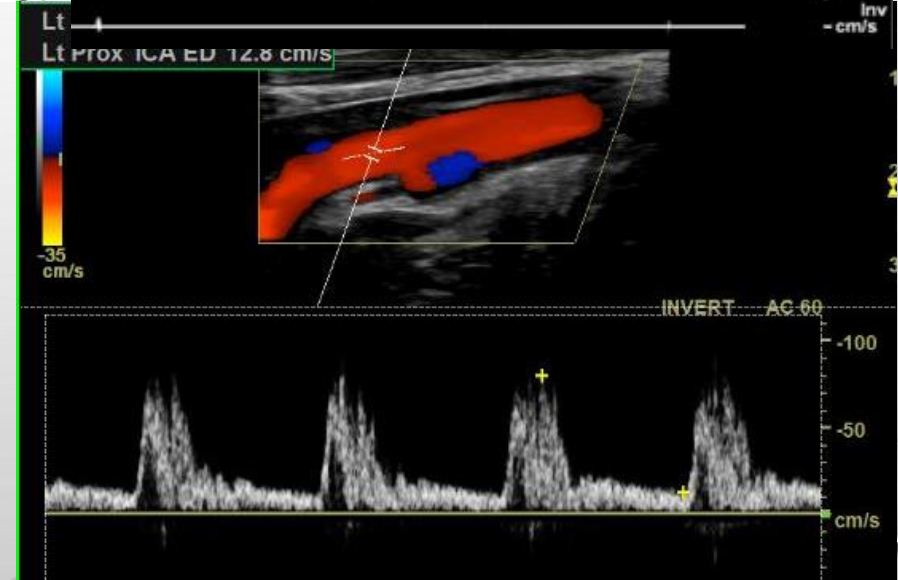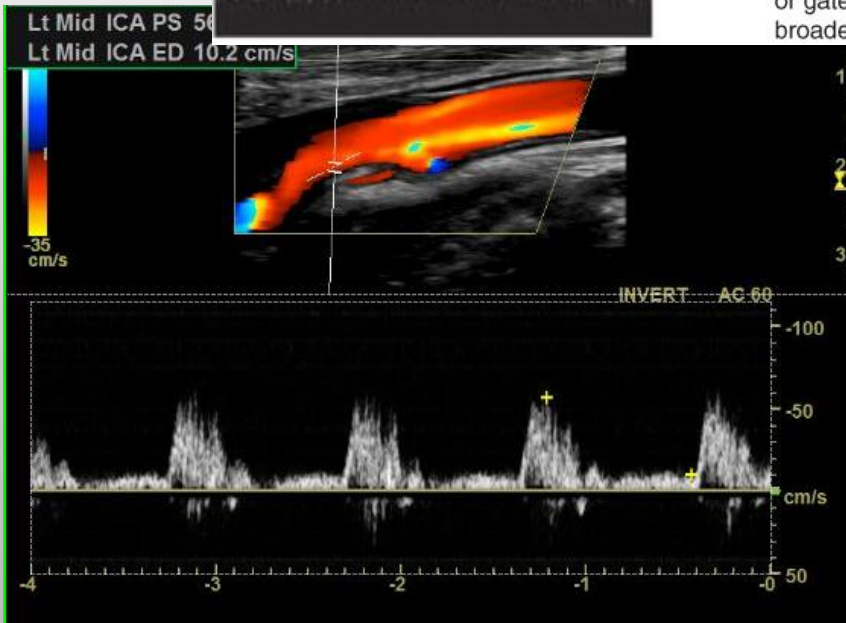
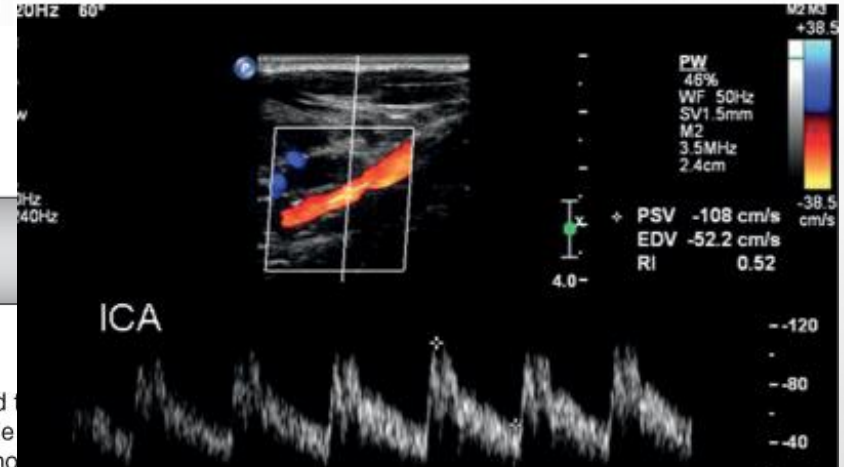
May see small area of flow reversal along the outer wall of the bulb - don't Doppler this area



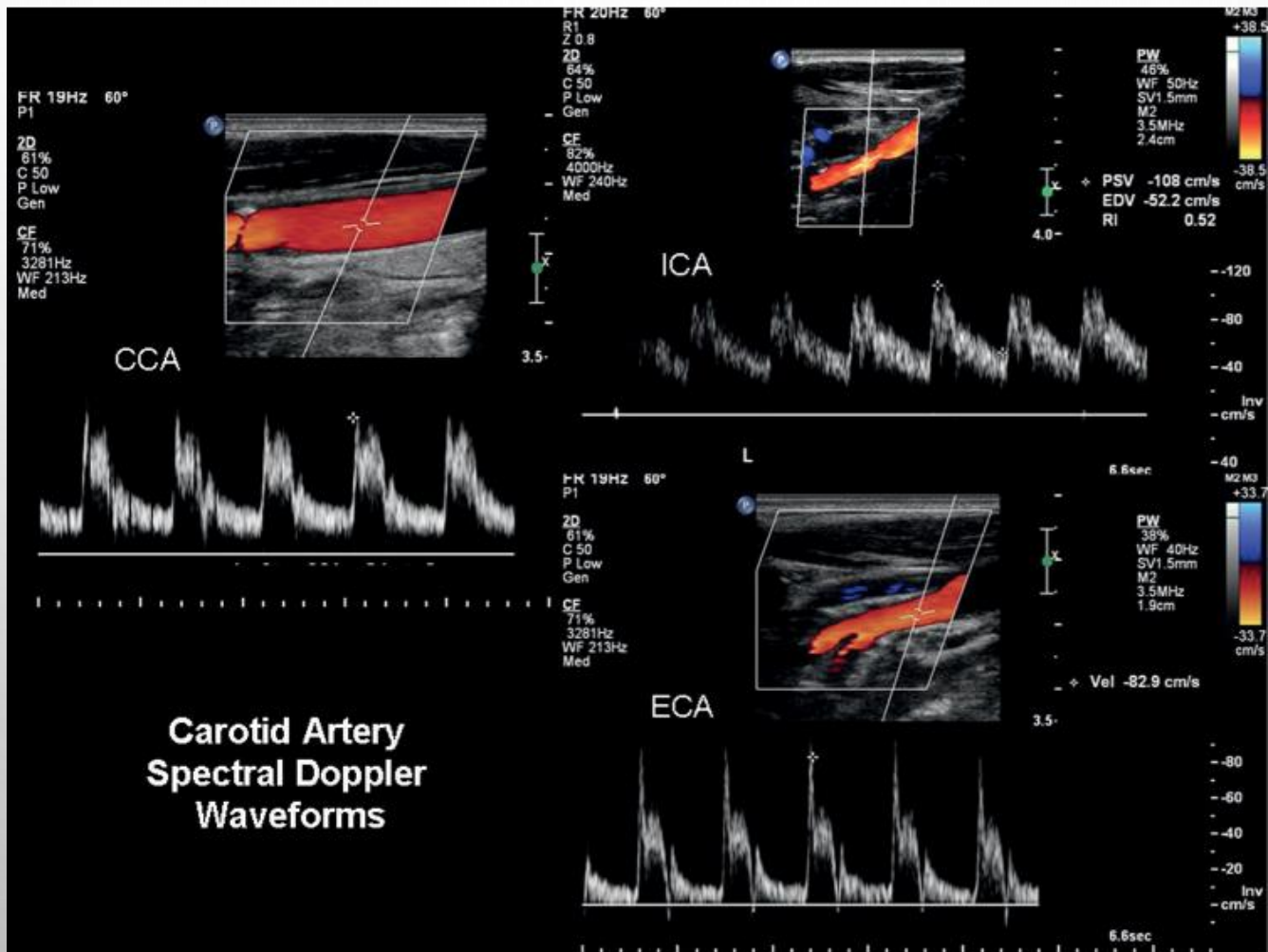
Place cursor in center of artery



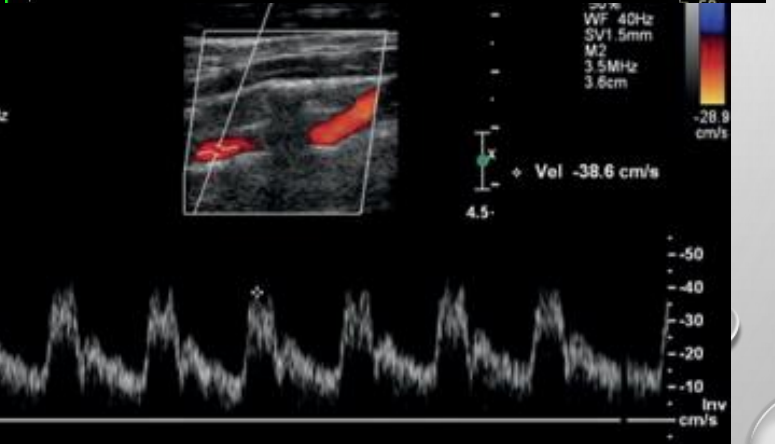
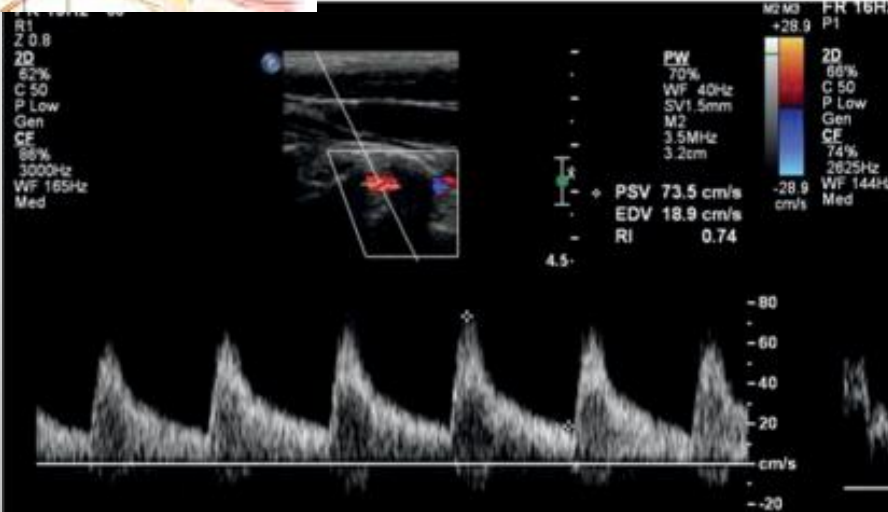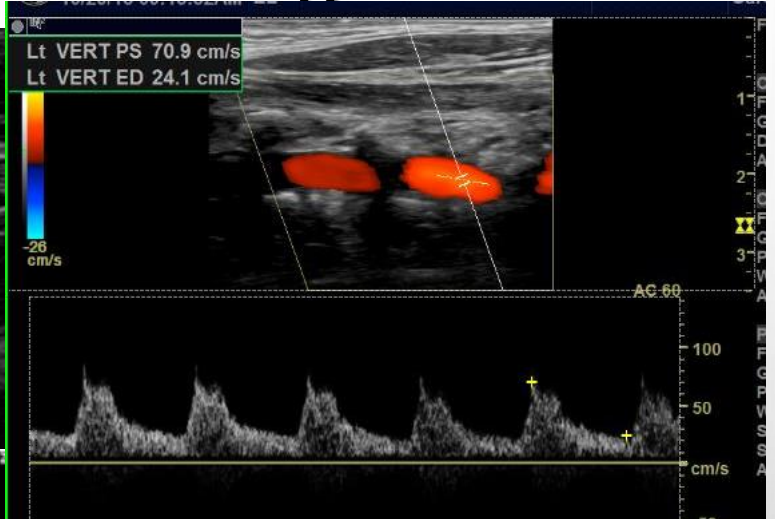
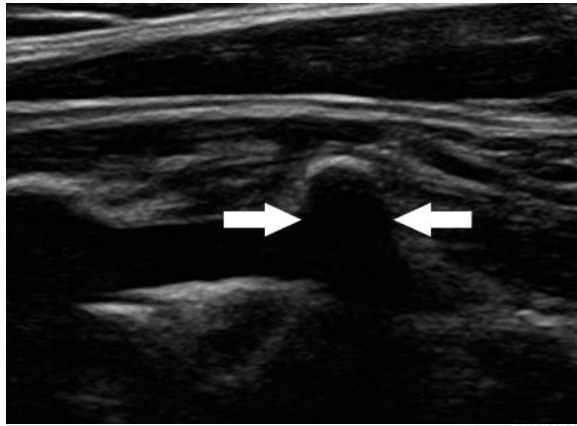
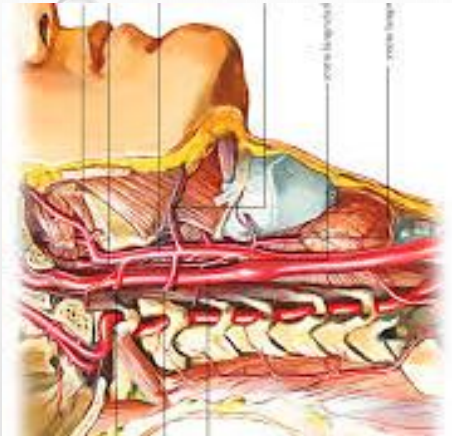
Cursor toward
or gate to wide
broadening (no



Know CCA, ICA, ECA Doppler waveforms

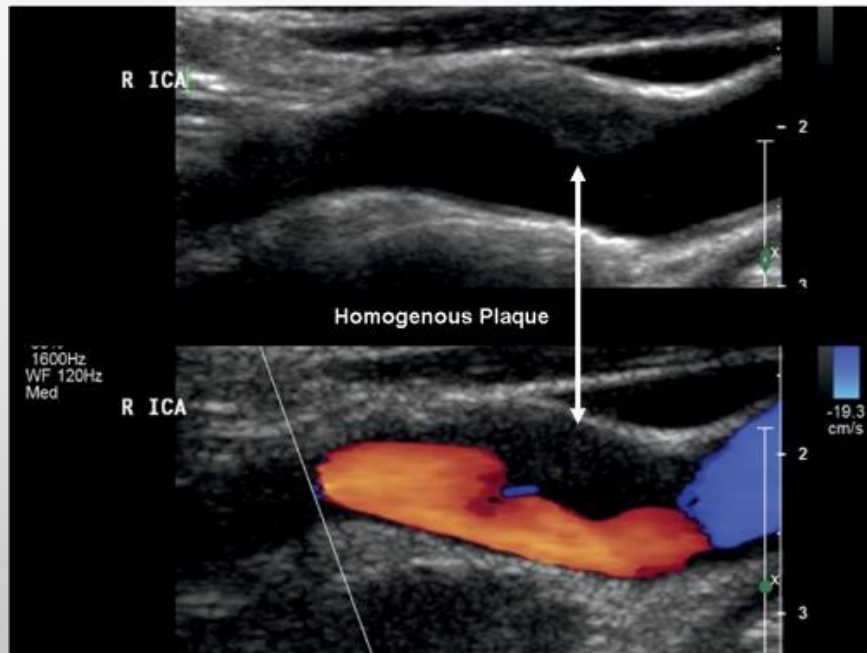


Use CCA color to determine vertebral flow is also antegrade

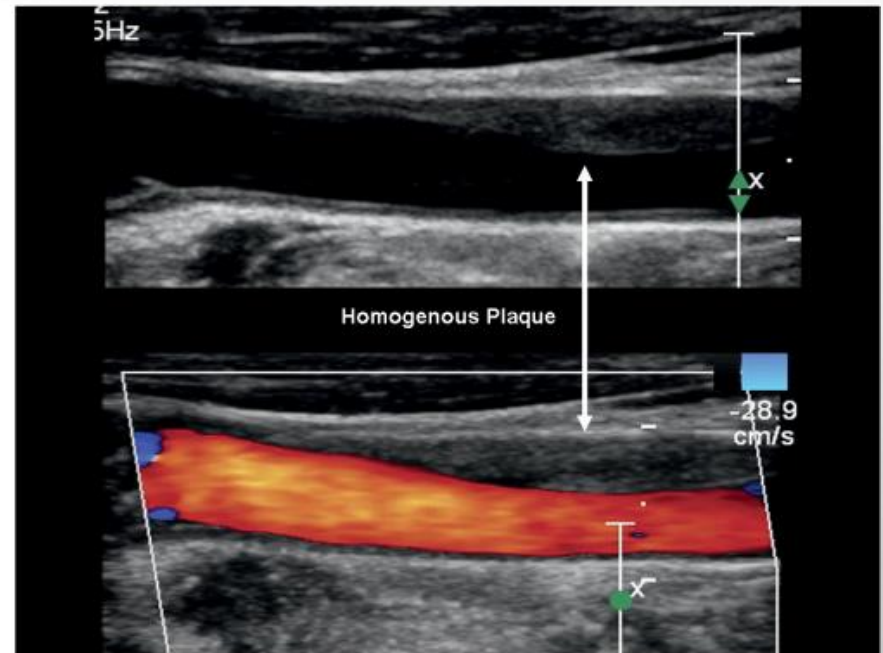


Normal Vertebral Artery Doppler Waveform Contour

Color will help to show plaque if gains too low

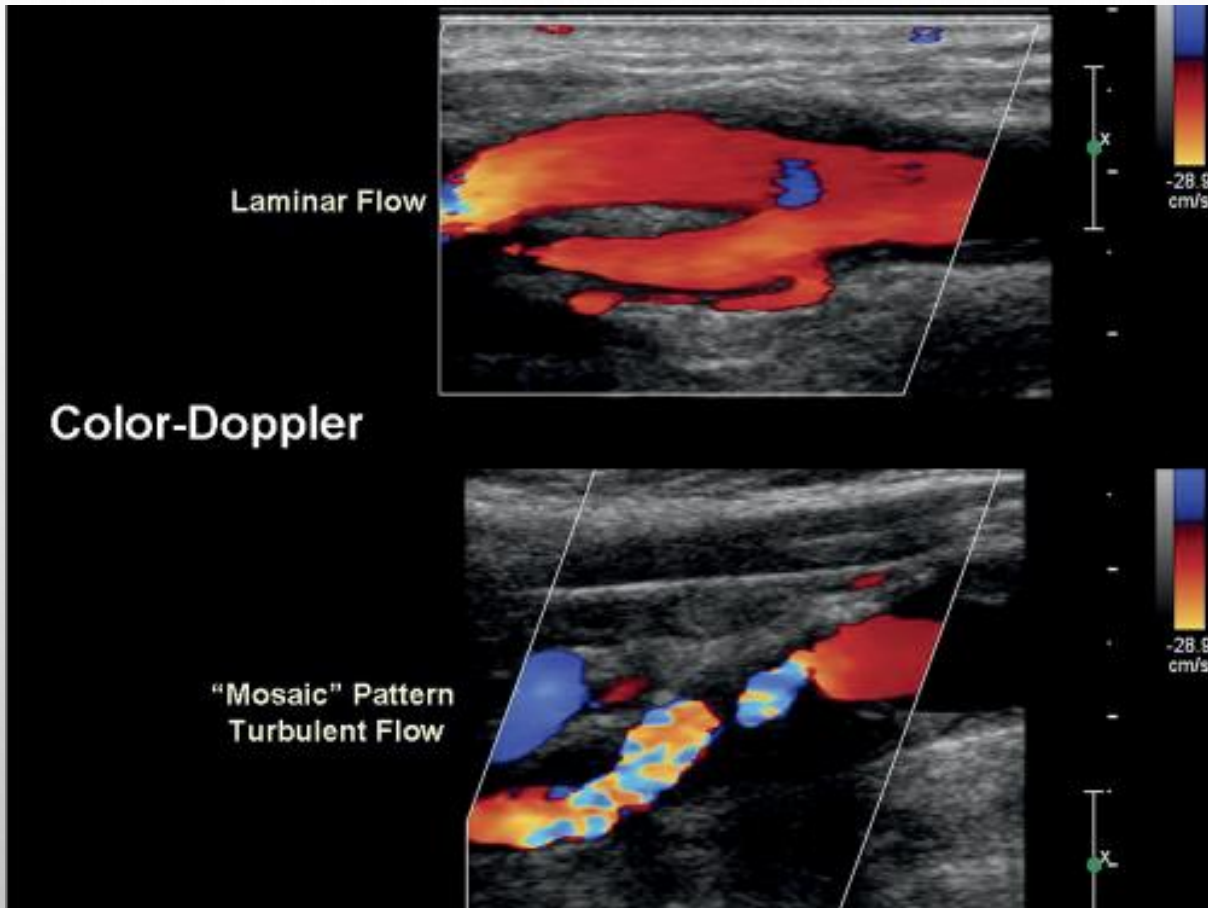


A



B

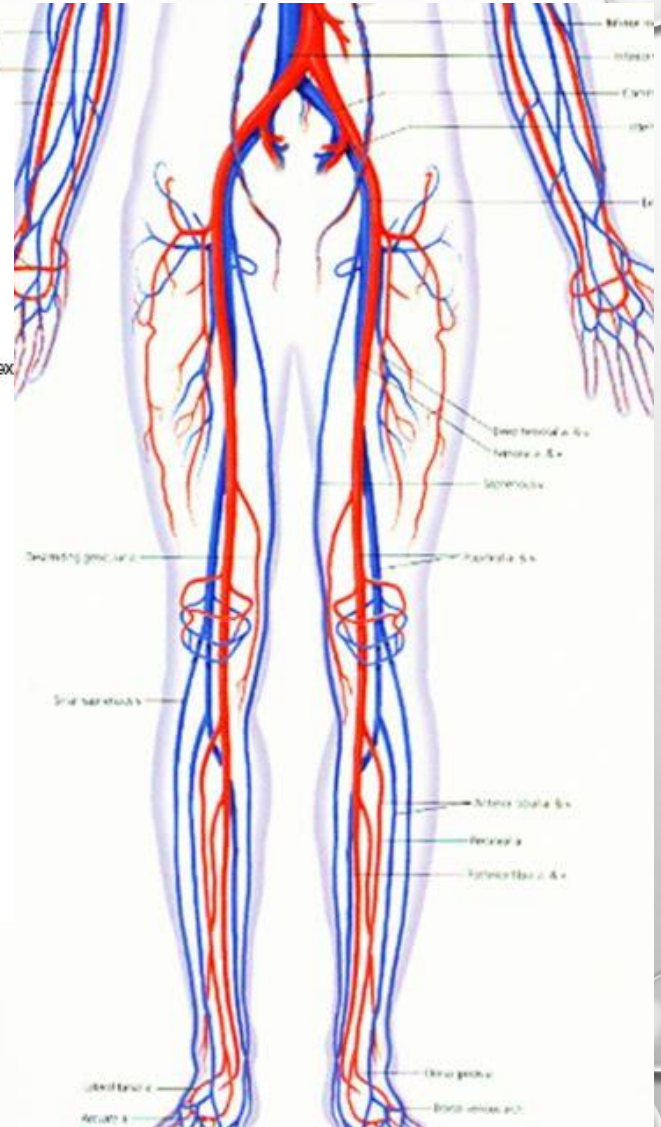
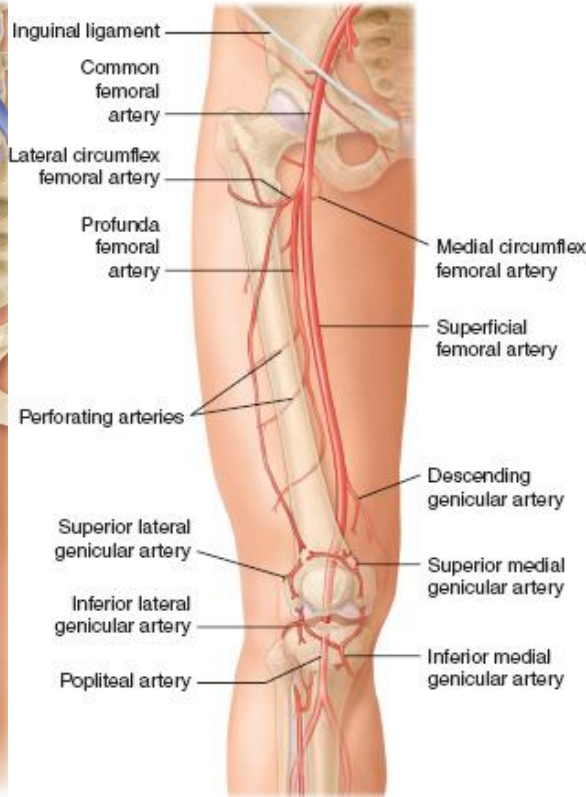
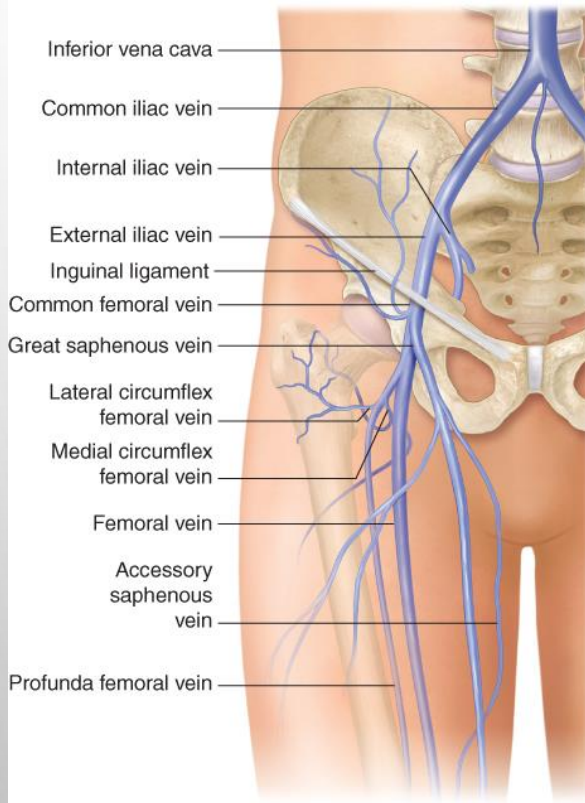
Doppler and Color Images MUST make sense!



The background of the slide is a light gray gradient with several realistic water droplets of various sizes scattered across it. The droplets have highlights and shadows, giving them a three-dimensional appearance. The text is centered in the middle of the slide.

**Let's Move Down to
the Legs**

LE Anatomy



Use Correct Terminology

Upper extremity – arm vs. forearm?

- Use upper arm and lower arm

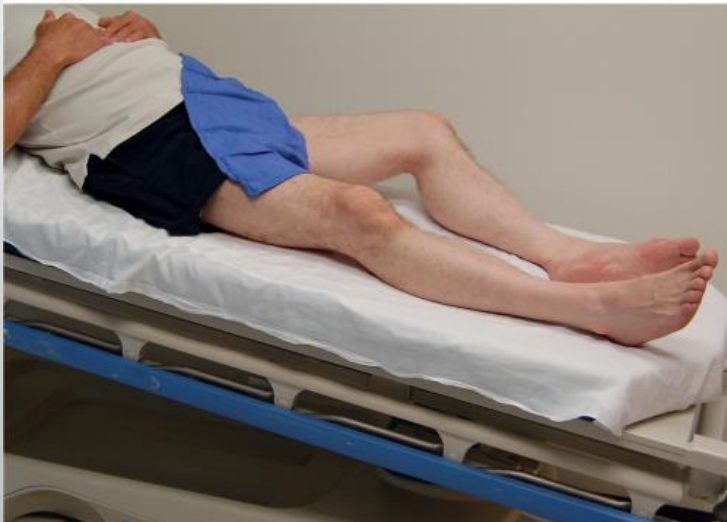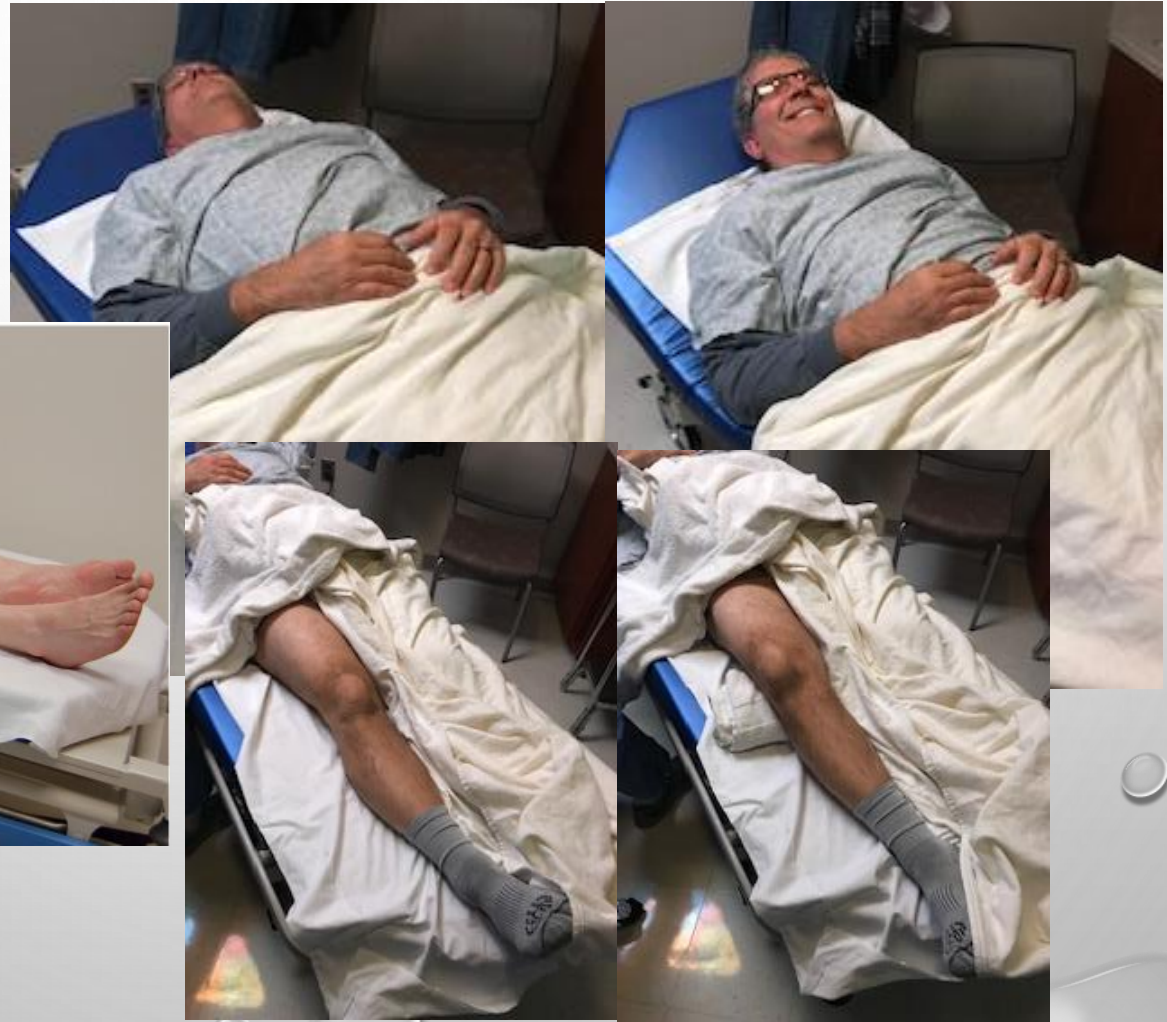Lower extremity - thigh vs. calf?

- Use upper leg to knee and lower leg to ankle

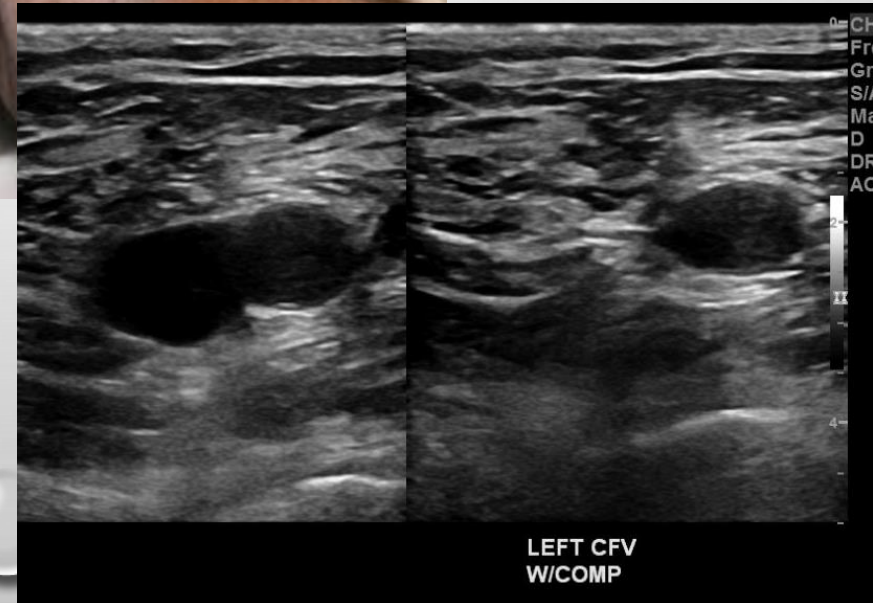
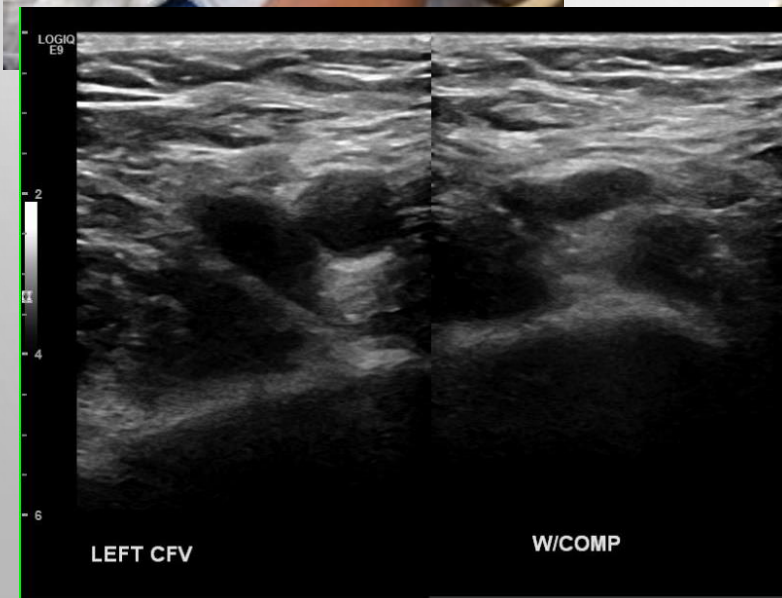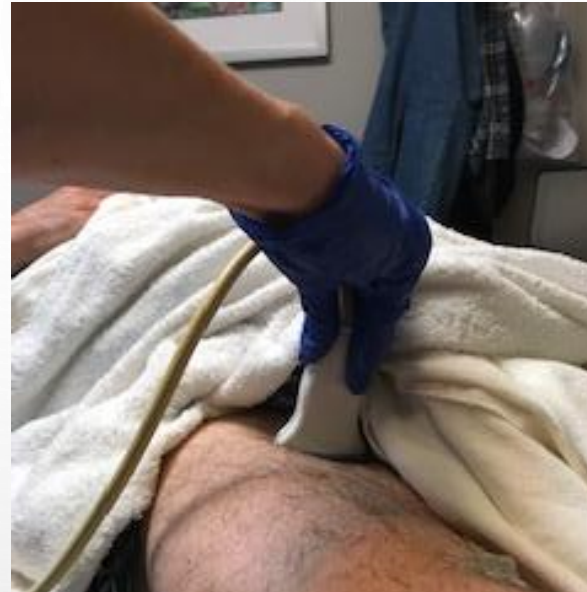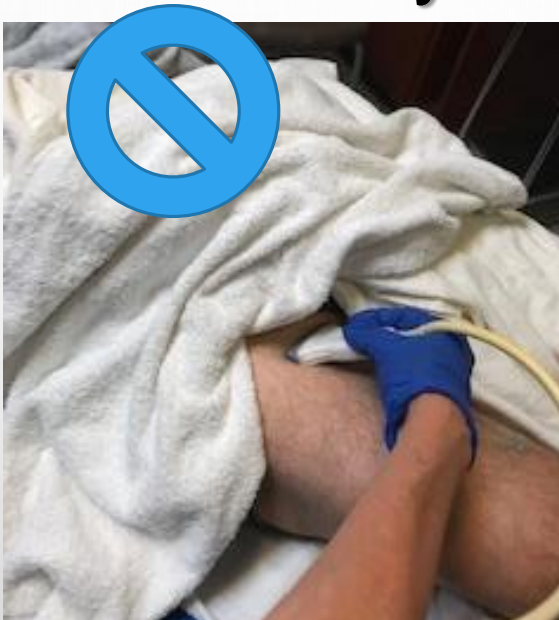LE venous – use femoral vein (FV) not SFV

Use universal language – plaque, stenosis, occlusion, occlusive vs non-occlusive thrombus

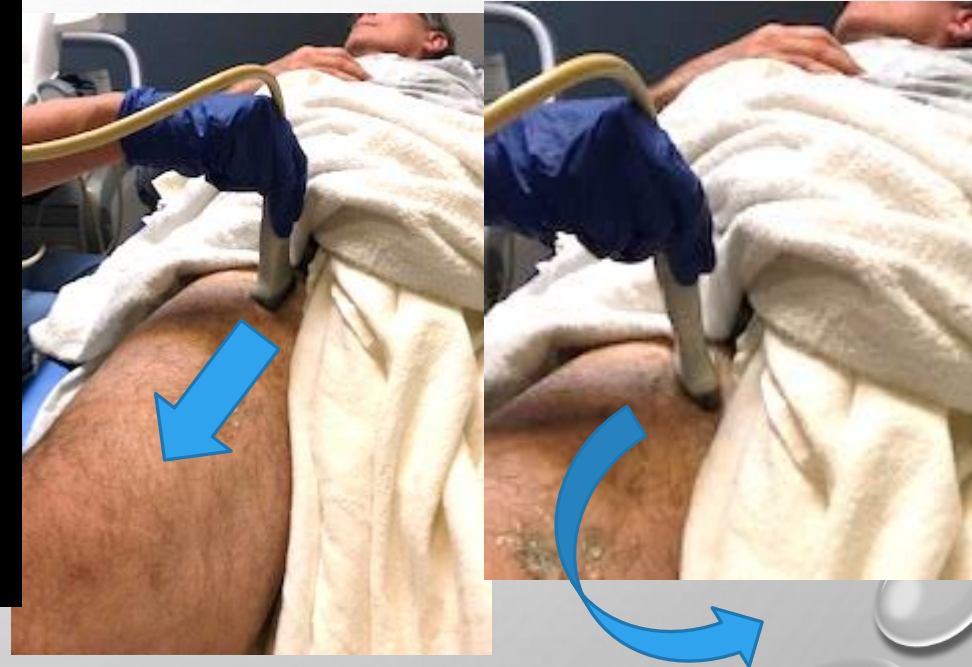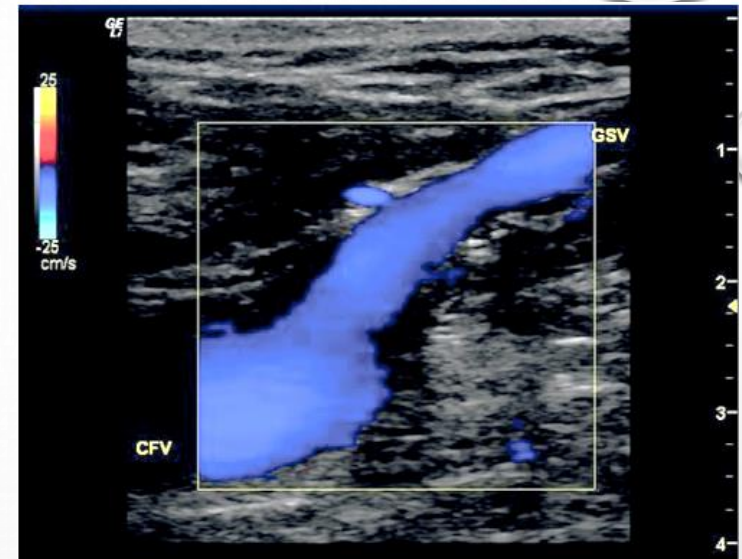
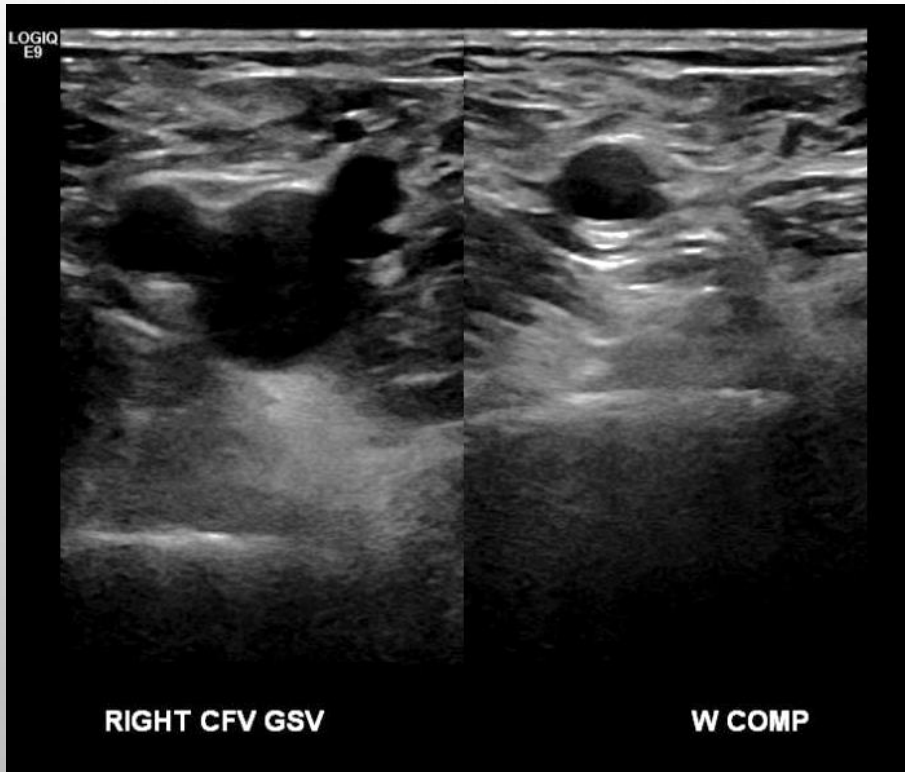
Head should be higher than body
Put towel under knee



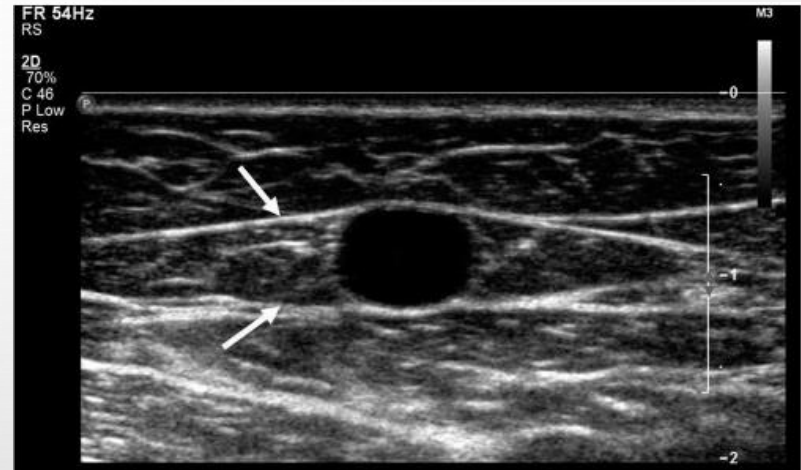
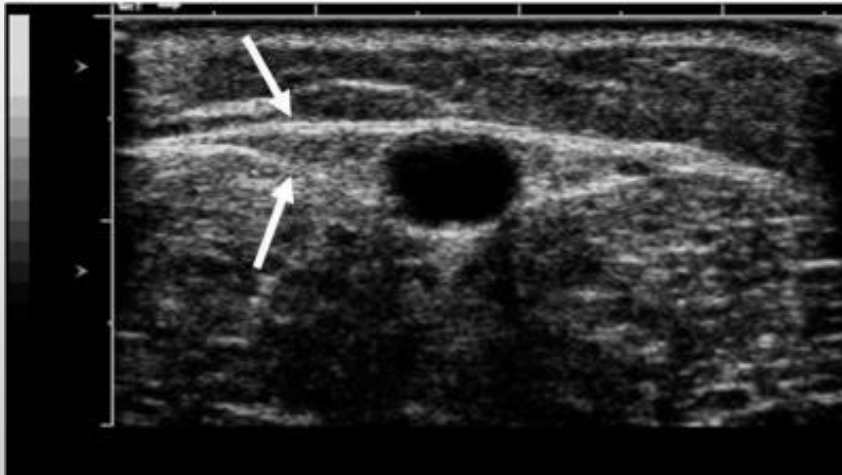
Start transverse in mid groin and stay as perpendicular as you can



Finding the GSV swing bottom of transducer medially

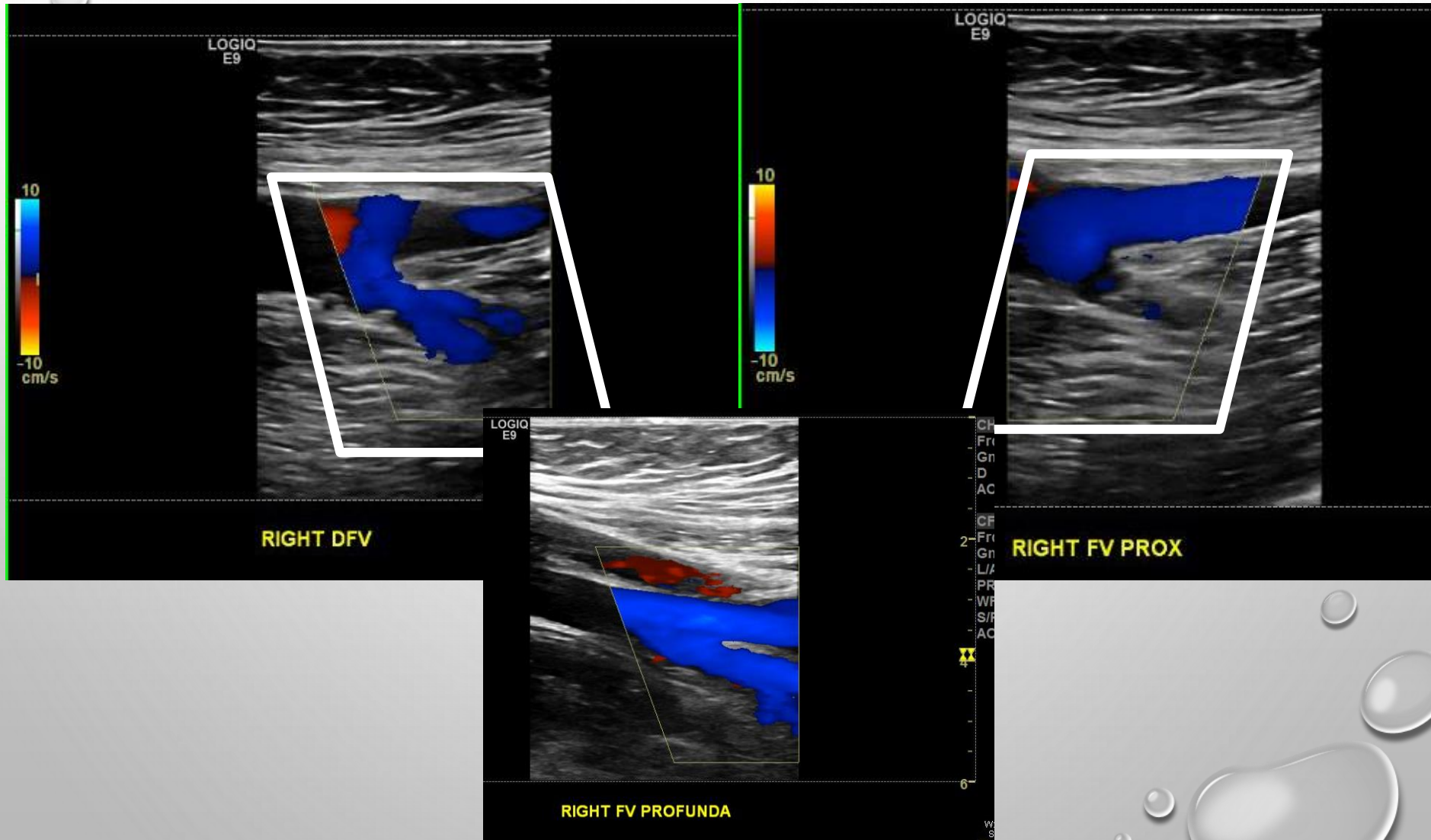


Superficial Veins are distinct
No artery alongside
Look for the “Egyptian eye”

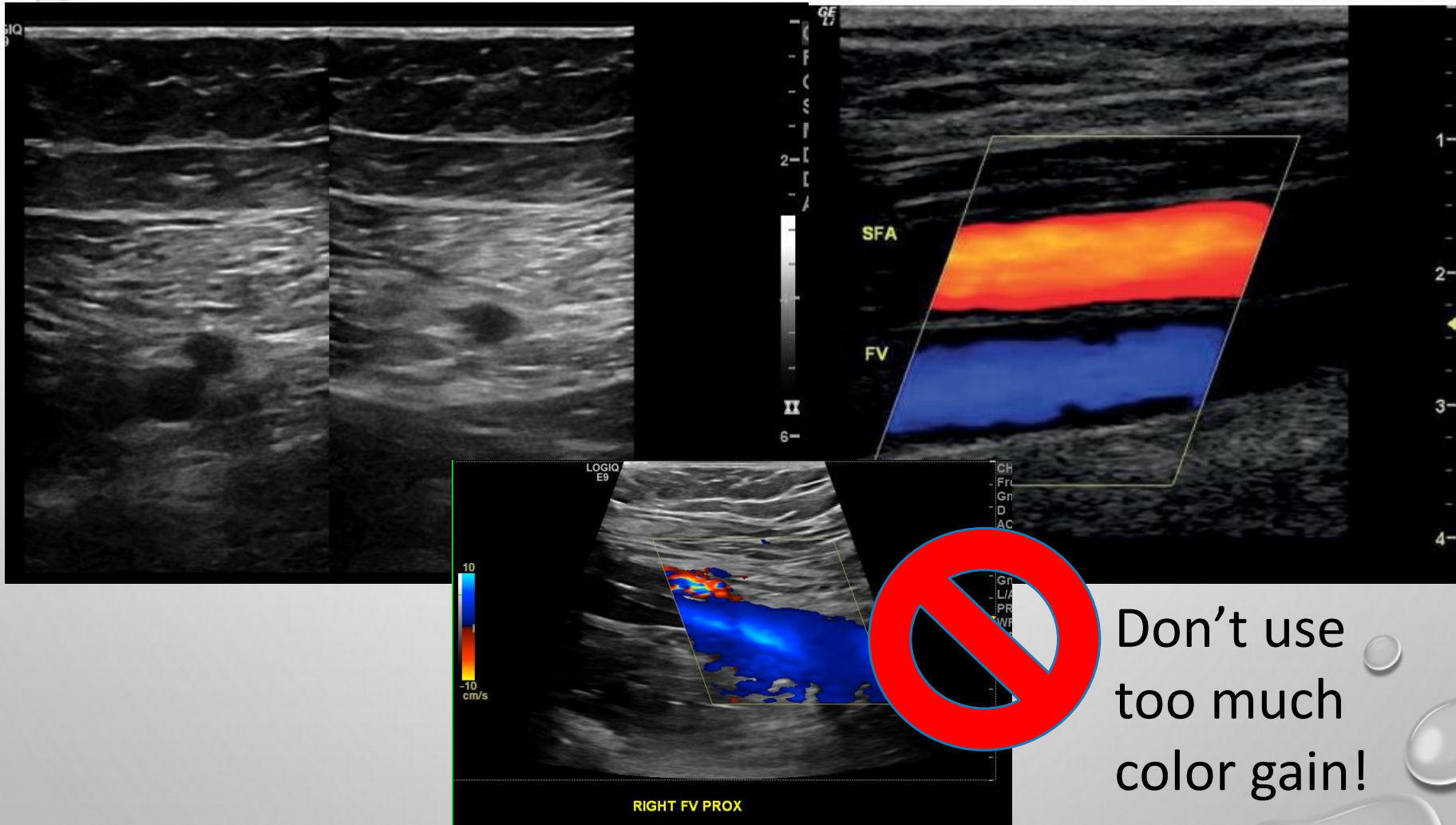


Kupinski, Ann Marie, *The Vascular System*, 2nd edition, Wolters Kluwer, 2018.

Watch color angles to fill in veins

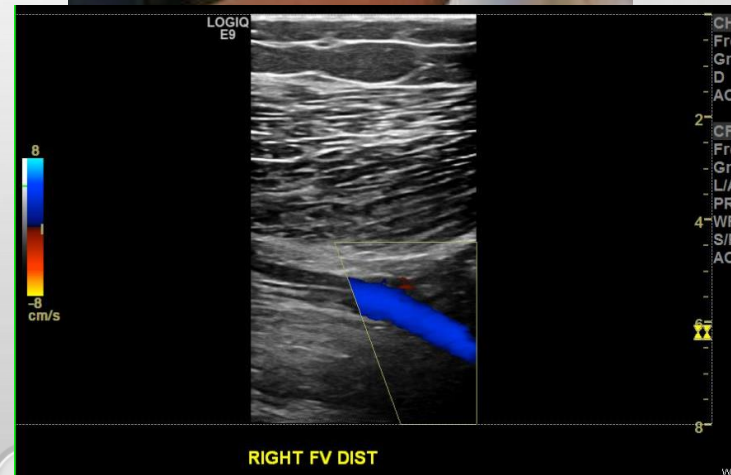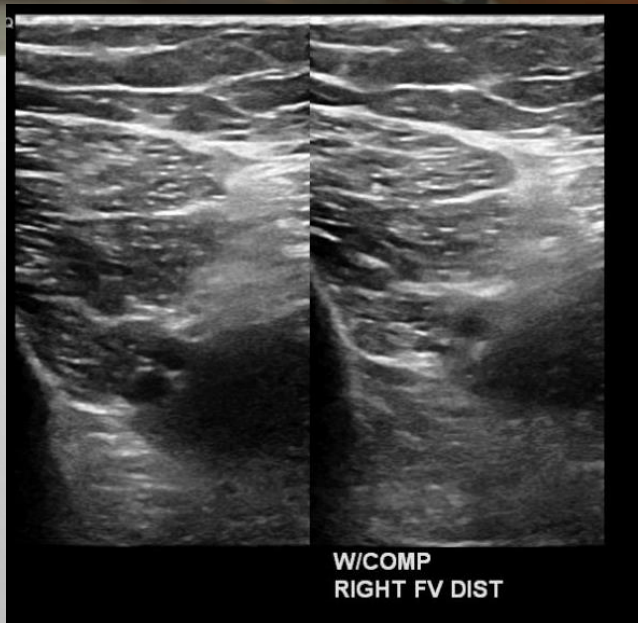

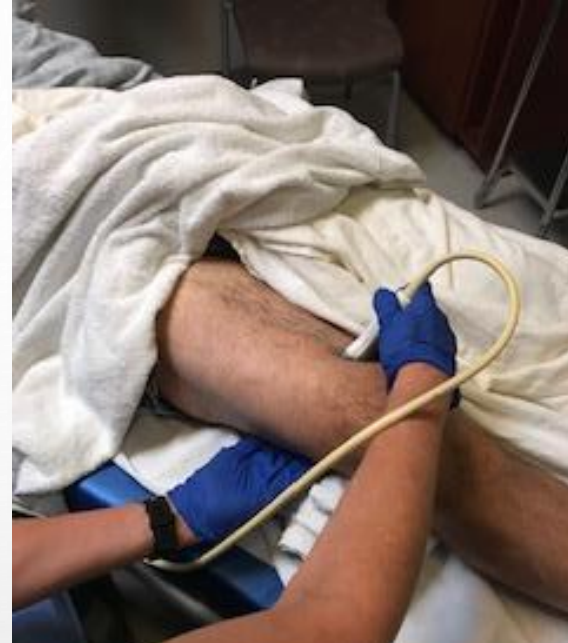
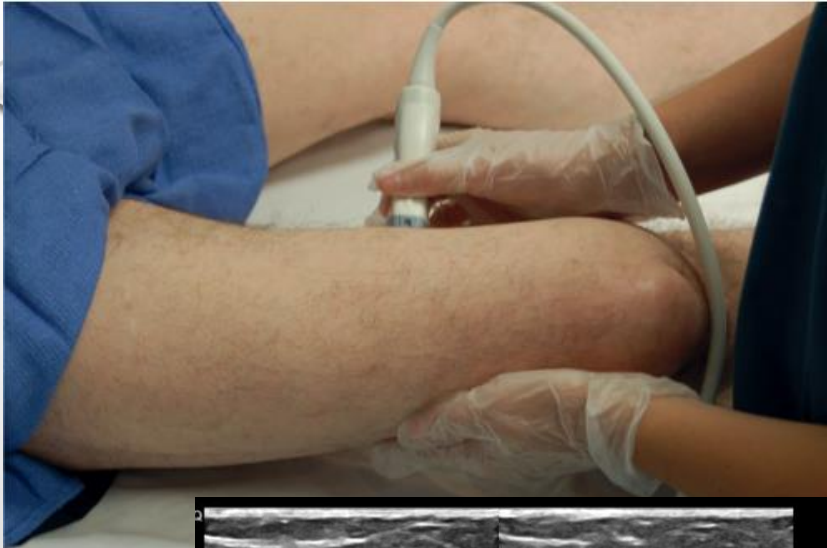Follow vein with artery

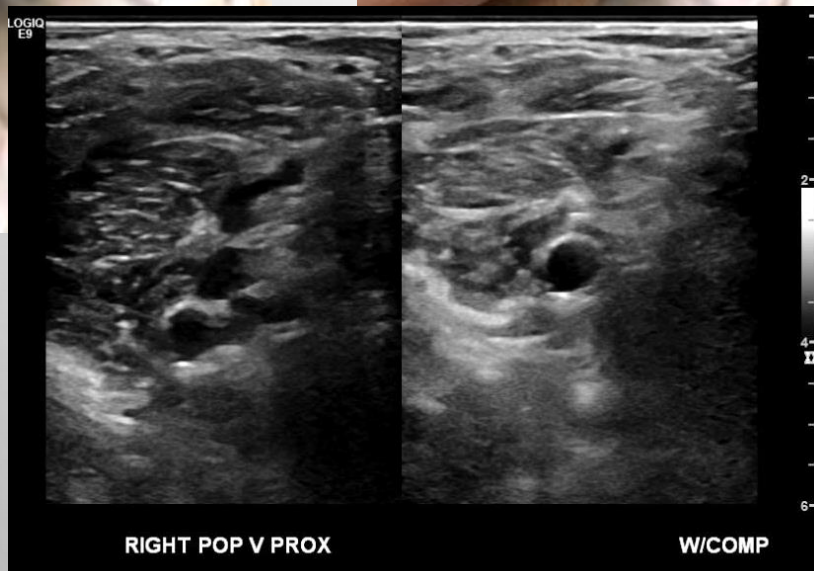
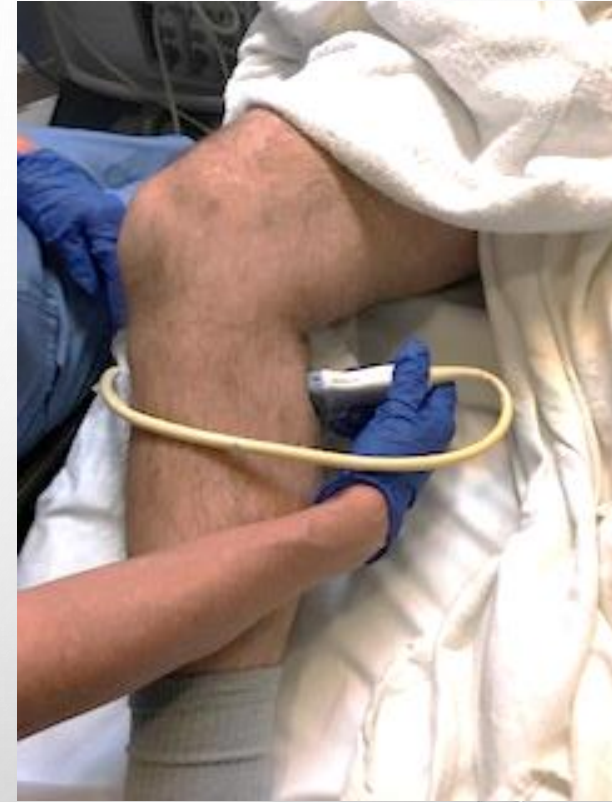
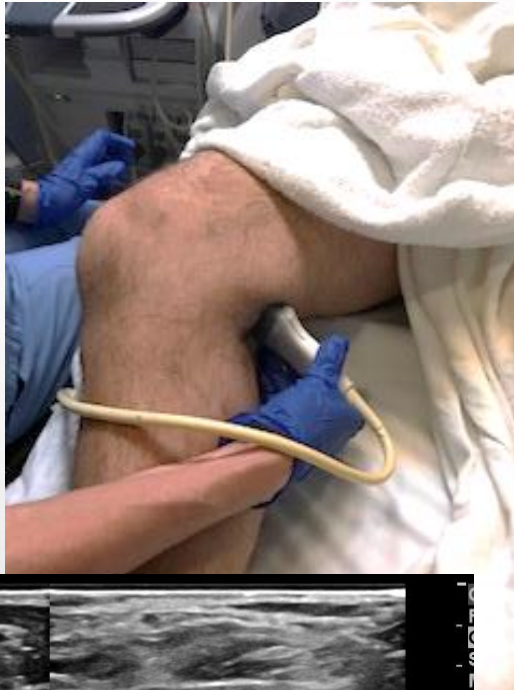
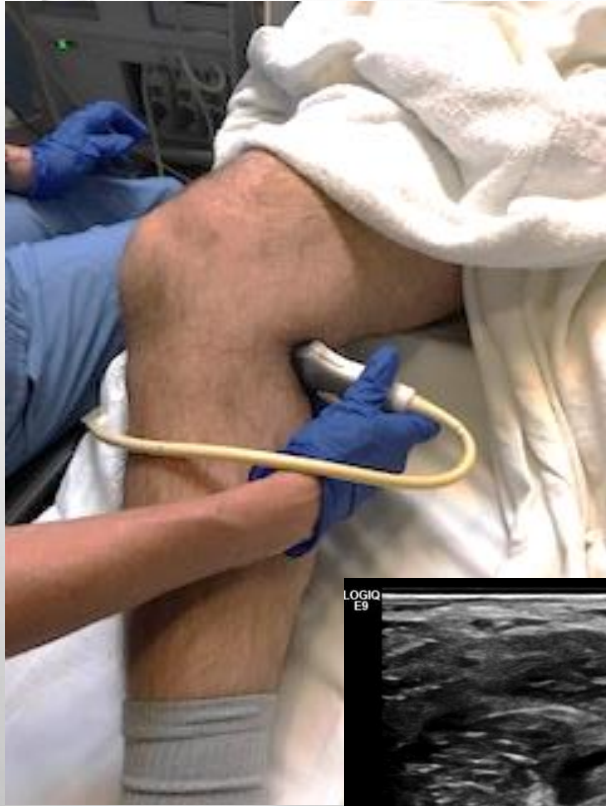Don't use
too much
color gain!

Distal FV Compression



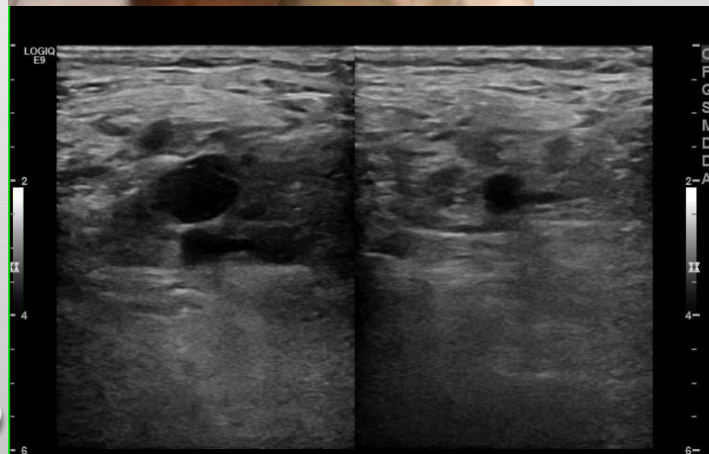
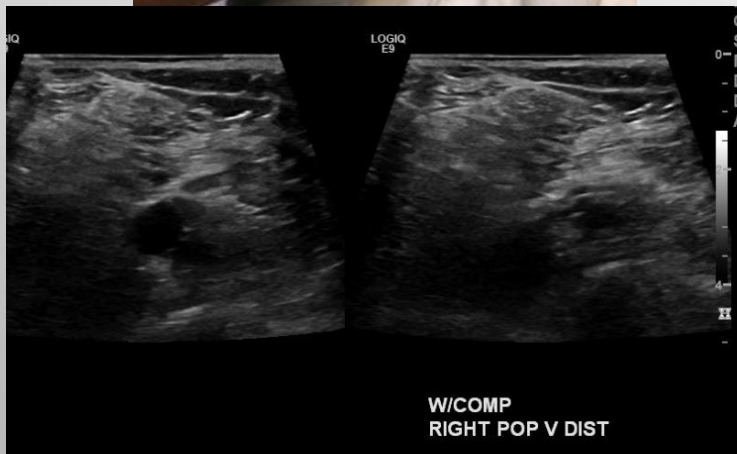
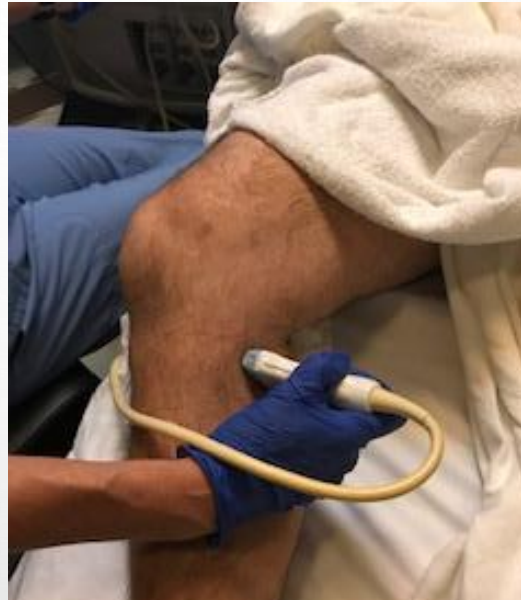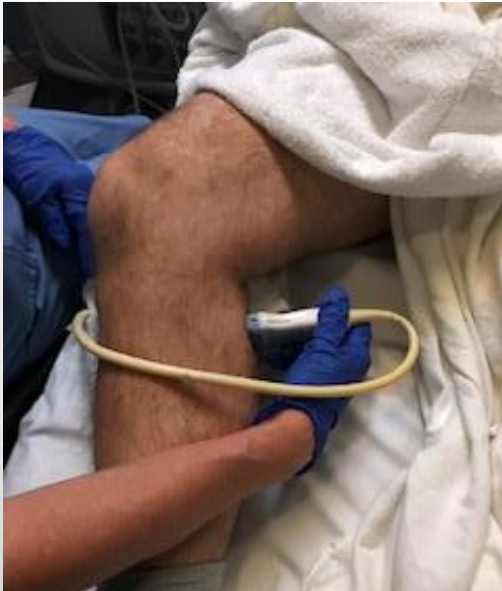Finding the Popliteal Vessels



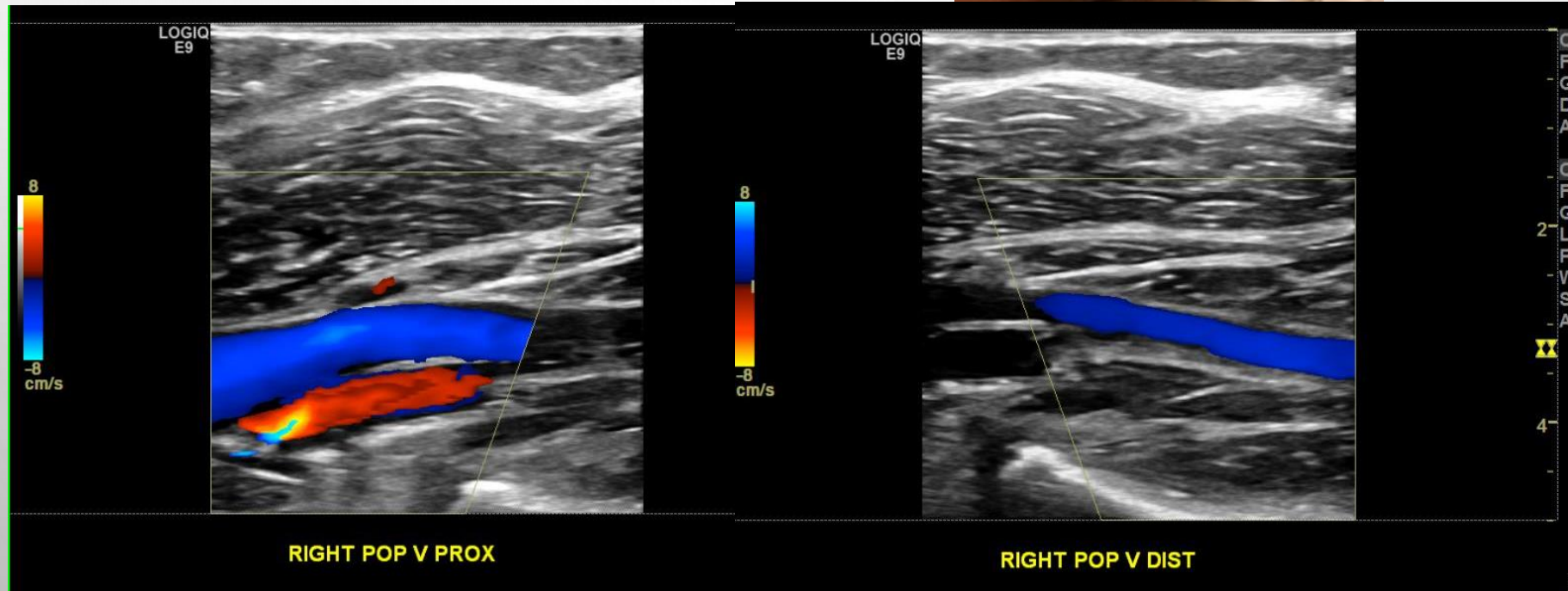
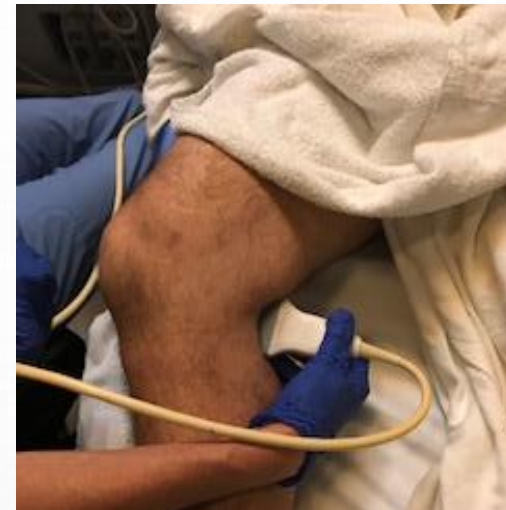RIGHT POP V PROX

W/COMP

Finding distal Popliteal Vein slide more medial

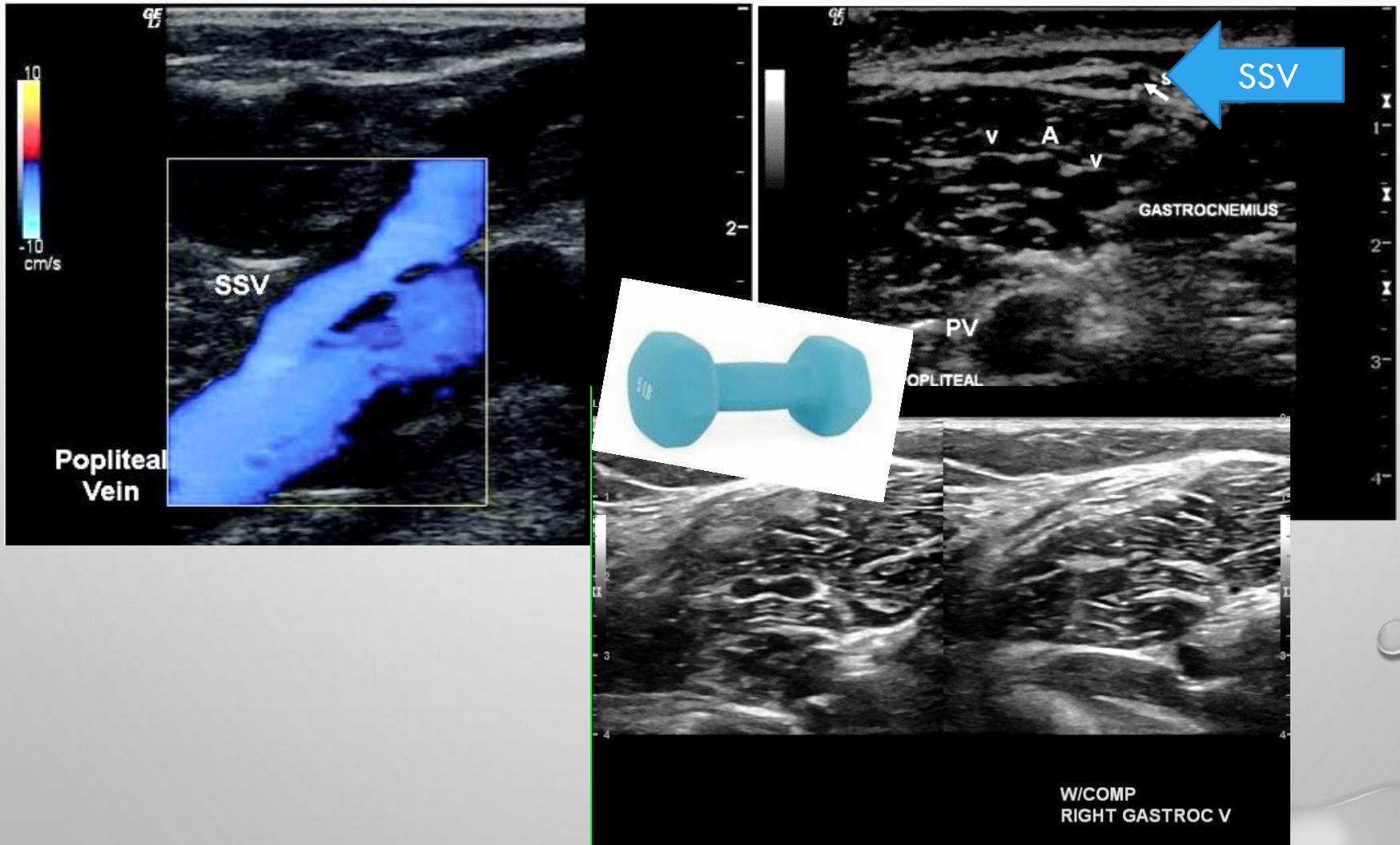


From posterior approach
Popliteal Vein now
anterior to artery

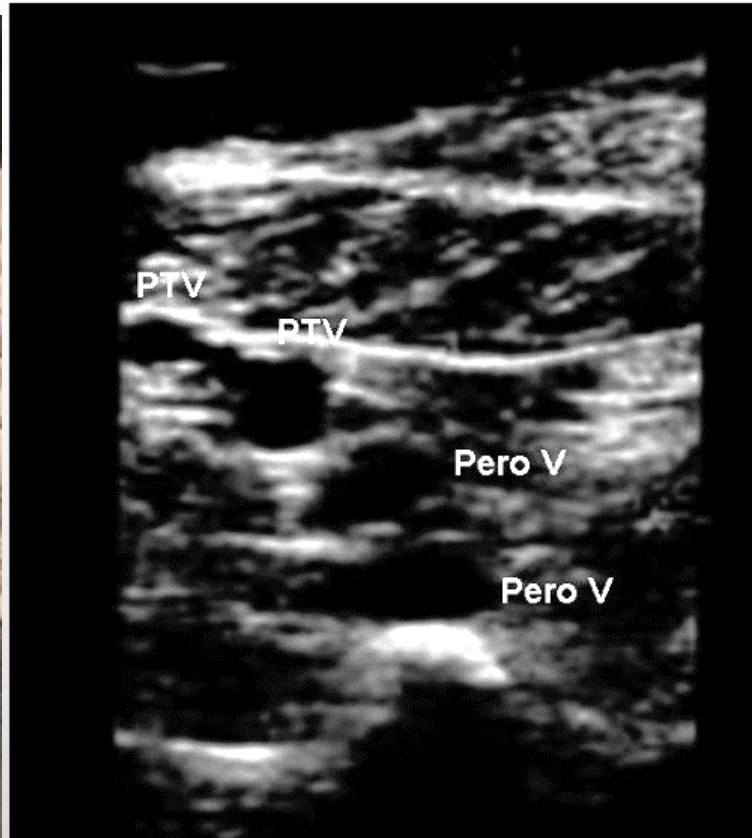
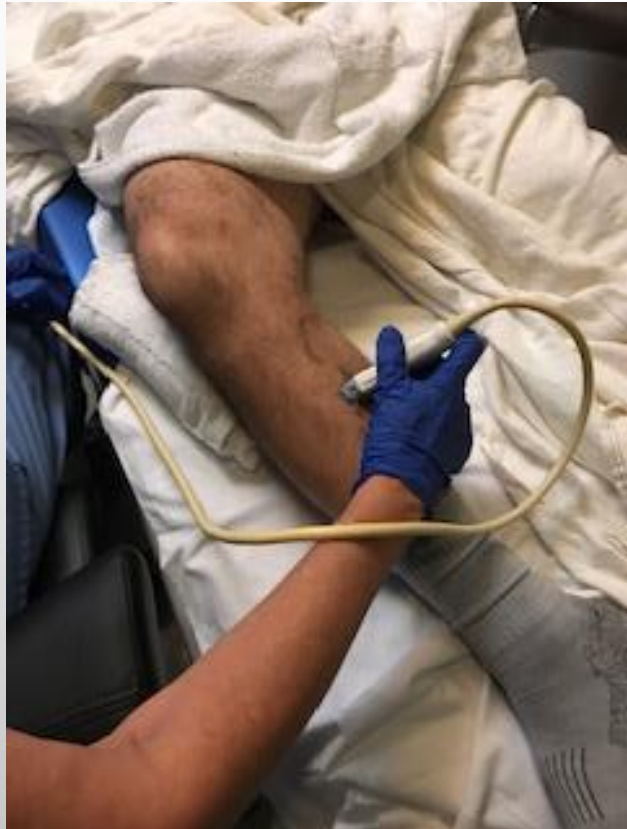

Kupinski, Ann Marie, *The Vascular System*, 2nd edition, Wolters Kluwer, 2018.

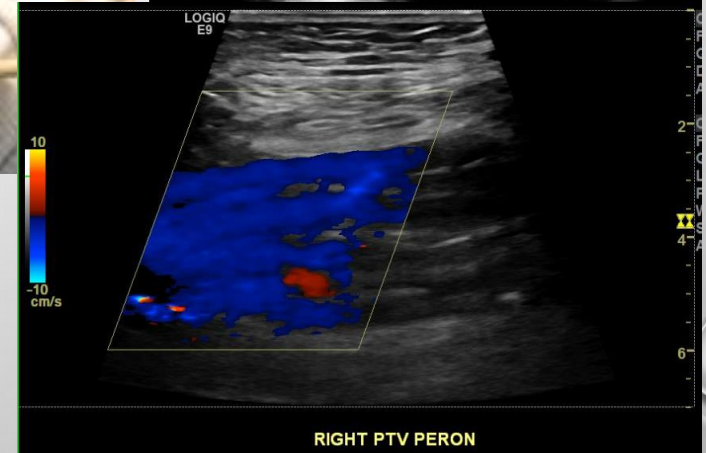
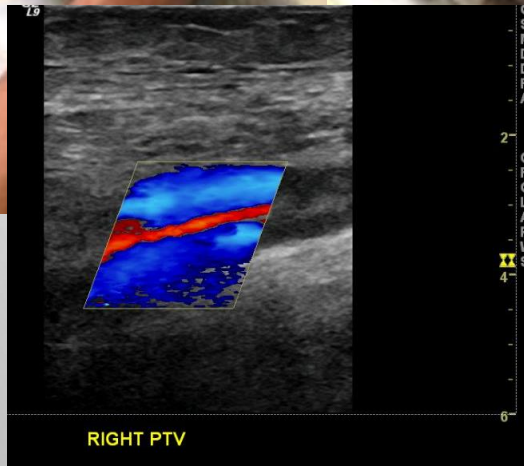
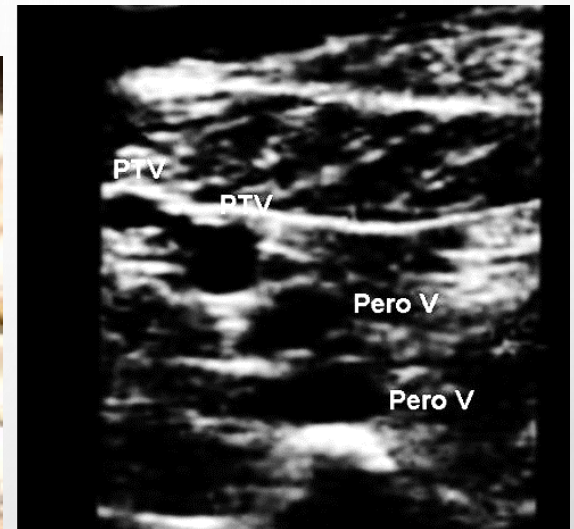
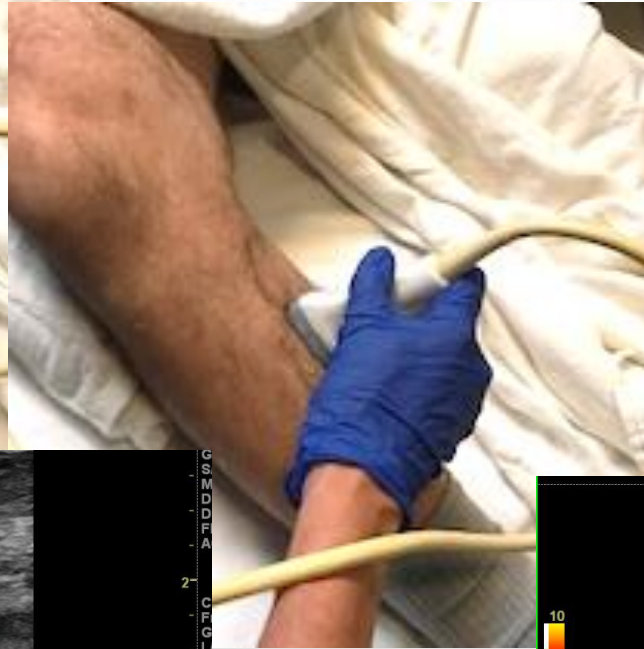
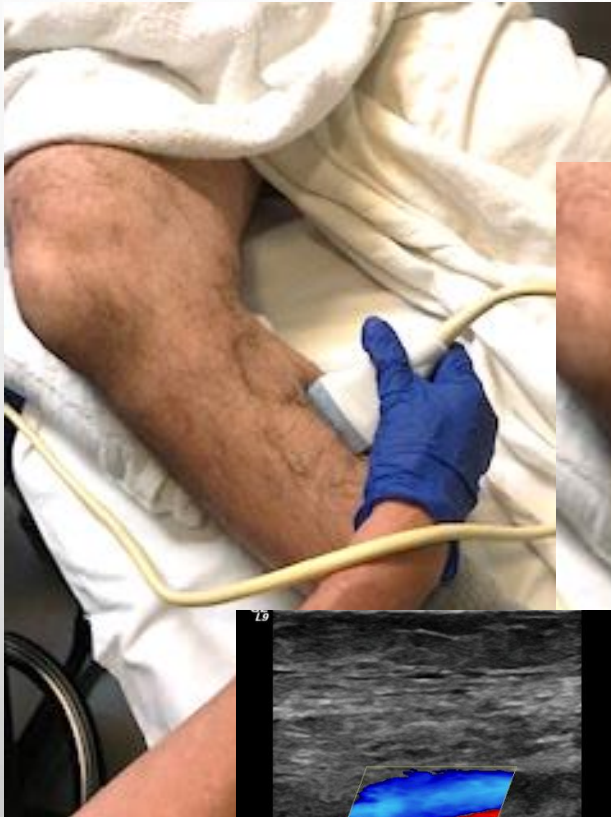Gastrocnemius Vein



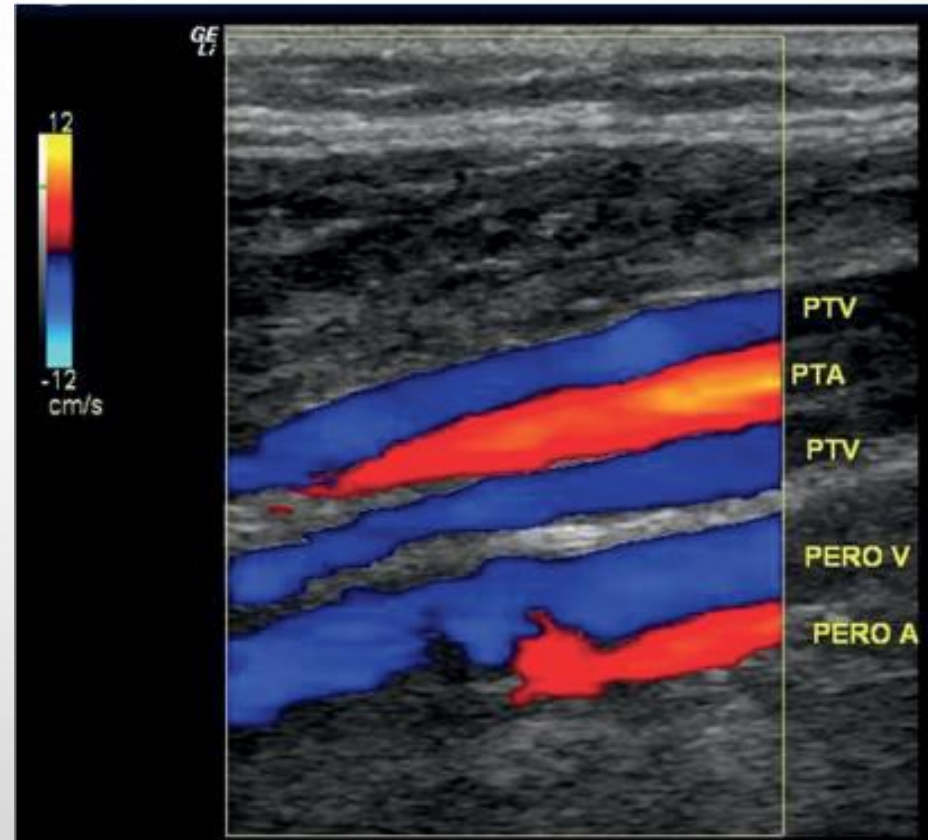
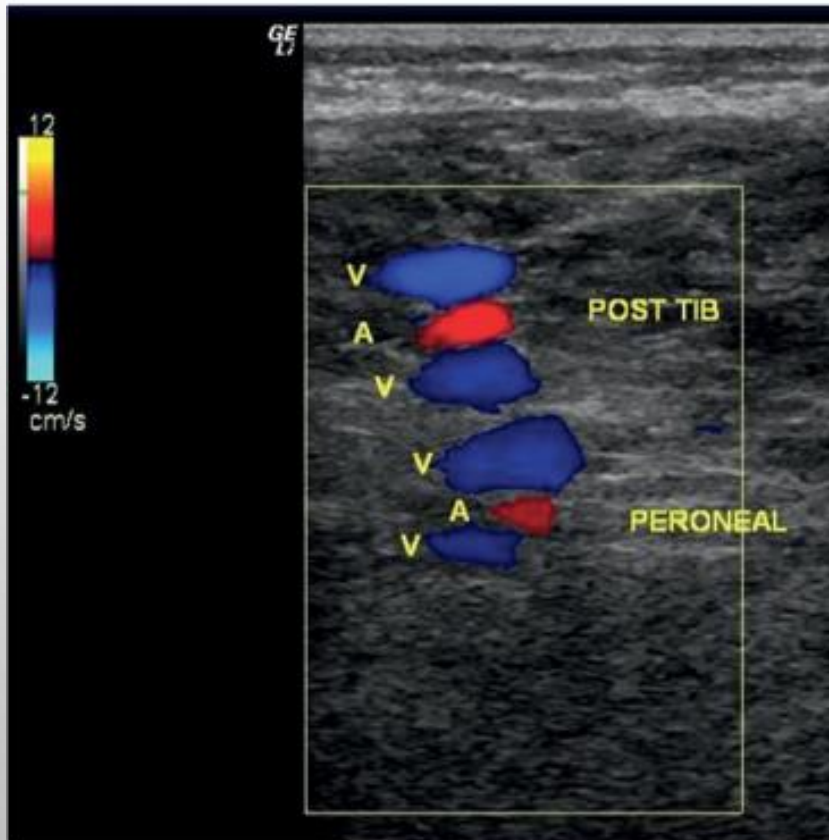
Finding PTV and Peroneal Veins



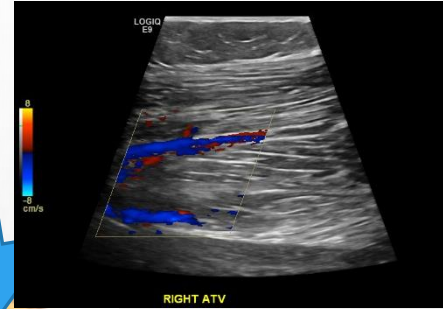
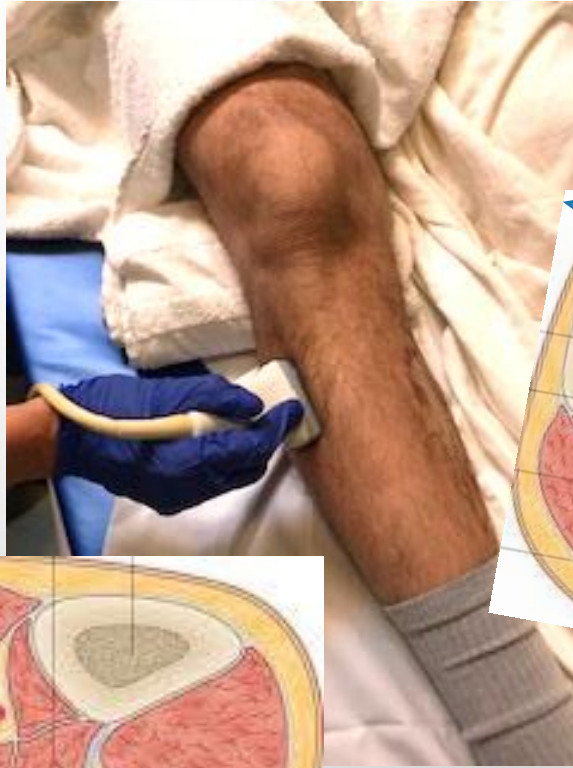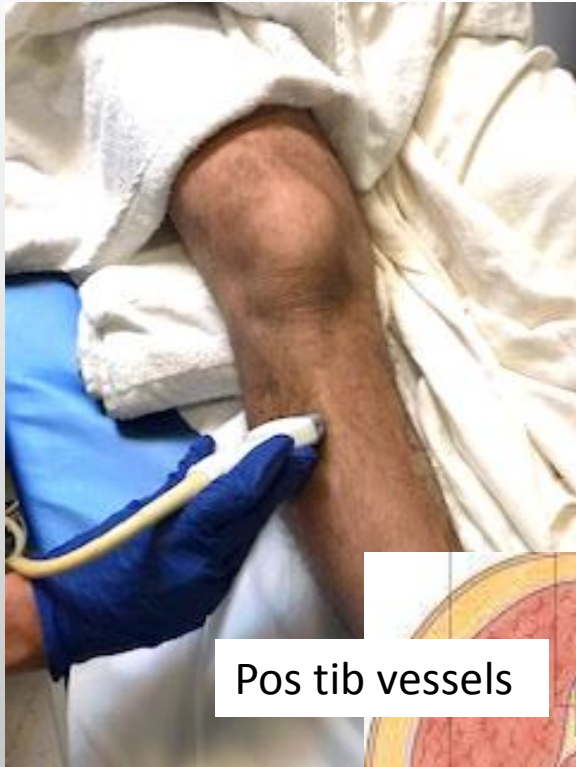
Some tricks to find calf veins Come closer to tibia



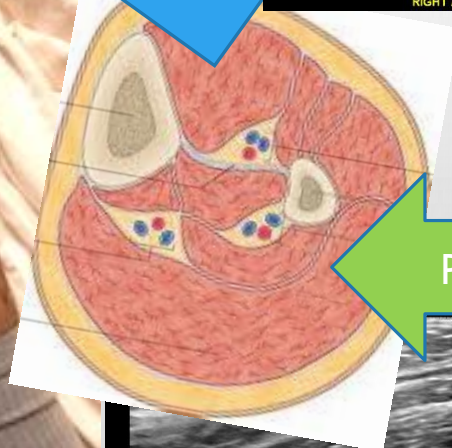
PTV and Peroneal Veins



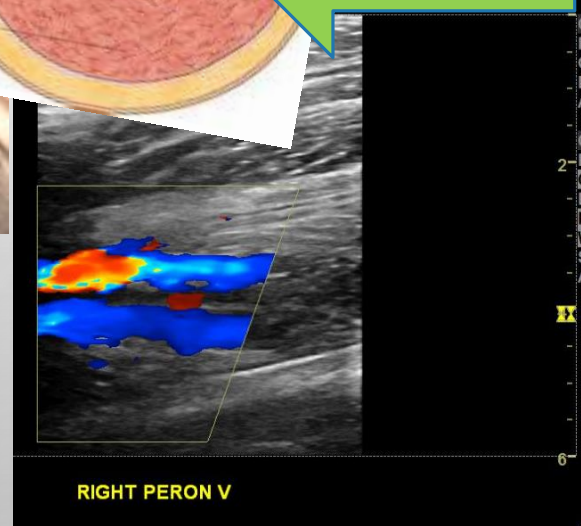
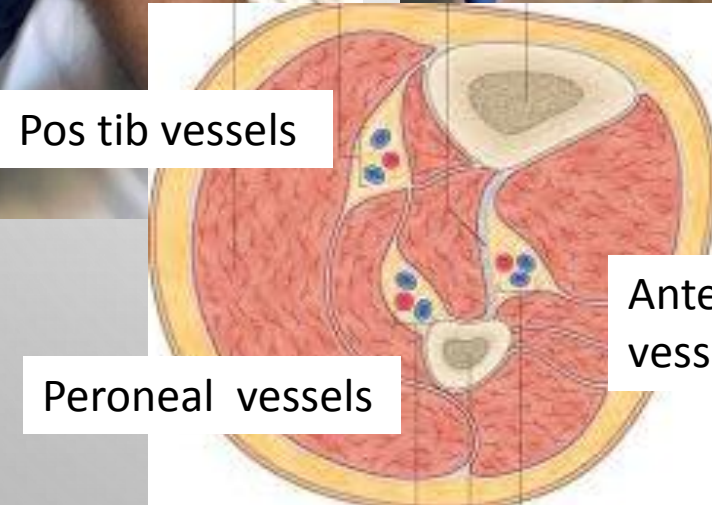
ATV window and another great way to see Peroneal Veins



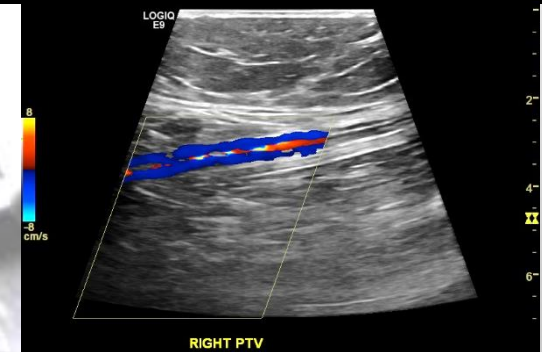
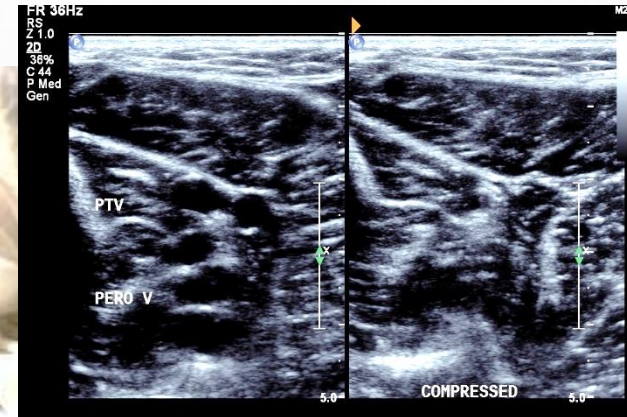
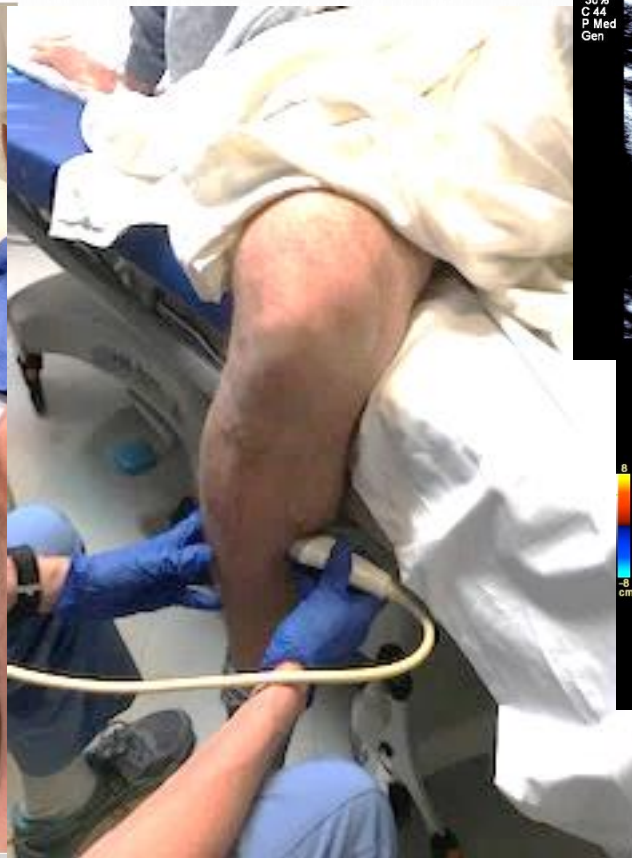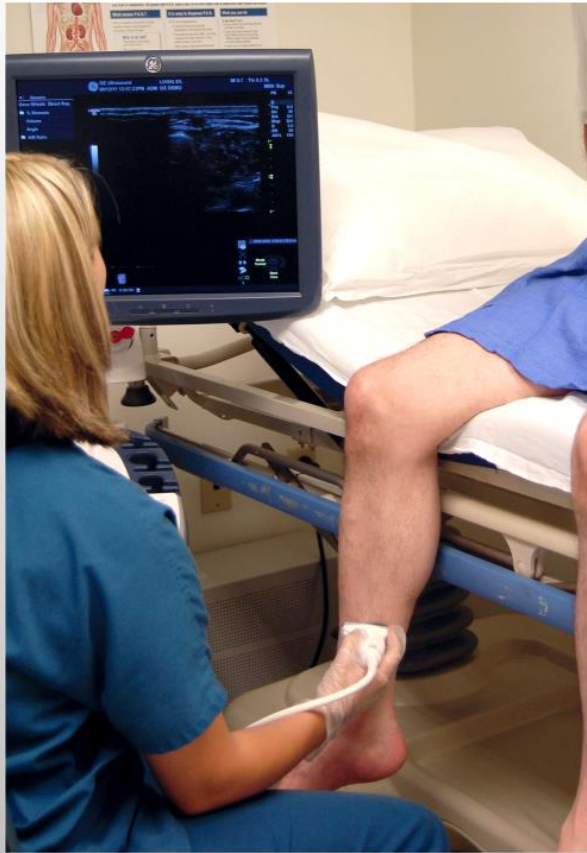Ant tib



Peroneal



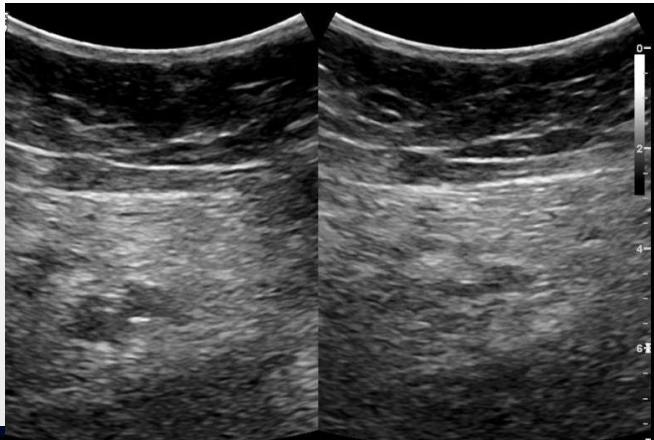
Dangle legs to find Calf Veins



Kupinski, Ann Marie, *The Vascular System*, 2nd edition, Wolters Kluwer, 2018.

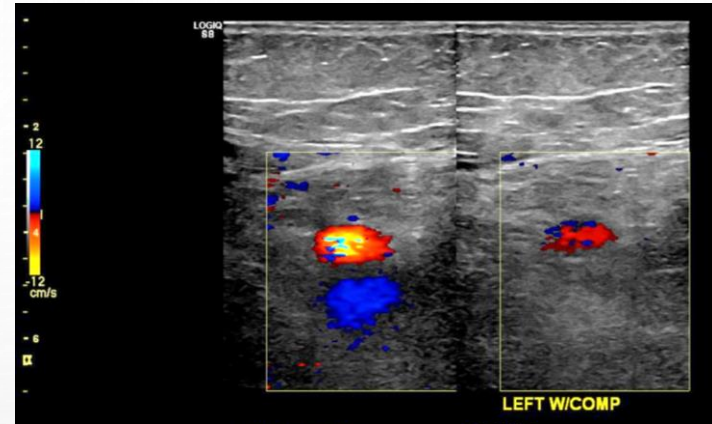
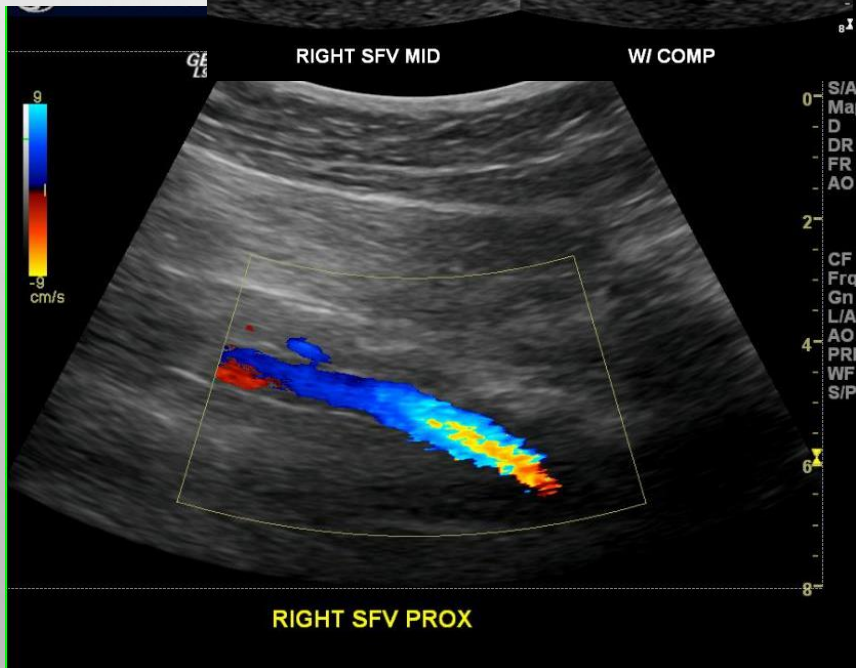
Tough Study?

Curvilinear can be your best friend



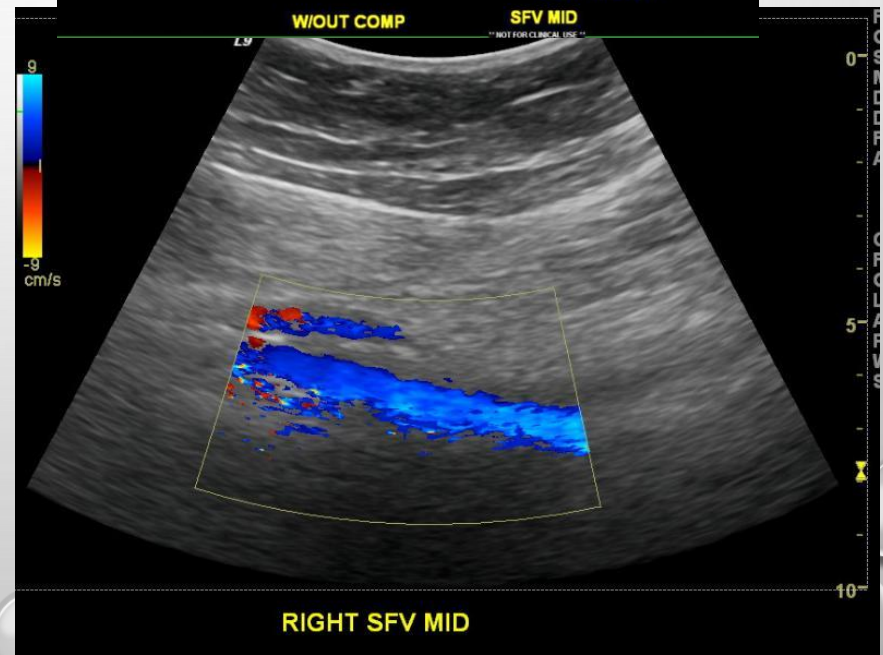
RIGHT SFV MID

W/ COMP

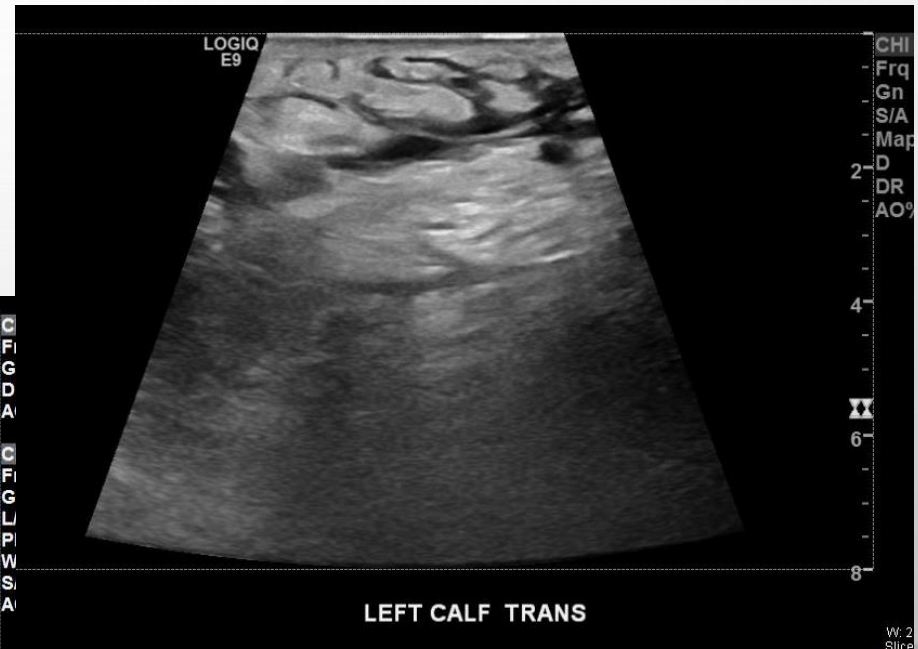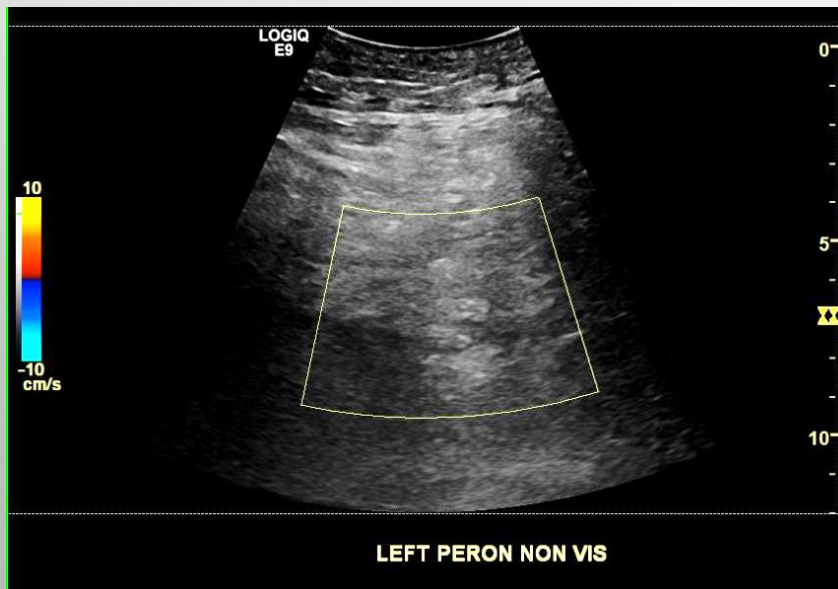
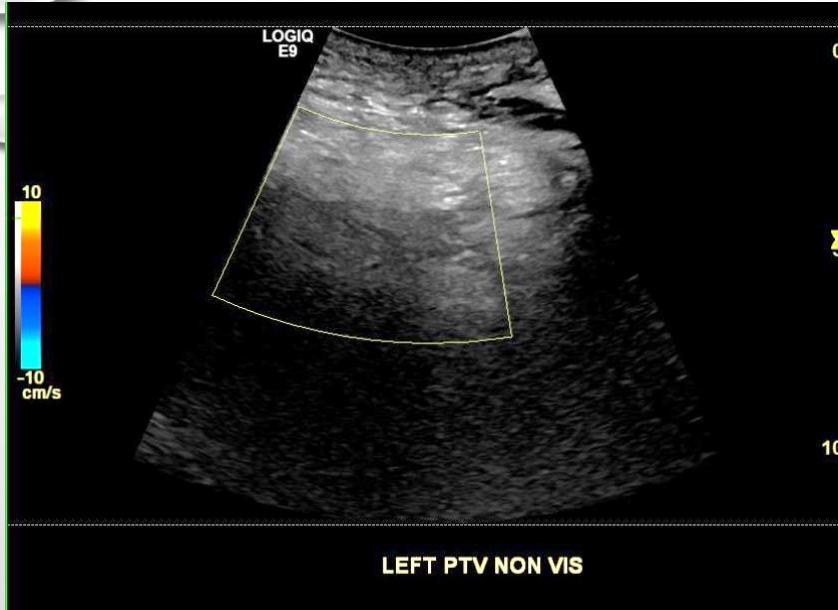


W/OUT COMP

SFV MID



Know your limitations and document



Remember the Secrets!

- Know your anatomy and landmarks
- Direct sound more perpendicular for 2D
- Direct sound more parallel for color and Doppler
- Survey first and document with Long, Trans and color

Final Secrets!

- Ask others for their tricks and tips
- Try to do as many as you can in a day or week
- Practice - practice - practice
- Obtain your RVT credentials to open more doors for your career!



References

- Hagen-Ansert, Sandra, *Textbook of Diagnostic Sonography*, Elsevier, 8th edition, 2018.
- <https://www.svunet.org/blogs/christine-unger/2016/04/06/calf-vein-imaging-for-the-newer-techs-you-got-this>
- <http://charlessledge.com/four-stages-competence-growth/>
- Kupinski, Ann Marie, *The Vascular System*, 2nd edition, Wolters Kluwer, 2018.
- Ridgeway, Donald, *Introduction to Vascular Scanning*, Davies Publishing, 2017.