

Ultrasound Evaluation of Cervix During Pregnancy & Elastography

Rafael Carballido MD

OB/GYN specialist

Central University of Venezuela

Problem: Preterm delivery

- Preterm delivery is the main cause of neonatal morbidity and mortality. Incidence is 12-13% of all deliveries.
- More than 500,000 preterm births every year. Out of those 2% are under 32 weeks with very poor outcomes.
- Identifying patients threatened with preterm delivery remains one of the main obstetric challenges.

Problem: Preterm delivery

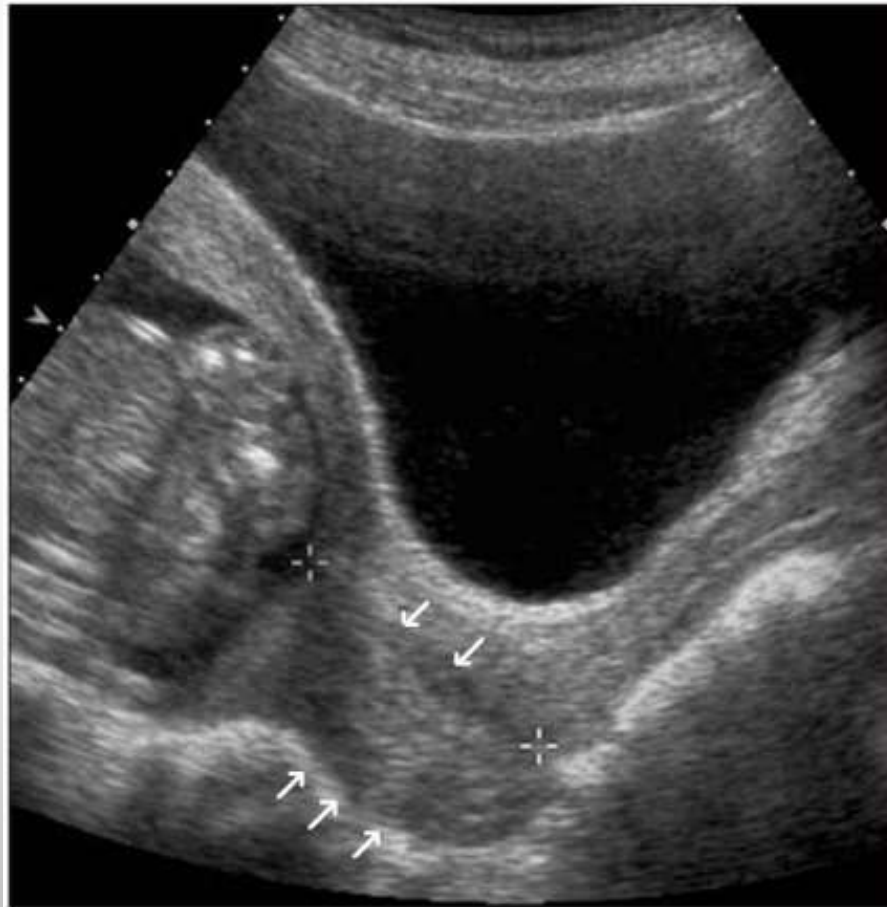- Measurement of the cervix length by transvaginal ultrasound is considered the most predictive test until this moment, it is safe, easy to perform, reproducible and accurate.
- Other techniques like elastographic assessment of the internal cervical os at 18-22 weeks of pregnancy may identify patients with high risk of preterm delivery in low-risk, asymptomatic women. *Wozniak S, Czuczwar P(1), Szkodziak P, Milart P, Wozniakowska E, Paszkowski T. BMC Pregnancy Childbirth. 2014 Jul 21;14:238*

Techniques for cervix sonography

- **Transabdominal sonography.**
 - Many shortcomings: Fetal parts interposed, filled bladder could elongate cervix or mask funneling.
 - Cervix that might be shortened or opened could be missed.
 - Clinical decision can not be taken based solely in transabdominal evaluation of the cervix.

Techniques for cervix sonography

- Transabdominal sonography.

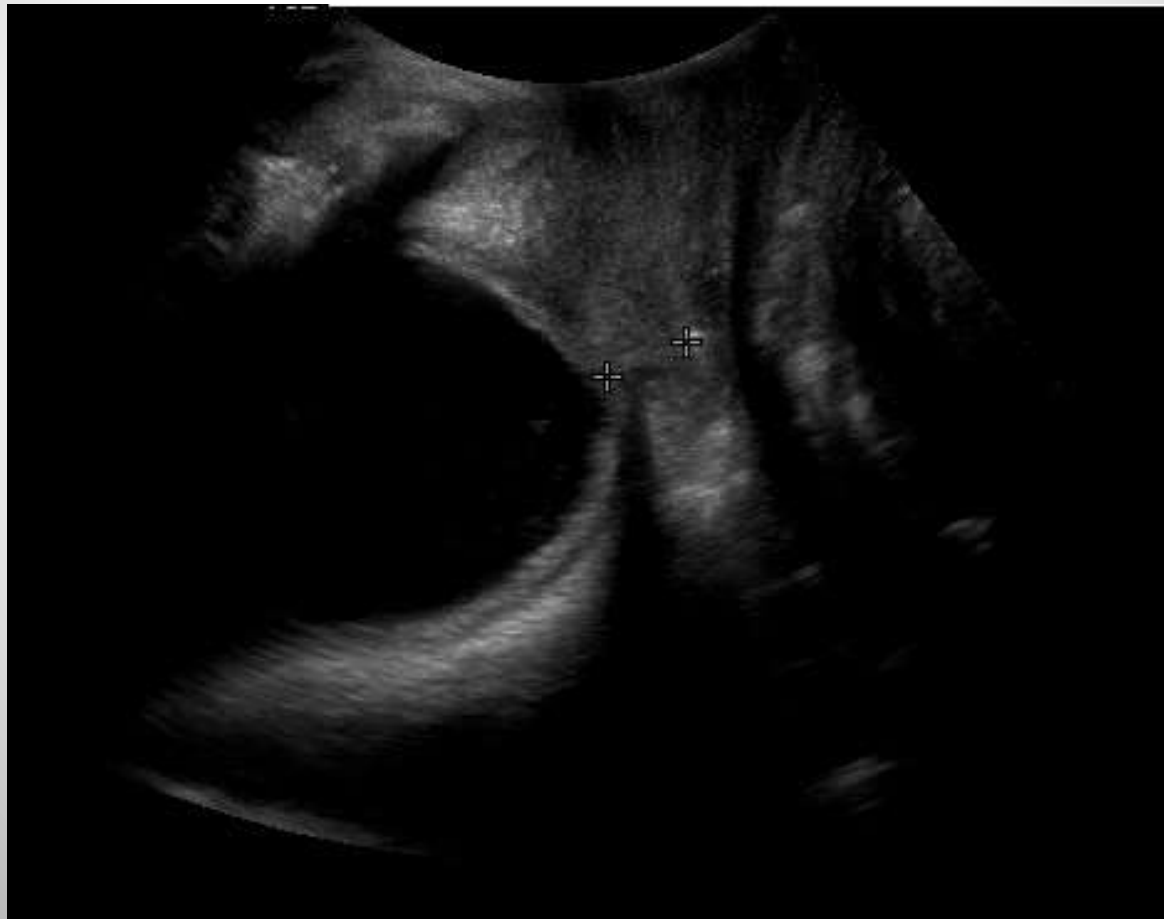

Techniques for cervix sonography

- **Transperineal sonography.**
 - Also called translabial,
 - It's uncomfortable for many patients.
 - Difficult to obtain good position of transducer.
 - External OS is difficult to observe.
 - Better visualization than transabdominal (no fetal parts interposed, no bladder filling needed, the transducer is placed close to cervix)
 - Is not superior to transvaginal technique.

Techniques for cervix sonography

- **Transperineal sonography.**

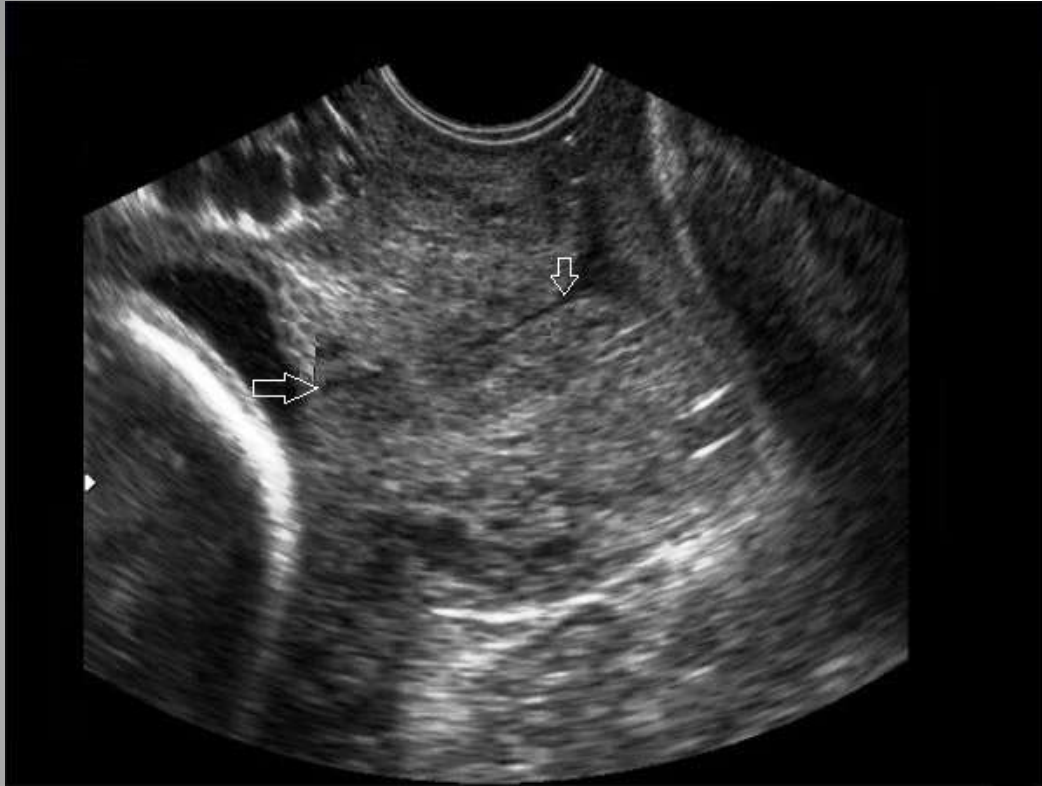

Techniques for cervix sonography

- **Transvaginal**

- It's the best technique for cervix visualization.
- Easy to learn and perform.
- More comfortable for patient than translabial.
- Direct visualization without obstructions.
- Bladder must be empty.
- Probe must be covered by condom or adequate cover
- Patient can insert the probe by herself.

Transvaginal evaluation of cervix



Technique:

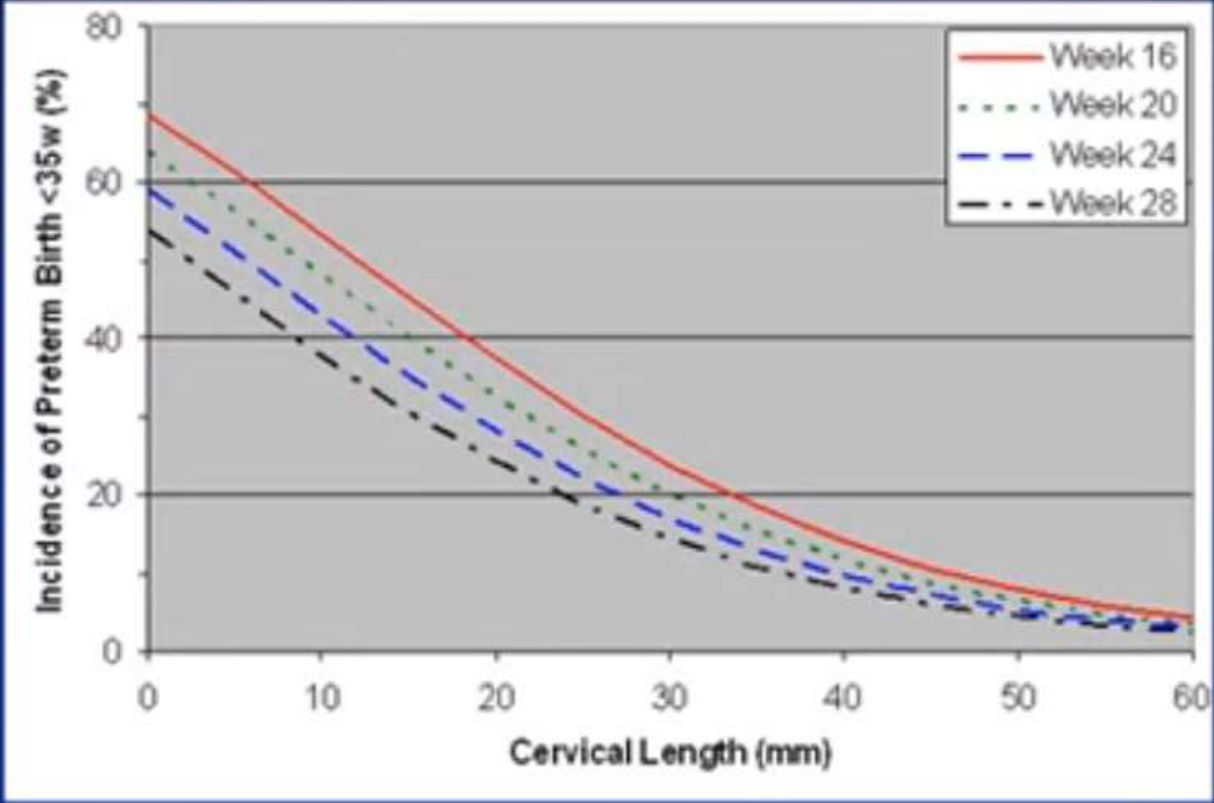
- Insert probe towards anterior fornix.
 - Then retire pressure on the anterior lip of cervix.
 - Internal OS and external OS must be clearly seen and whole endometrial canal
 - Enlarge screen to 2/3 of the screen.
-
- Anterior lip thickness should be similar to posterior lip.
 - Obtain at least 3 measurements from internal OS to external OS
 - Repeat after applying fundal pressure for 15 seconds.
 - See for changes after the pressure.

Measurement of cervix length

- Normal cervix length is 25 to 50 mm between 14 and 30 weeks.
- It is considered abnormal if less than 25 mm
- The measure should be compared to gestational age to estimate the predicted risk of preterm birth.

Measurement of cervix length

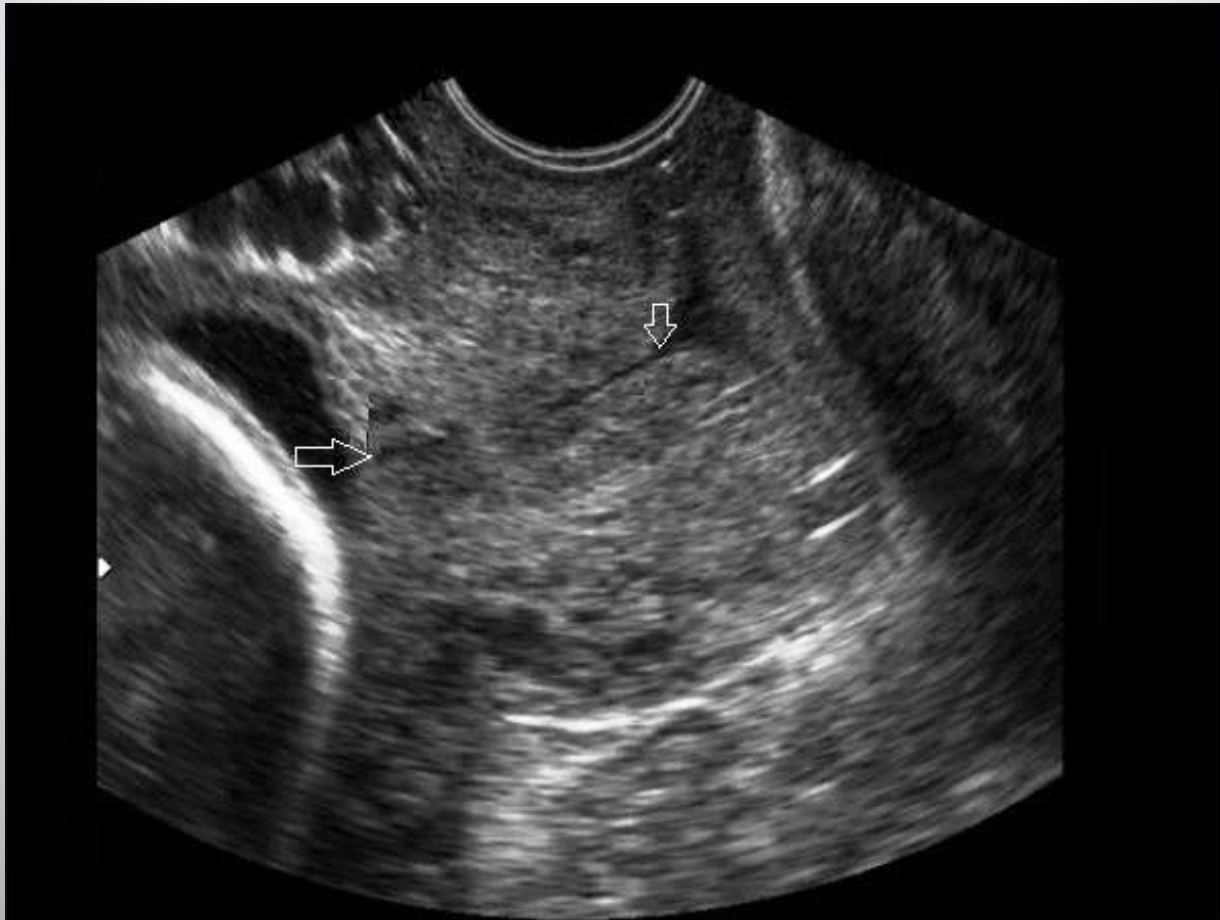Effect of GA when CL detected



Berghella, Roman, et al, OG 2007

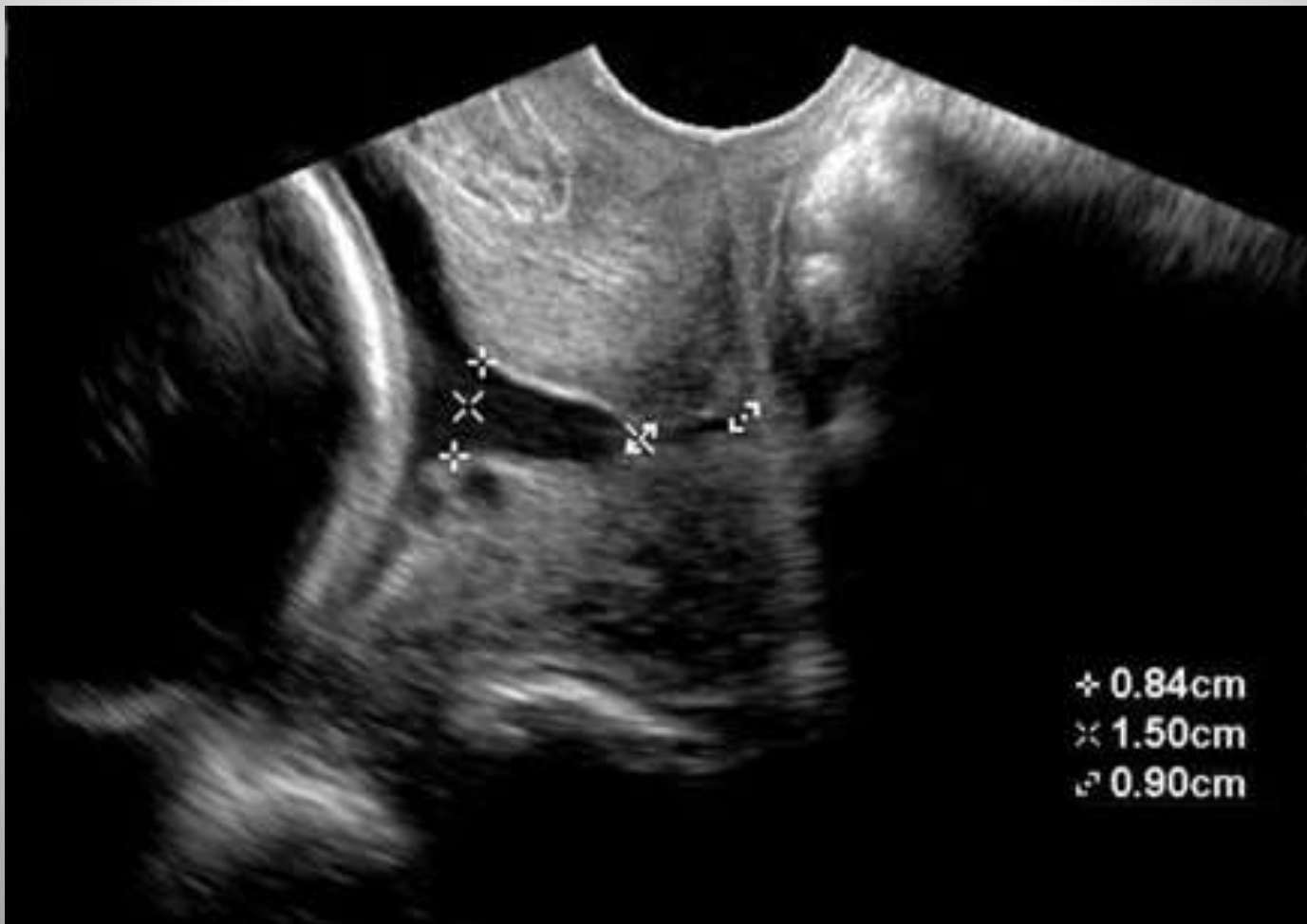
Transvaginal evaluation of cervix

- Cervical length measure:



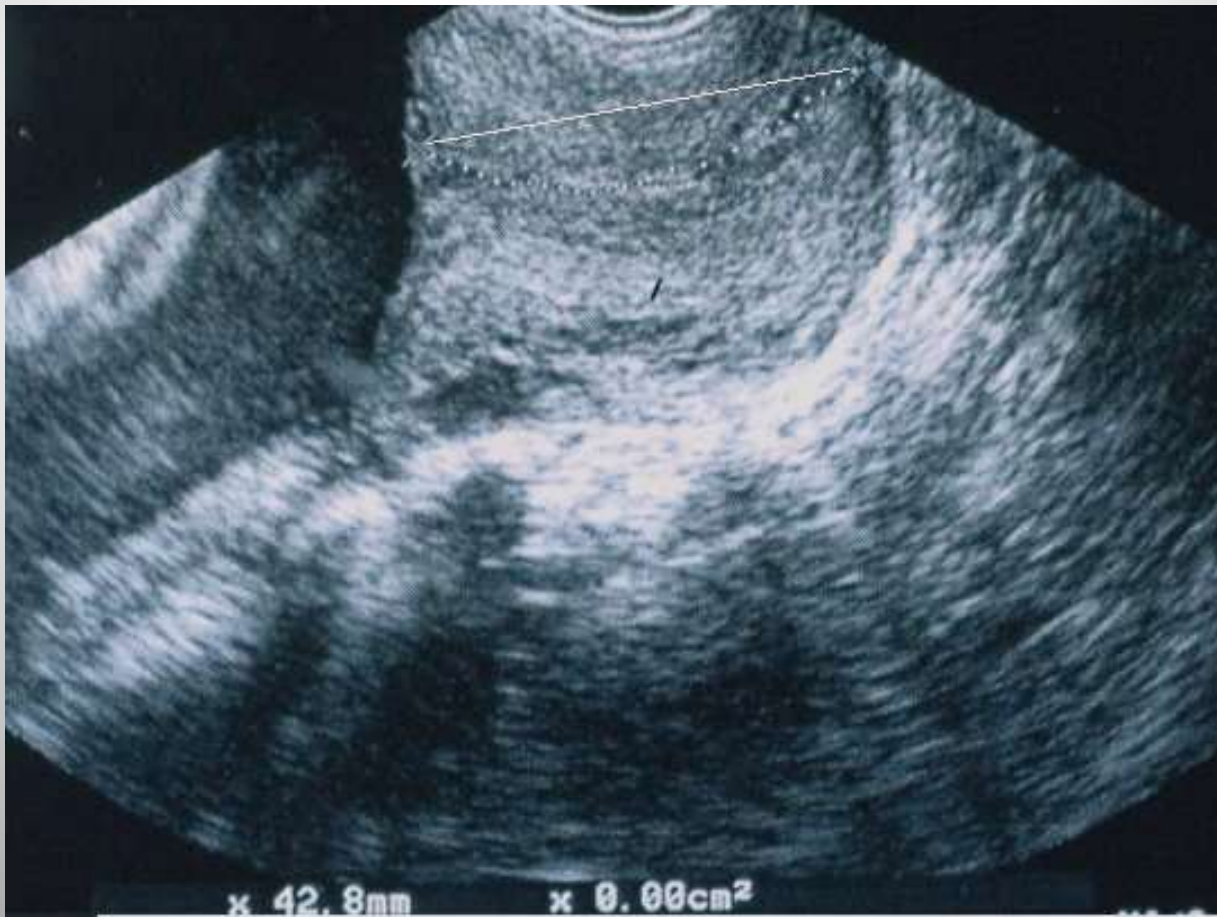Transvaginal evaluation of cervix

- Cervical length measure, correct caliper placement with funneling (effacement):



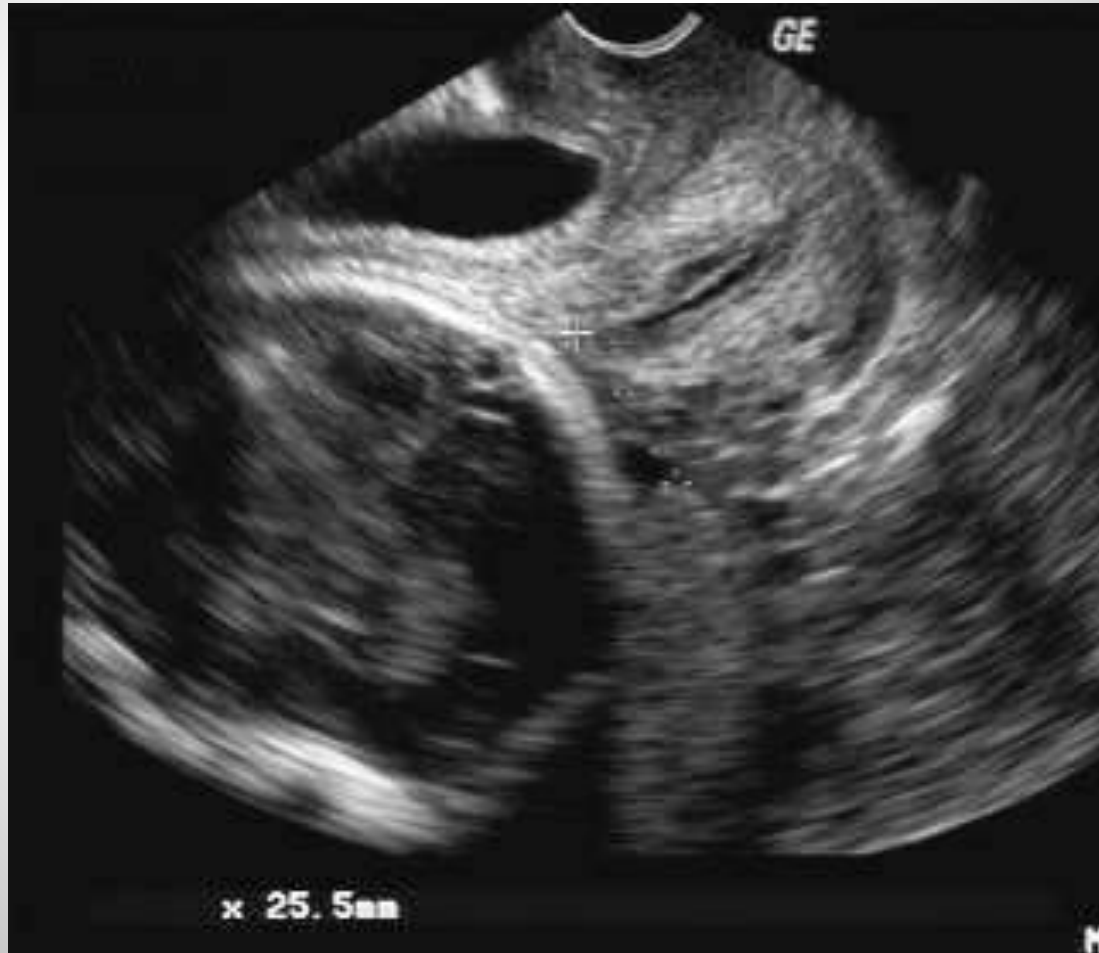Transvaginal evaluation of cervix

- Technique to measure cervical length in curved cervix (usually curved cervix are long and linear cervix are short):



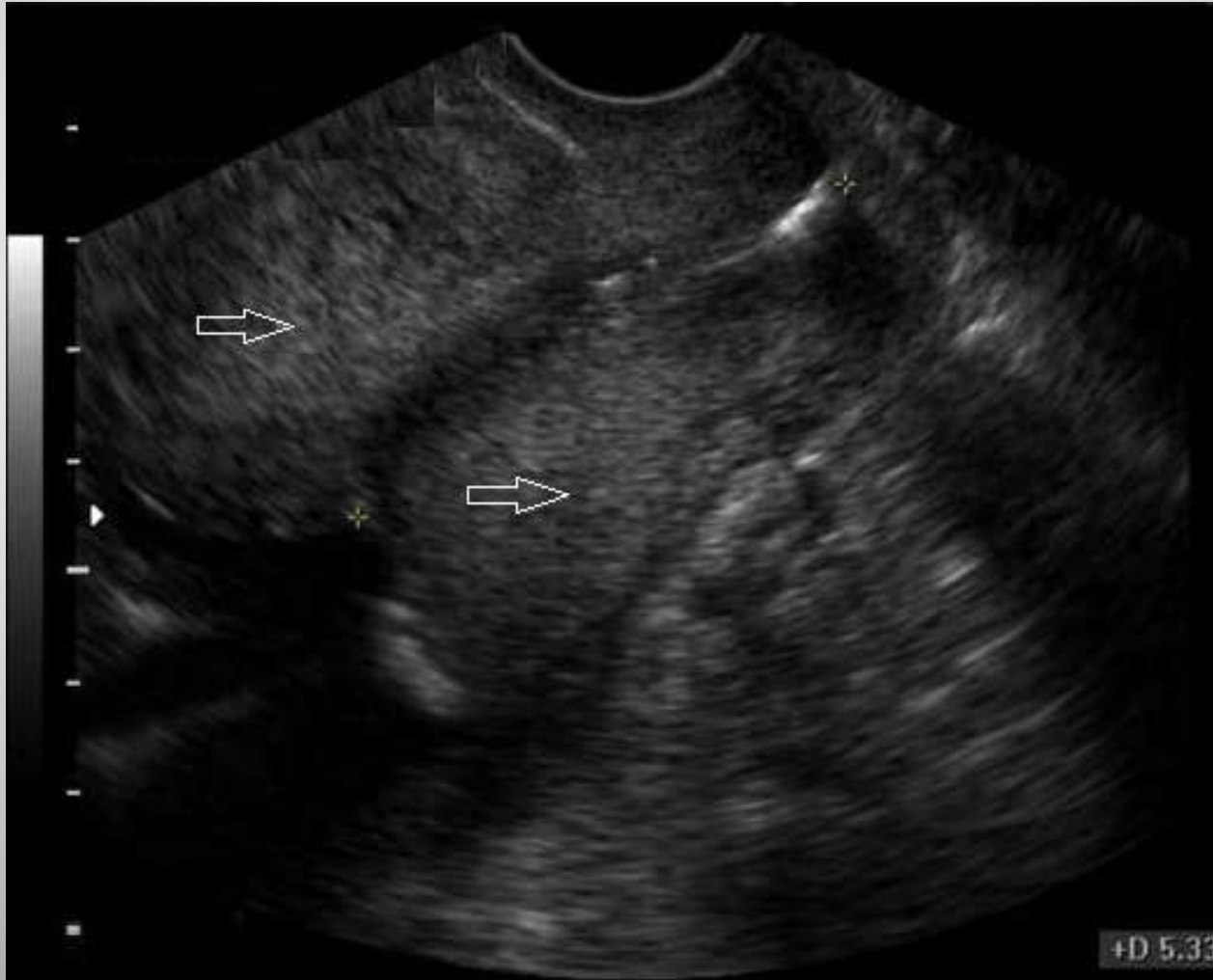Transvaginal evaluation of cervix

- Technique errors, bladder not empty:



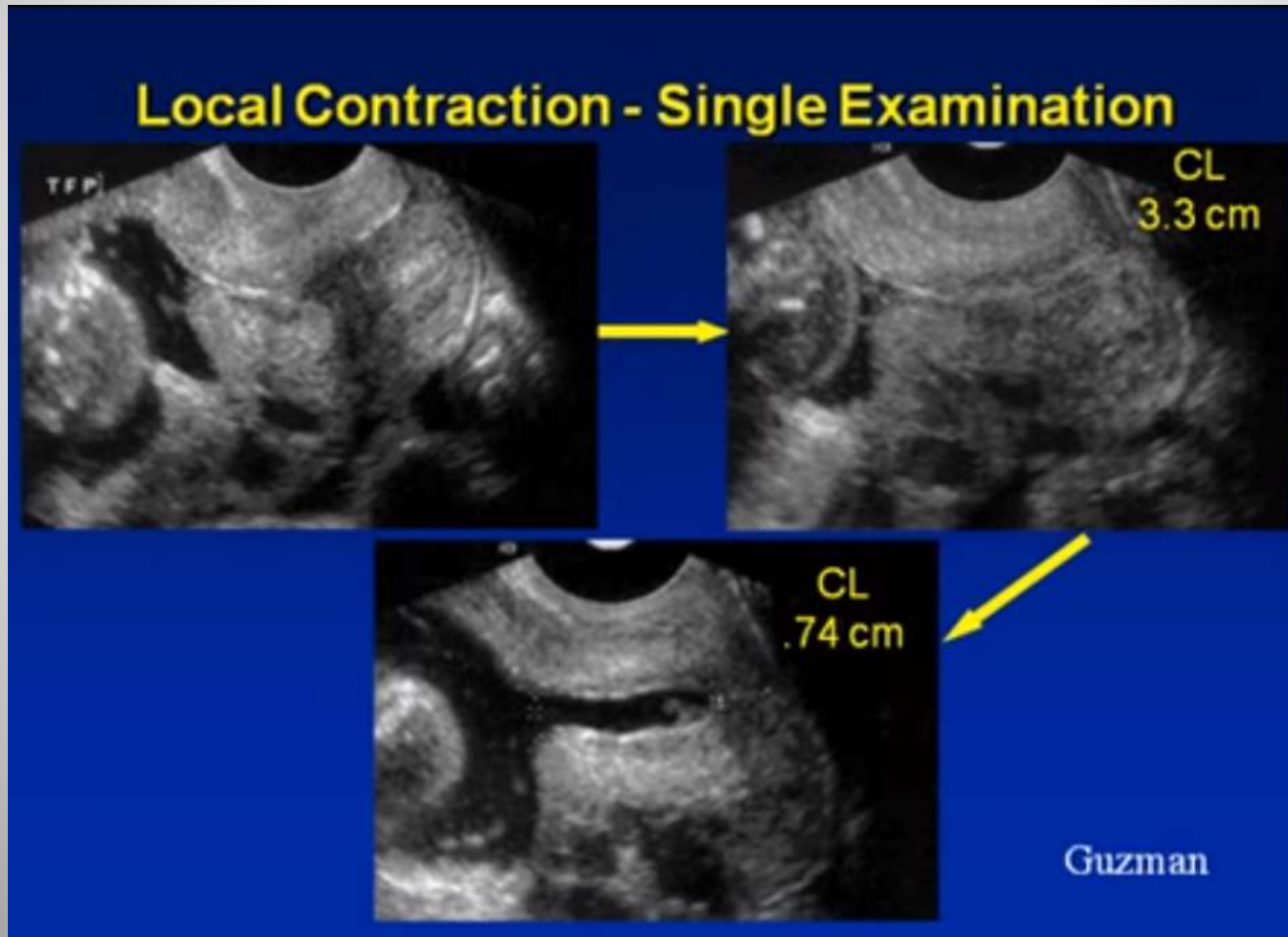
Transvaginal evaluation of cervix

- Presence of uterine contractions:



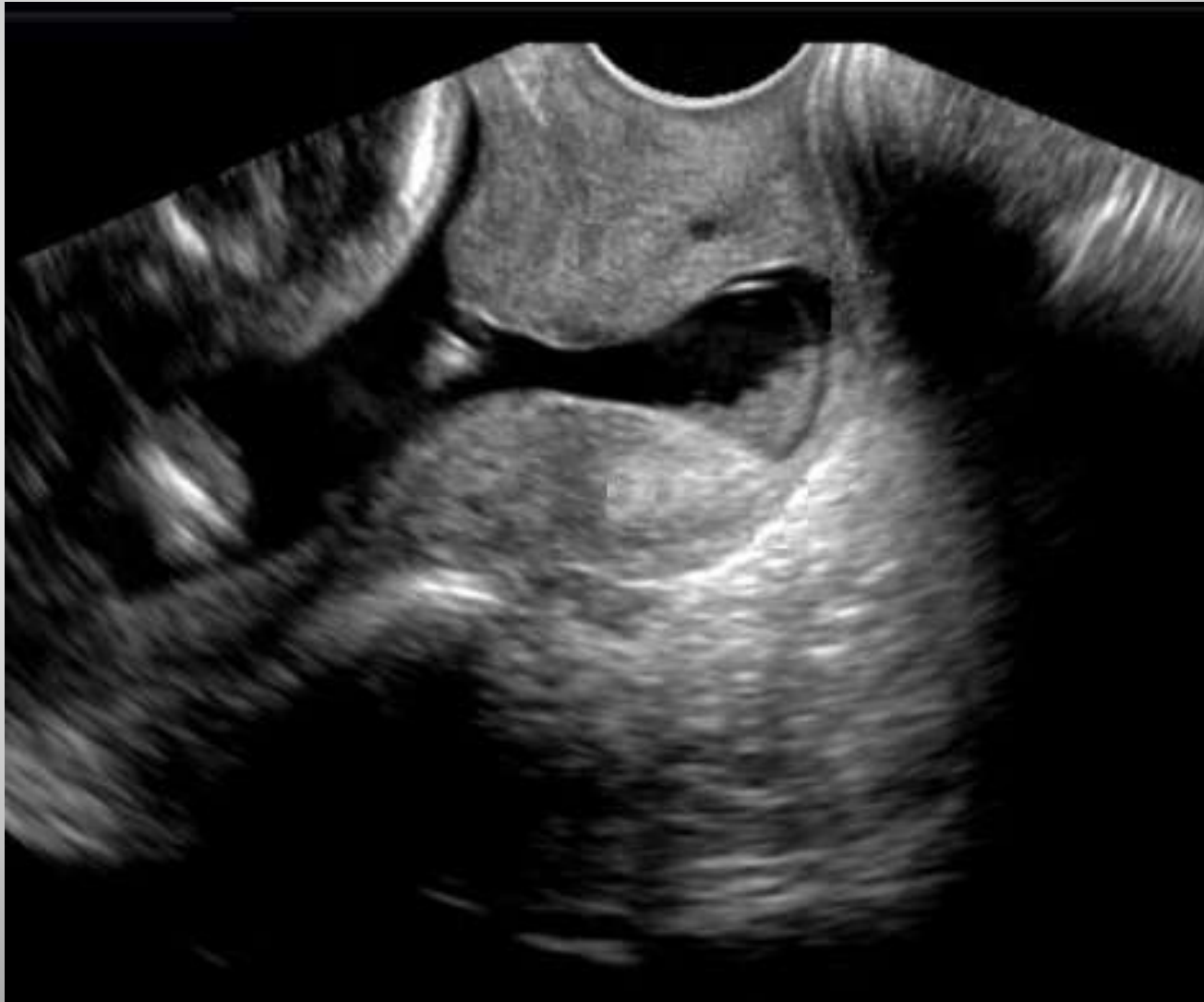Transvaginal evaluation of cervix

- Presence of uterine contractions, dynamic changes:



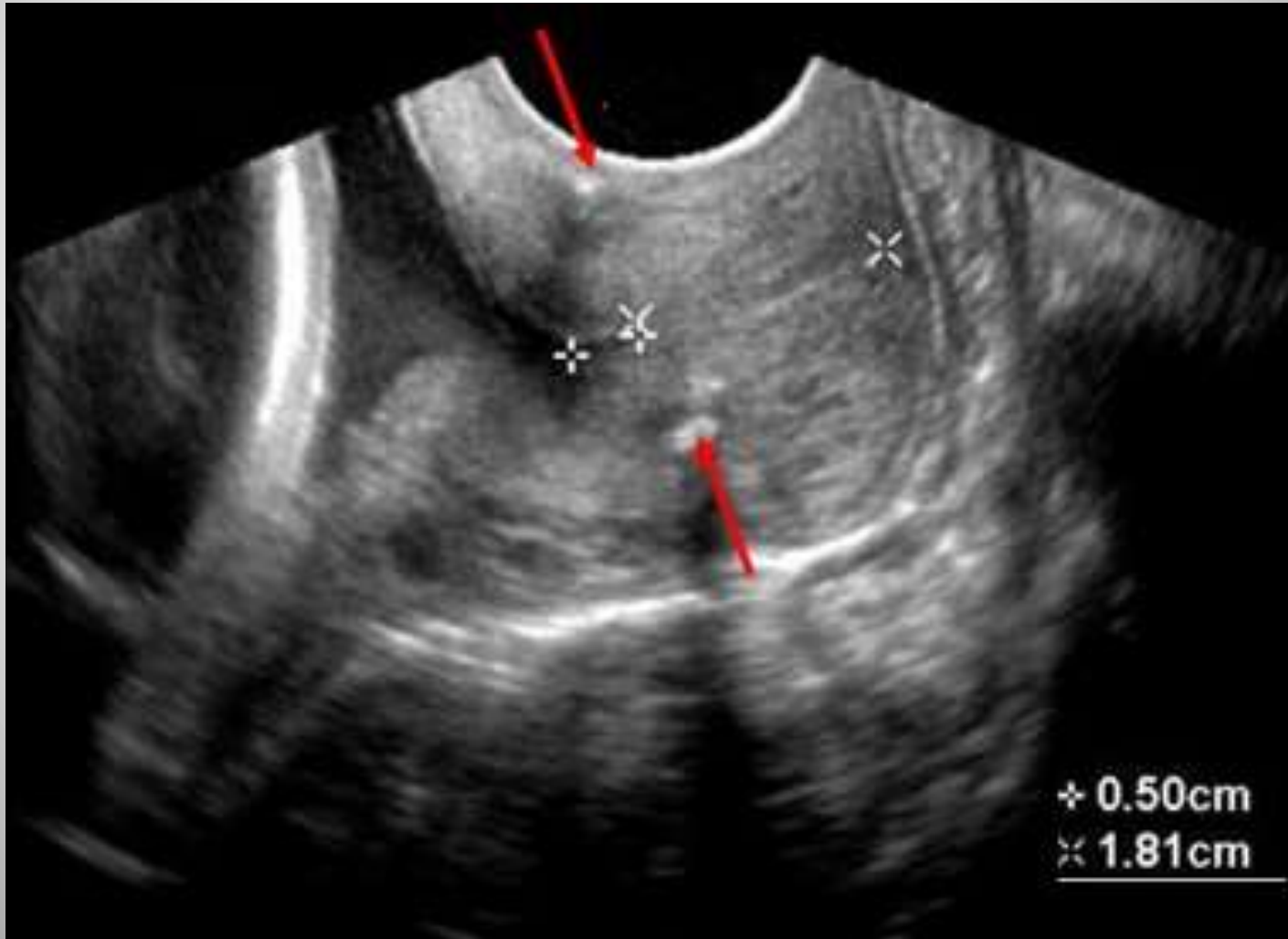
Transvaginal evaluation of cervix

- Cervical funnel extends to the external OS



Transvaginal evaluation of cervix

- Cerclage



Cervix length, conclusions

- Transvaginal ultrasound is a screening test, it is the most important test to predict preterm delivery.
- Safe, reliable and reproducible.
- Accurate in its prediction, allows onset of treatment and prevention measures.
- Can be performed any moment between 14 and 32 weeks.
- Best moment for prediction is between 18 and 22 weeks
- Inter-observer and intra-observer variability is less than 10%
- In low risk population sensitivity is 37% and positive predictive value is 18%

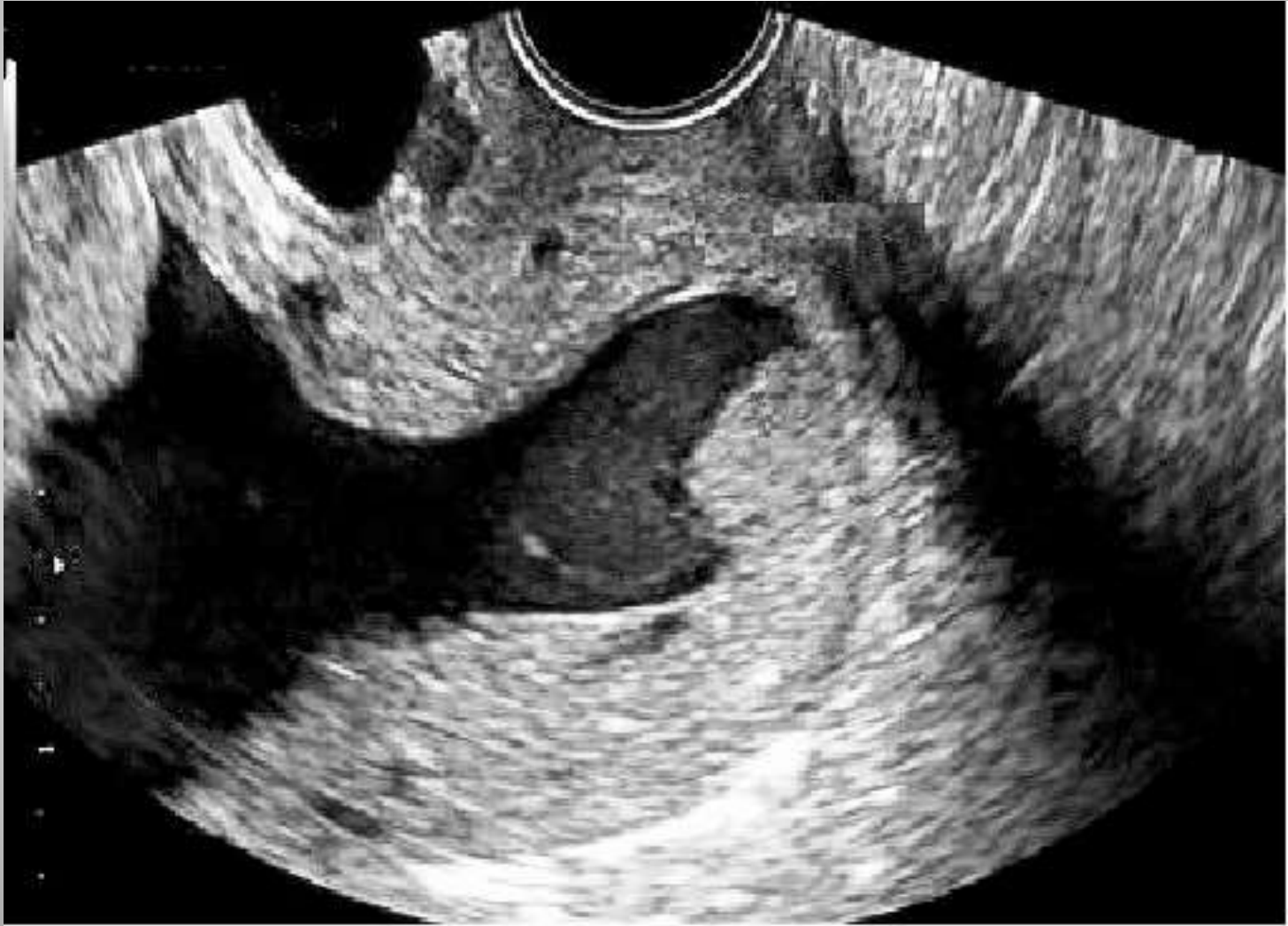Cervix length, conclusions

- Patients with increased risk:
 - Previous preterm birth. Initiate screening at 16 weeks and repeat every 2 weeks.
 - Patients with previous cervix surgery: conization.
 - Multiple gestation
 - Symptomatic patients.
 - In high risk population sensitivity is 69% and PPV is 55%

Amniotic fluid Sludge

- Presence of free-floating hyperechogenic material within the amniotic fluid in close proximity to the uterine cervix
- Amniotic fluid 'sludge' has been identified in asymptomatic women at risk for spontaneous preterm delivery in the mid-trimester of pregnancy and is also an independent risk factor for preterm prelabor rupture of membranes (PROM) and spontaneous preterm delivery

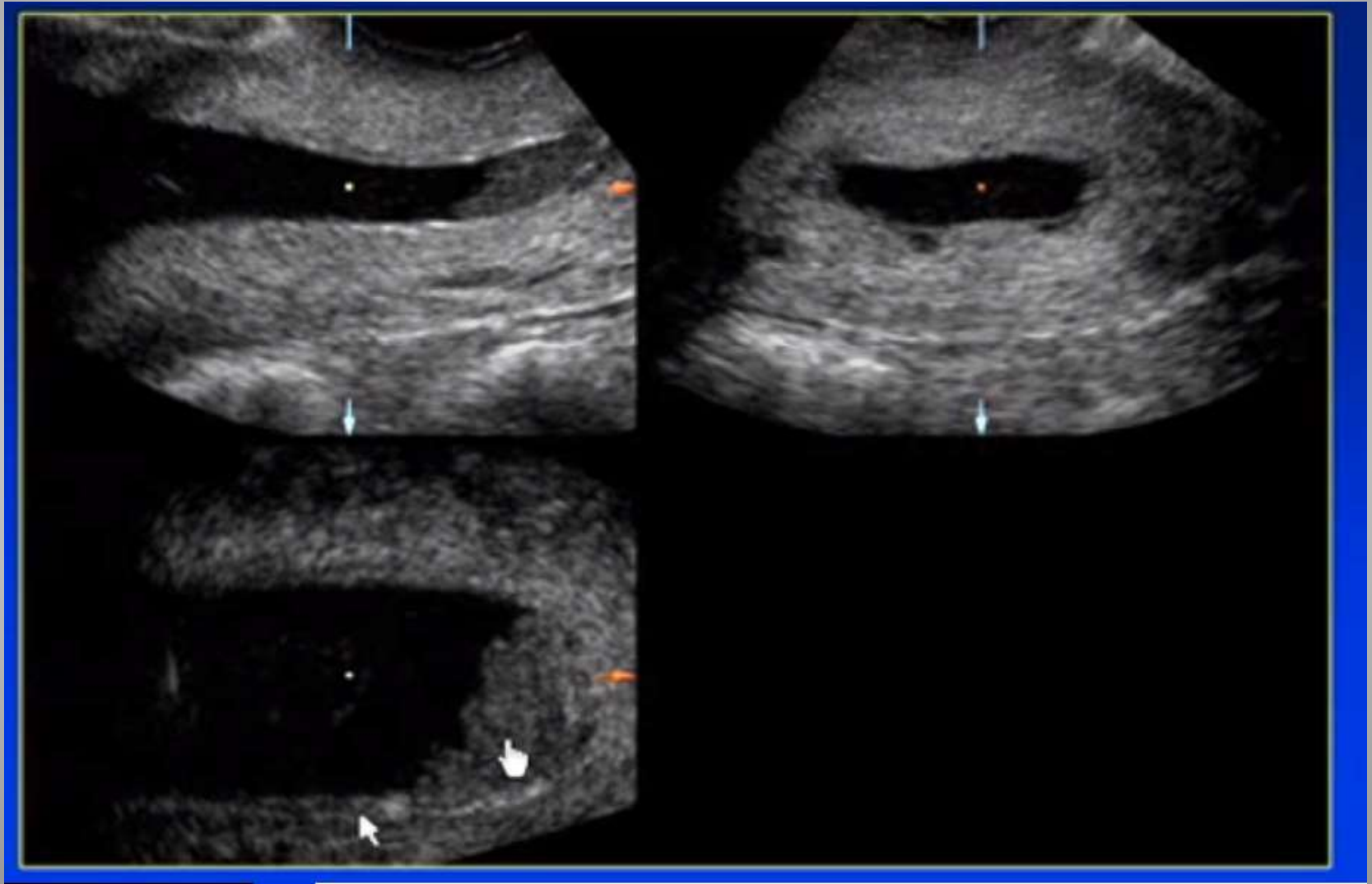
Amniotic fluid Sludge



Amniotic fluid Sludge

- The presence of AF sludge in pregnancies with a short cervix is a risk factor for extreme prematurity (delivery prior to 26 weeks), histological chorioamnionitis, and perinatal death. *Boyer A, Cameron L, Munoz-Maldonado Y, et al. Clinical significance of amniotic fluid sludge in twin pregnancies with a short cervical length. Am J Obstet Gynecol 2014;211:506.e1-9.*

Amniotic fluid Sludge



ELASTOGRAPHY

ELASTOGRAPHY

- **Elastography** is a promising method to assess tissue differences in stiffness or elasticity what was historically assessed manually by palpation.
- **Elastography** helps to detect the malignant tumors from the benign ones on the basis of the principle that most **malignant lesions have a harder or stiffer consistency than surrounding benign tissue.**

ELASTOGRAPHY

Ultrasound elastography is a non-invasive diagnostic technique performed in combination with conventional B-mode ultrasound to help assess tissue stiffness. Strain elastography can help clinicians characterize abnormal tissue by assessing the stiffness in relationship to surrounding tissue.

The use of ultrasound elastography is based in the widely accepted principle that most malignant lesions have a harder or stiffer consistency than surrounding benign tissue.

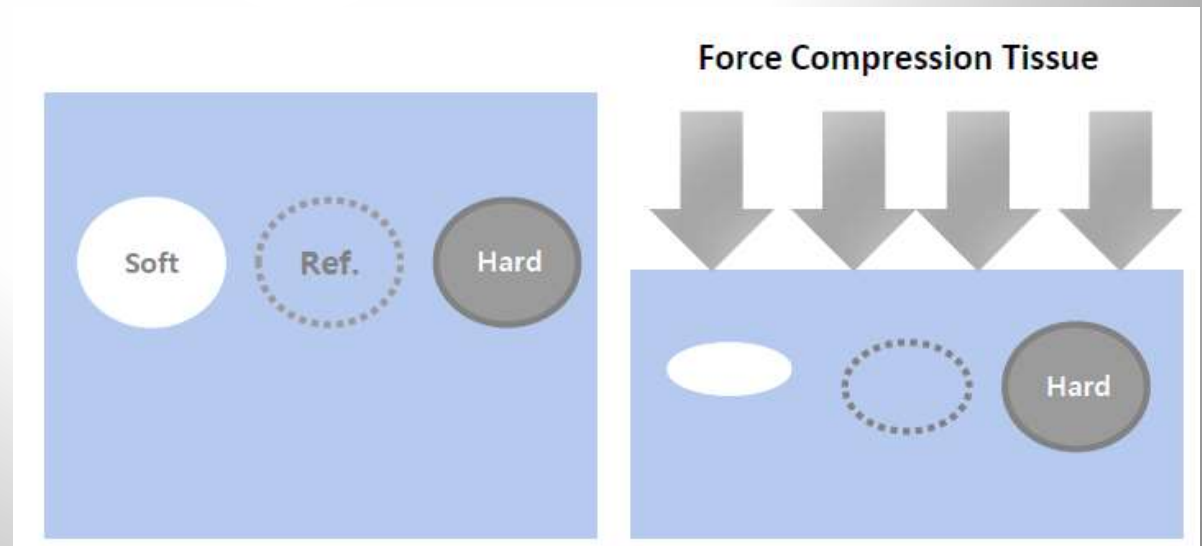
ELASTOGRAPHY

- Elastography is an ultrasound-based newer imaging technique that is currently being used for the evaluation of breast lesions and hepatic pathology. It is also being evaluated for characterizing lesions of the prostate, thyroid, cervix and lymph nodes. *Korean J Radiol. 2011 Sep-Oct;12(5):646*

ELASTOGRAPHY

Basic Principle:

- Apply a small stress to the Tissue
- Measure the tissue displacement
- Calculate stiffness based on the tissue displacement



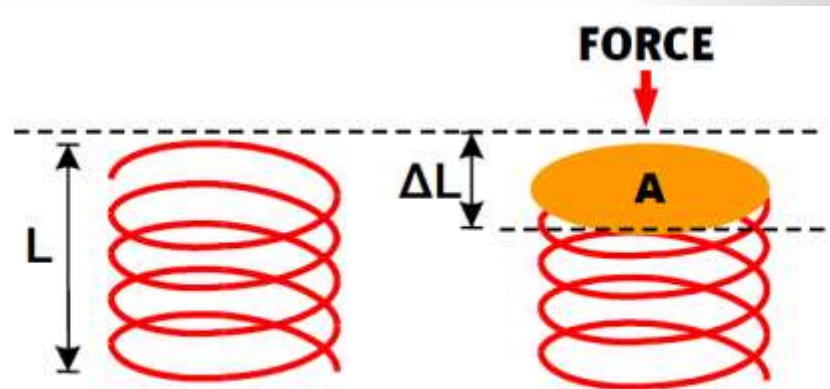
ELASTOGRAPHY

Elasticity is the ratio of the strain and the stress.

Elasticity = Stress / Strain

Stress = F / A (F: force, A: forced area)

Strain = $\Delta L / L$



©Copyright Prof. Jonathan Ophir, University of Texas

Elastography techniques

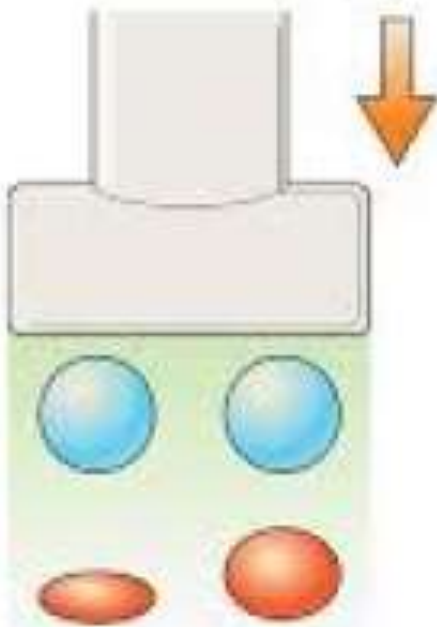Technique of US elastography

1. Manual compression by operator using transducer (Strain Elastography)
2. Organ compression by heartbeat or vascular pulsations
3. Acoustic Radiation Force (push pulse waves compression)
4. Shear waves

Three step approach:

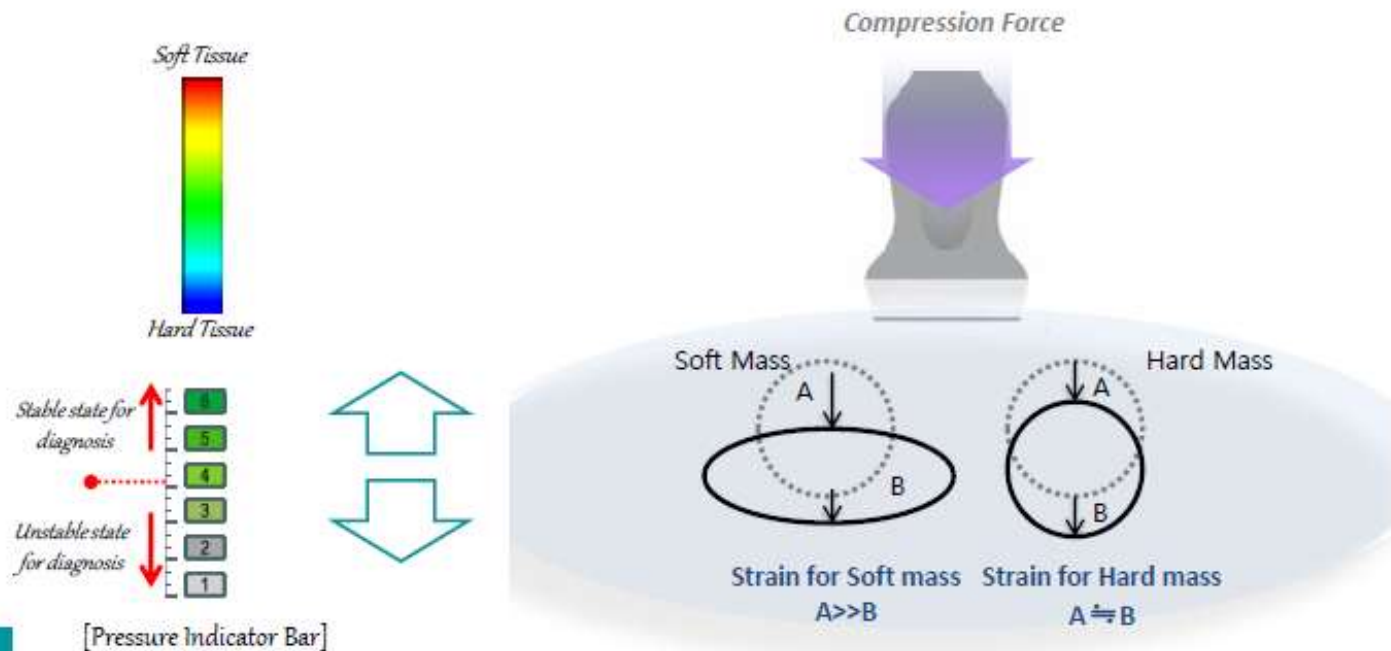
1. Organs mechanically stressed by either external or internal forces
2. Measurements of tissue movement induced
3. Qualitative or quantitative evaluation of tissue elastic properties from the measured displacement of tissues

Strain Elastography



Strain elastography evaluates elasticity through tissue displacement caused by compression, with the degree of displacement being larger in soft tissue than in hard tissue

Strain Elastography



Key Benefits

High Sensitivity



Provides real-time elasticity images through improved tissue motion tracking and data acquisition technique

High Accuracy



Displays extracting strain data through measurements from the Strain Ratio tool and a pressure quality indicator

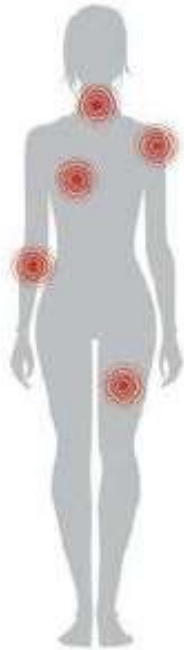
High Intuitiveness



Helps streamlined workflow by performing fast, accurate and reproducible results with intuitive S/W

Strain Elastography

Clinical Benefits on Various applications



Breast

Reduce the number of unnecessary biopsies

Thyroid

Reduce the number of FNA biopsies (63.3%) by detecting benign nodules and managing them via follow-up observations rather than an FNA biopsy.

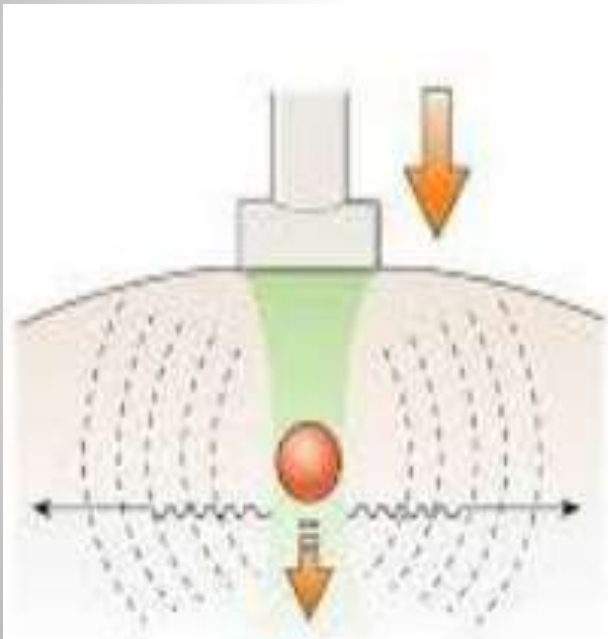
MSK

Used as an additional tool in diagnosing Achilles tendiopathy and to depict stiffness changes in congenital muscle spasticity

Uterine Cervix

Strain measurement of cervical stiffness is correlated with the predictability of preterm delivery.

Shear Wave Elastography

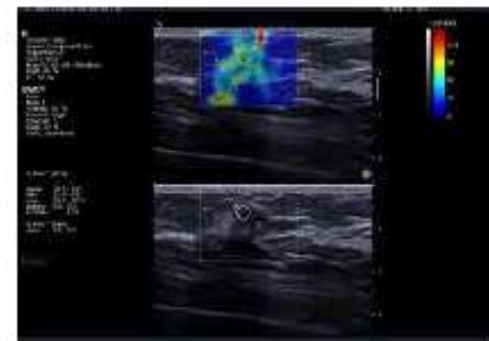
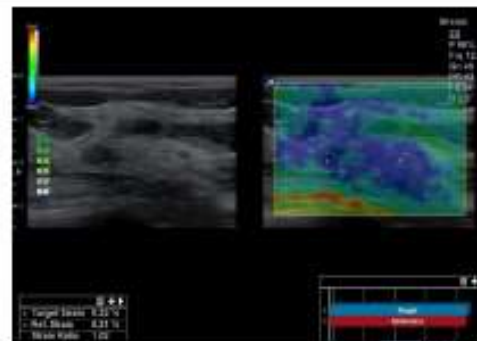


Shear wave elastography evaluates elasticity through the propagation speed of transverse-oriented shear waves, with the wave speed being faster in hard tissue than in soft tissue.

Strain Elastography vs. Shear-wave Elastography(SWE)

<i>Property</i>	<i>Strain Elastography</i>	<i>Shear-wave Elastography</i>
<i>Imaging at Depth</i>	++++	+
<i>Effects of Precompression</i>	+++	+++
<i>Sensitivity (Is it a cancer?)</i>	++++	++
<i>Specificity (Is it benign?)</i>	++	++++
<i>Quantitative</i>	+	++++
<i>Cyst Characterization</i>	++++	++
<i>Price</i>	<i>Less Expensive</i>	<i>Expensive</i>

Image



Shear wave elastography: LIVER

- Spleen stiffness measurement (SSM) using transient elastography (TE) has widely been demonstrated to predict liver disease severity and progression of chronic liver disease
- Transient Elastography (TE) is the reference method and has been validated for liver fibrosis evaluation.

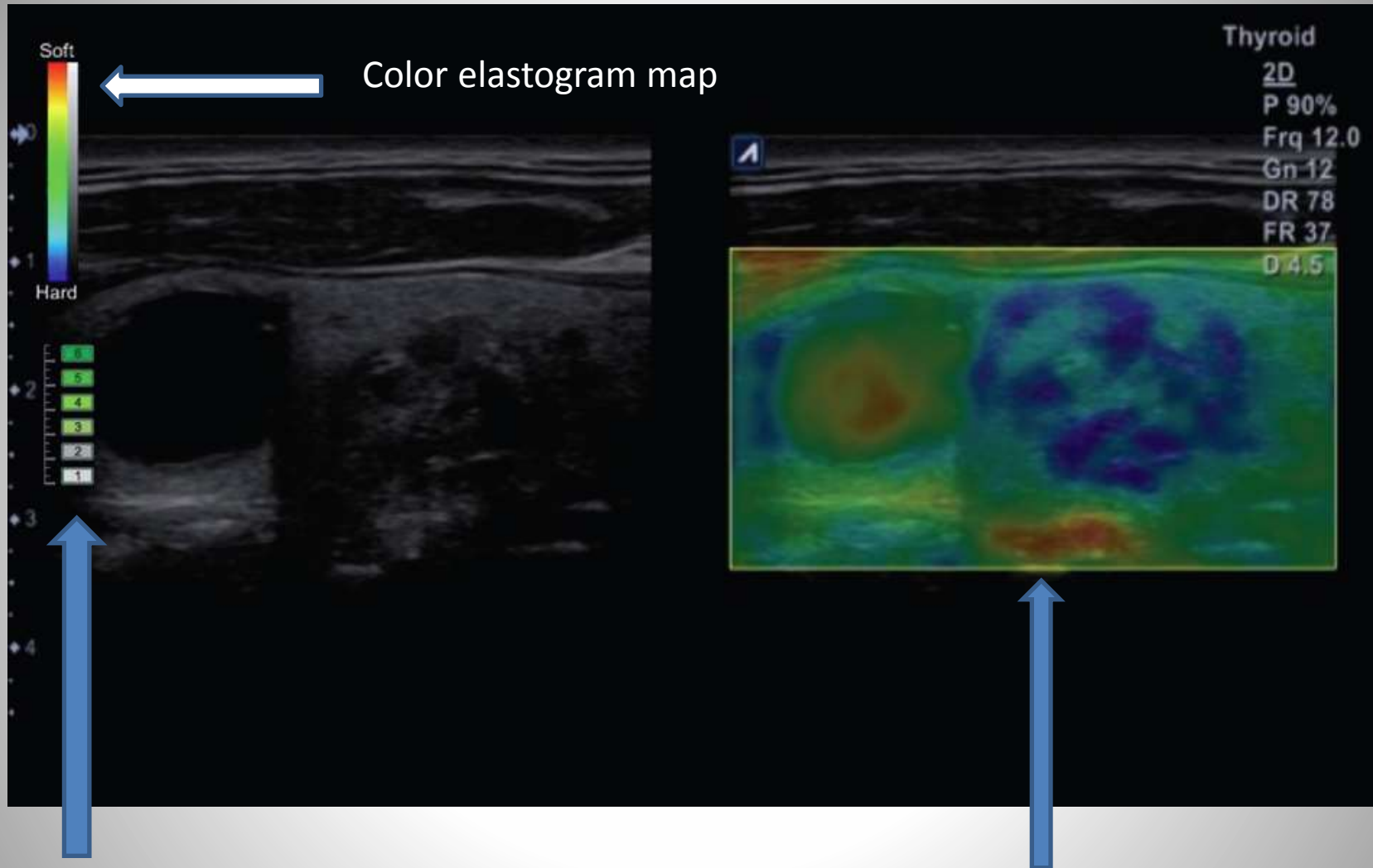
Shear wave elastography: LIVER

- Point Shear Wave Elastography-PSWE:
 - TE (FibroScan, Echosens)
 - VTIQ (Siemens Acuson S2000™)
 - ElastPq (Philips Affinity)
- 2D-SWE (Aixplorer™ SuperSonic Imagine S.A)
- Considering TE as the reference method for liver fibrosis evaluation, VTIQ, ElastPQ and 2D-SWE had similar accuracies for diagnosing at least significant fibrosis ($F \geq 2$) and liver cirrhosis.
- PSWE-ElastPQ is feasible in more patients than TE.
- ElastPQ is a highly reproducible method for assessing liver fibrosis with excellent intra and interobserver agreement.

Strain elastography: make it simpler

- Enhanced ultrasound elastography technique adopts simple compression, displacing the underlying anatomical structures. Proprietary software estimates the strain on tissue in a region of interest and creates an elastogram, displayed as a real-time color map of relative elasticity, superimposed on the B-mode, providing useful clinical information and improved diagnostic confidence.

Strain elastography: make it simpler



Pressure indicator bar:
Provides real time
feedback on
precompression

Dual Mode: Side by side
views of B mode and
elastogram

Strain elastography: make it simpler

- **Highly Sensitive:** Real-time elasticity imaging through improved tissue motion tracking and data acquisition techniques.
- **Highly Accurate:** Displays extracting strain data using measurements via a Strain Ratio tool and a pressure quality indicator.
- **Highly Intuitive:** Helps streamline workflow by performing fast, accurate, reproducible results with intuitive user-interface

Elastography: Breast

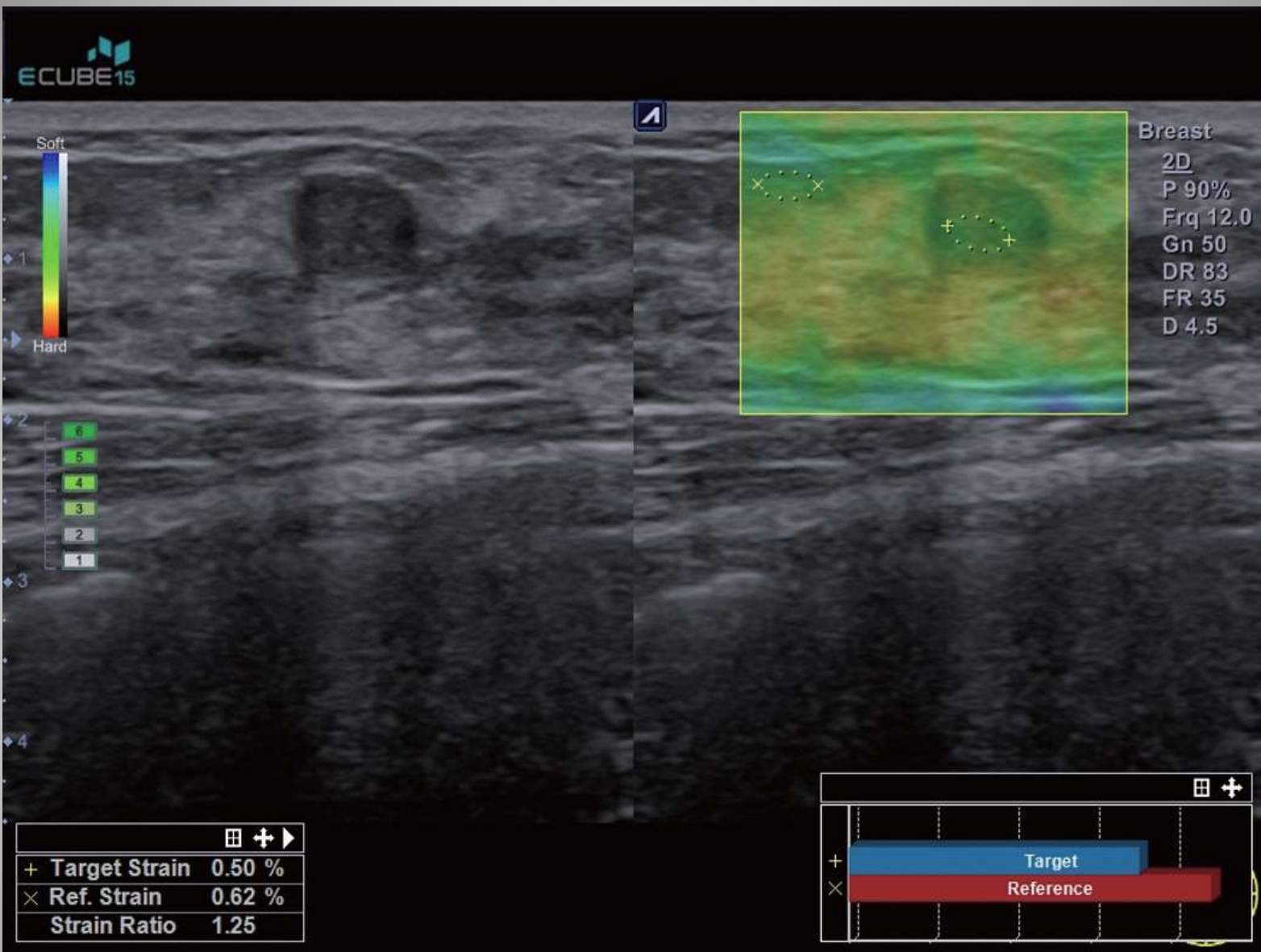
- In recent years, the interpretation of breast nodules detected via ultrasound has depended mainly on morphological criteria. To improve the accuracy of US, additional techniques can be used, including Doppler and harmonic imaging.
- The lesion's contours, dimensions, color, strain ratio, and appearance in elastography are some of the criteria used for differentiating benign from malignant lesions.

Elastography: Breast

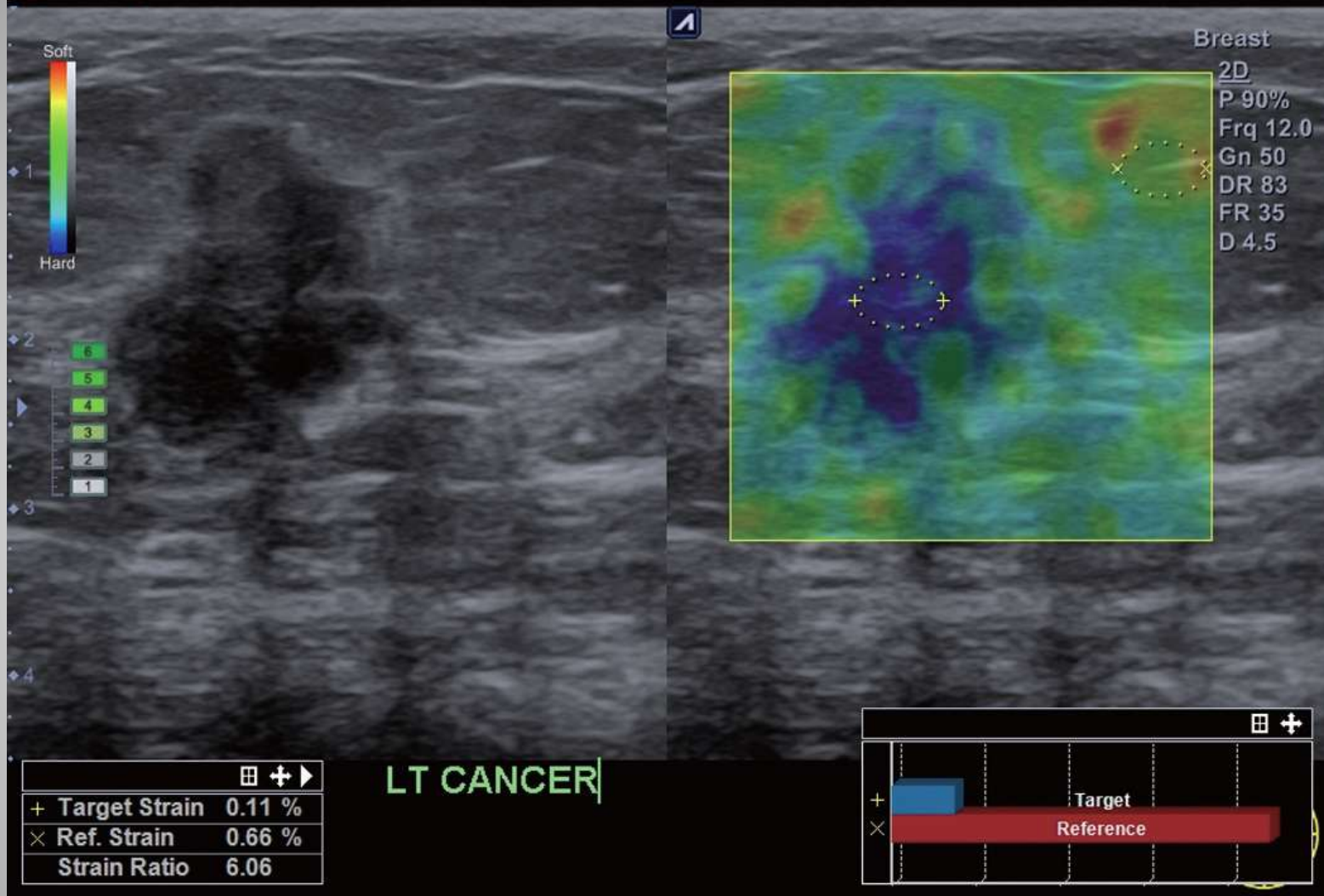
- The strain ratio shows the relative stiffness of lesions compared to surrounding tissue. Malignant lesions are usually very stiff, with less deformation, and are displayed in blue on the elastography images, whereas benign lesions deform much more easily and are depicted in red.
- 171 breast lesions were evaluated by B-mode and elastography imaging using Alpinion E-CUBE 15 EX in a tertiary medical center, South Korea from July to December, 2015.

Elastography: Breast

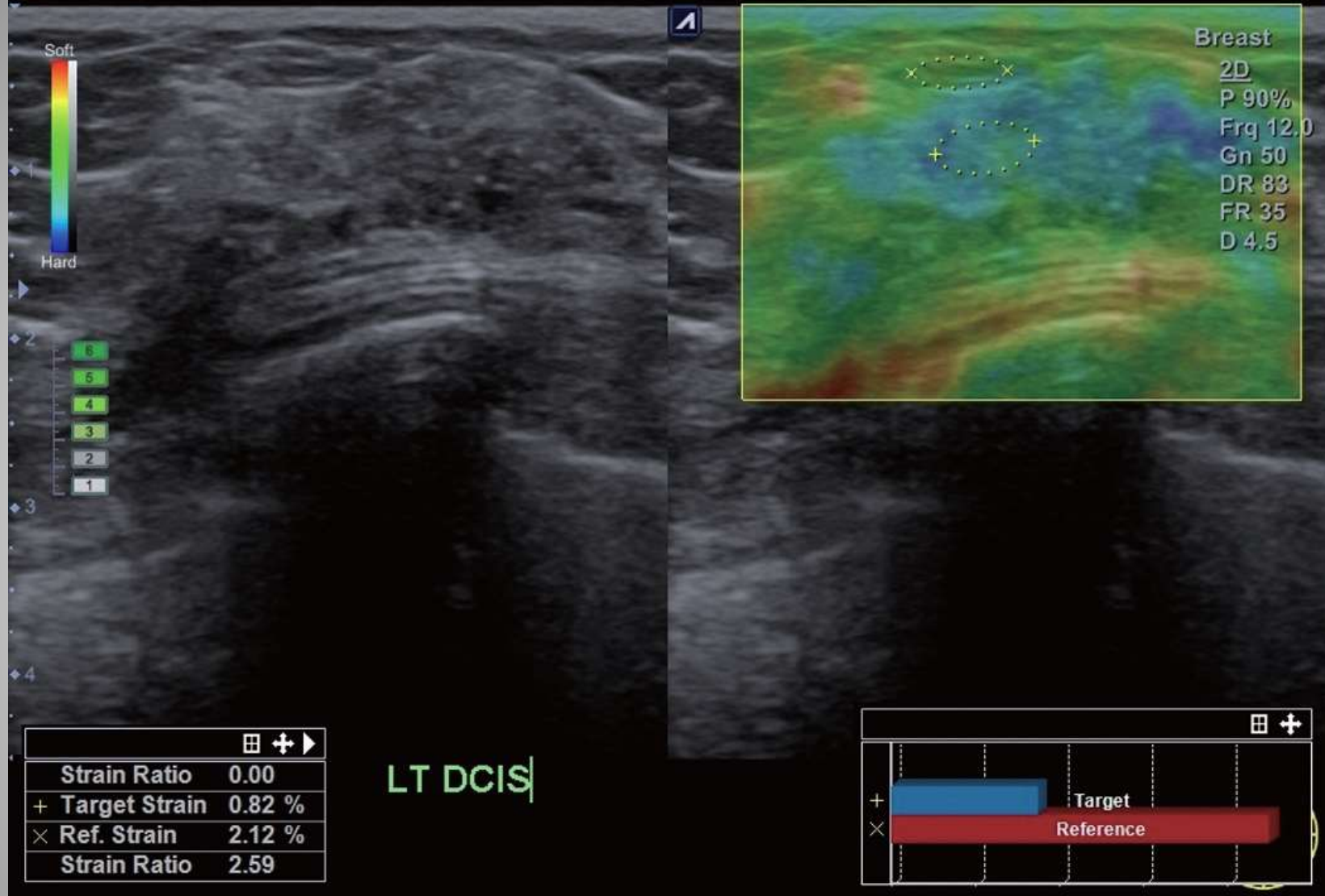
- Strain ratio helps the clinician distinguish BI-RAD III-IV lesions with direct visual information. Elastography shows the relative softness, which can prevent unnecessary biopsies.
- In the near future, elastograms might be added to all ultrasound devices and be included in diagnostic criteria.



The lesion measured 0.9 cm in size, with an oval shaped and smooth margins, classified BI-RAD III. An elastogram revealed the stiffness of the lesion, indicated by yellow-blue, in contrast to the fat tissue, indicated by yellow-red. The strain ratio was 1.25. Biopsy result was fibroadenoma.



The lesion was 1.67cm in size, irregularly shaped, hypoechoic with indistinct margins, classified BI-RAD IV c. Elastogram revealed stiffness, indicated in blue, while the fat tissue was red. The strain ratio was 6.06. Biopsy result was invasive ductal carcinoma.



The lesion was 2.56cm, a hypoechoic mass with internal calcification, irregularly shaped indistinct margins and posterior acoustic shadow, classified BI-RAD IV b. Elastogram revealed stiffness, indicated by blue, contrasted with yellow fat tissue and a Strain ratio of 2.59. Biopsy result was ductal carcinoma in situ.

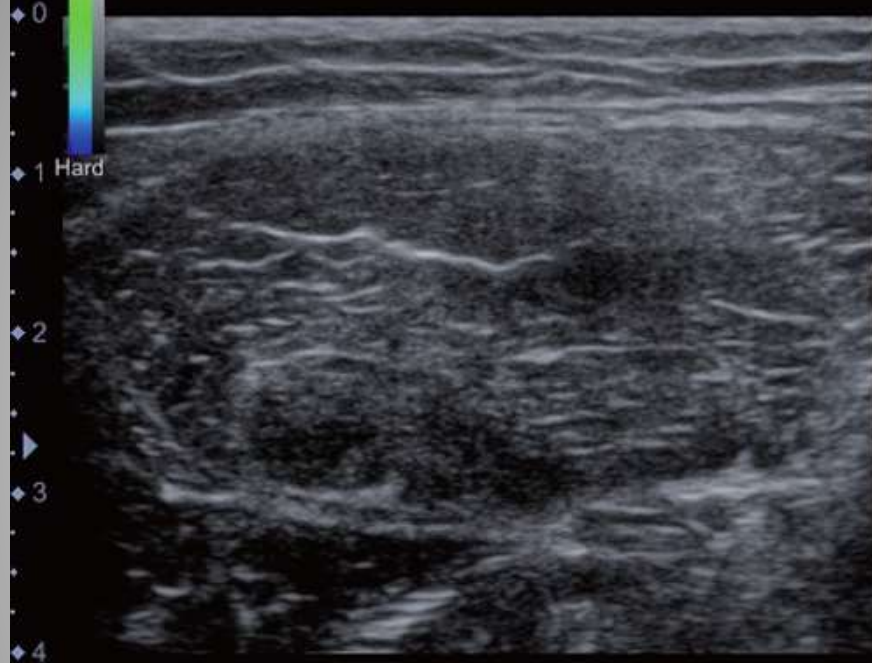
Elastography: MSK –Sports Medicine

- Ultrasound (US) sonography has been well-known for its usefulness in assessing musculoskeletal pathology, and recent studies have revealed that the combination of US elastography may be a useful tool for the evaluation of musculoskeletal disorders and even for monitoring the effect of rehabilitation therapy.
- Case studies are being conducted to evaluate the clinical usefulness of US elastography in the diagnosis and treatment of athletes with rectus femoris or other muscle tears.

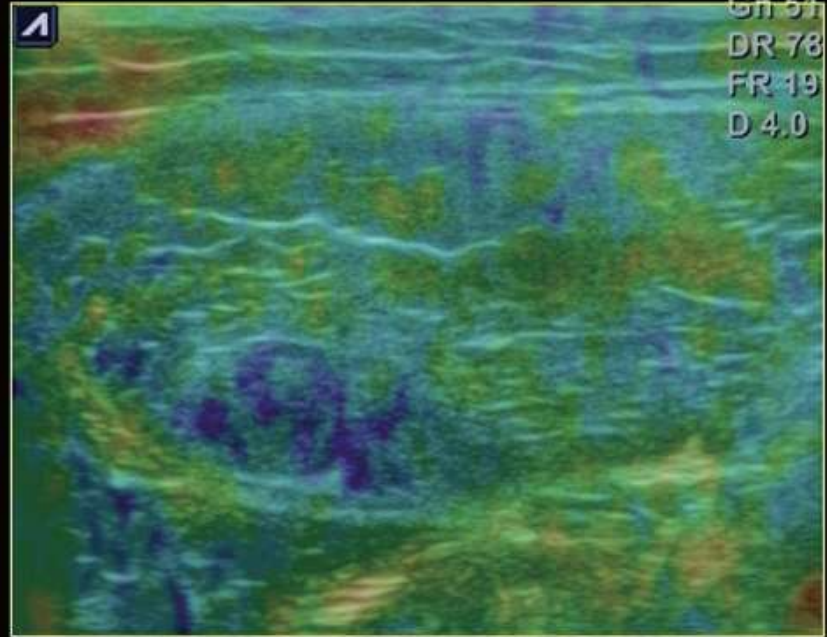
Soft



Hard



MSK
 2D
 P 90%
 Frq 12.0
 Gn 54
 DR 78
 FR 19
 D 4.0



- Initial Visit - Short axis view: Partial rupture in rectus femoris is more clearly identified with elastography mode than 2D mode, with the SR values of 3.2-3.64 measured from the site. Blue color mapping: Hard lesion

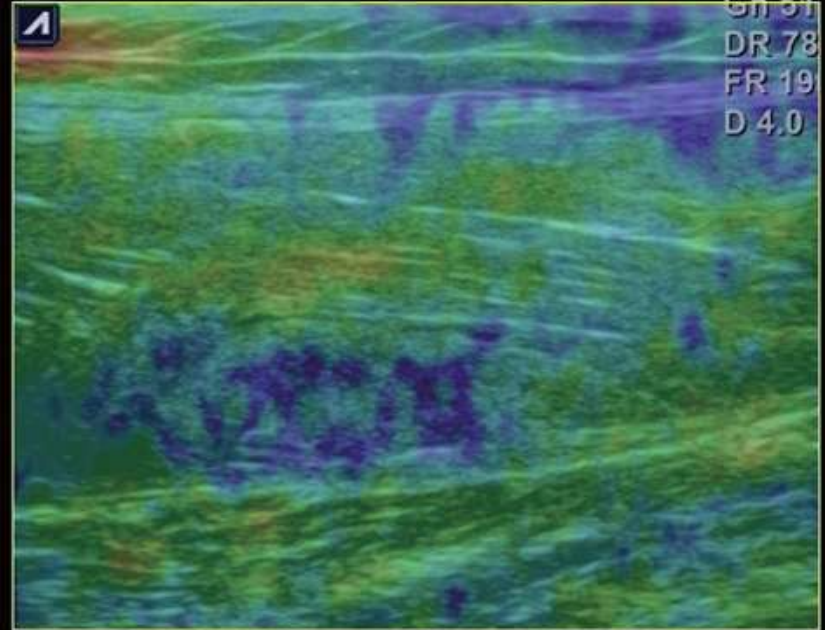
Soft



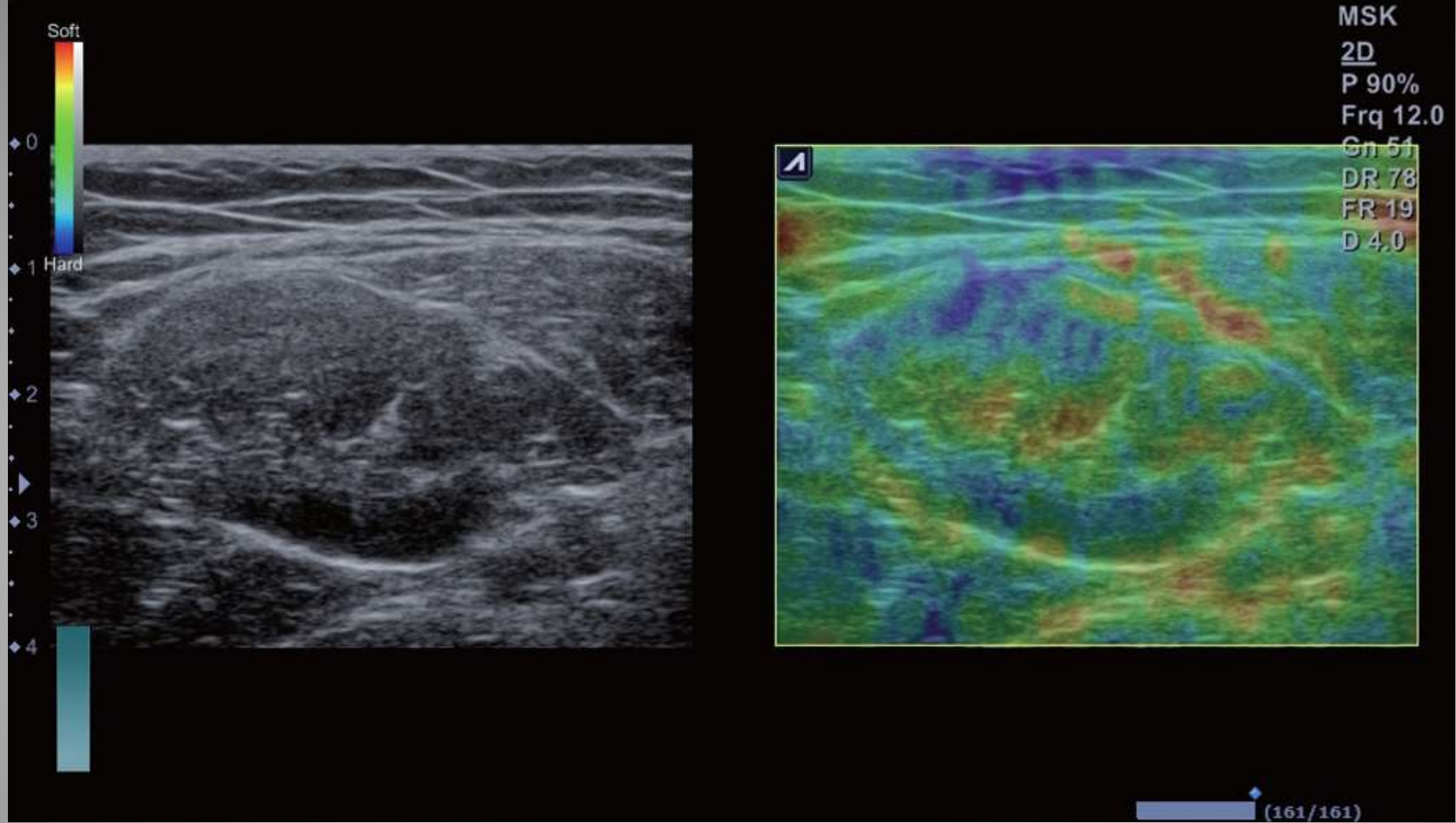
Hard



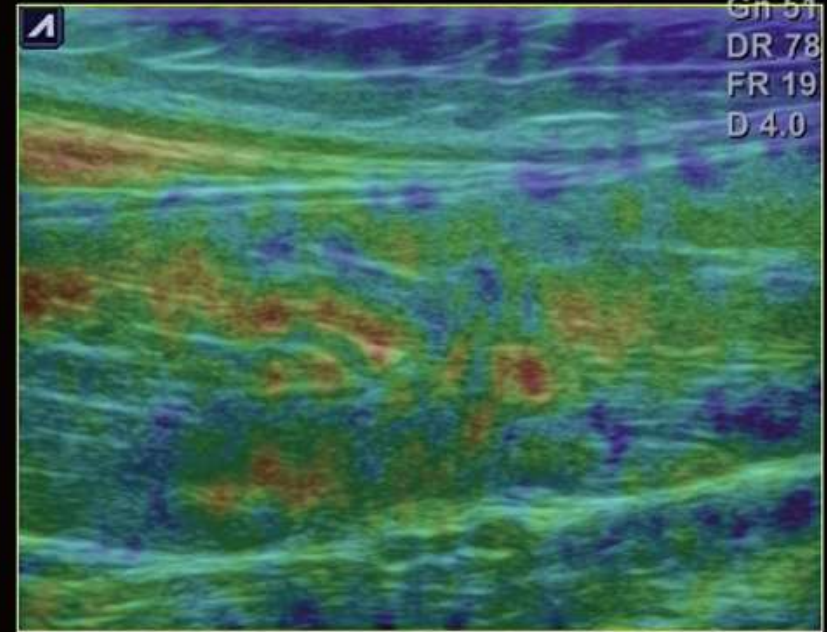
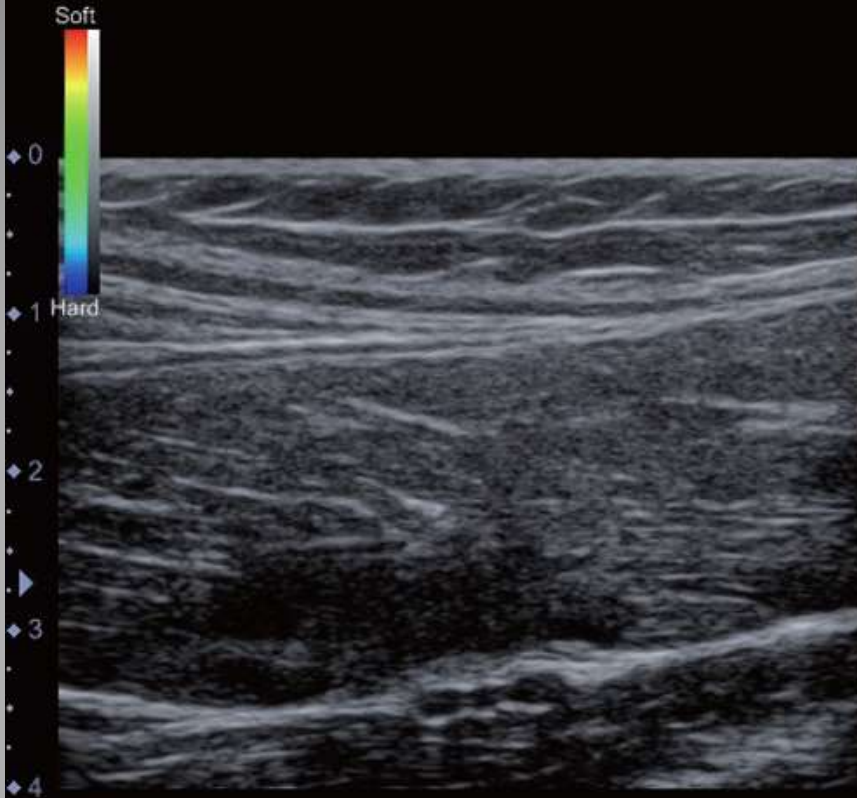
MSK
 2D
 P 90%
 Frq 12.0
 Gn 51
 DR 78
 FR 19
 D 4.0



- Initial Visit – Long axis view: Partial rupture in rectus femoris is more clearly identified with elastography mode than 2D mode, with the SR values of 3.2-3.64 measured from the site. Blue color mapping: Hard lesion



- Follow up – 3 months later: Short Axis view There was nothing more than partially reduced elasticity, as the SR values of 0.5-1.25 measured from the site.



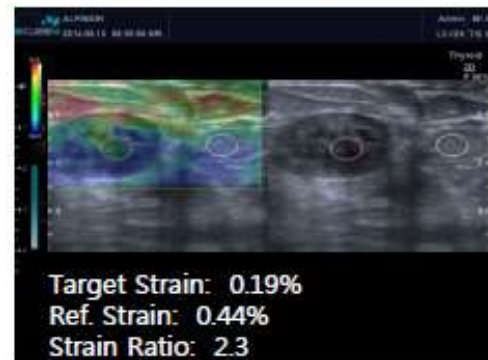
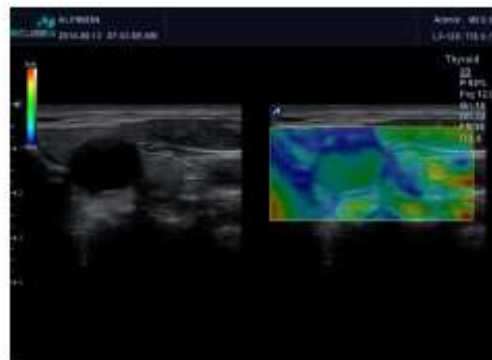
- Follow up – 3 months later: Long Axis view Partially reduced elasticity, as the SR values of 0.5-1.25 measured from the site. *Excerpted from The Korean Journal of Sports Medicine Images by courtesy of SH Choi, MD Yonsei SOL Sports and Orthopedics Rehabilitation Center, South Korea, Supported system: E-CUBE 15 V.3.0*

Elastography: MSK –Sports Medicine

- In terms of diagnosis and treatment of muscle injuries, it has been confirmed that real-time strain elastography can be utilized as an easier serial follow up tool for improvement of understanding such injuries and their healing process, as it is efficient in cost and time.
- Elastography can provide an accurate diagnosis of musculoskeletal injuries and may help prevent athletes from injuring themselves further during rehabilitation sessions, which can be a useful tool for evaluating when an athlete can return to training.

Elastography: Thyroid

- ▶ Thyroid nodules are very common, but less than 5% are malignant.
- ▶ Biopsy is typically conducted with fine-needle aspiration(FNA); some 300,000 thyroid biopsies are performed each year in the U.S. with 70% of these proving benign.
- ▶ For work-up of thyroid nodules, elastography has a high sensitivity and specificity in the evaluation of thyroid nodules.
 - >> FNA : sensitivity of 54-90%, specificity of 60-96%
 - >> Elastography: sensitivity of 92% and specificity of 90% for the diagnosis of malignant thyroid nodules.
- Thyroid, 2010 Oct;20(10):1145-50
 - >> Using a strain ratio(SR) elastography a significant association with malignancy at a cut-off $SR > 2.05$ and an accuracy in the diagnosis of nodules with indeterminate cytology, potentially aiding a presurgical selection.
- European Journal of Radiology, 2013

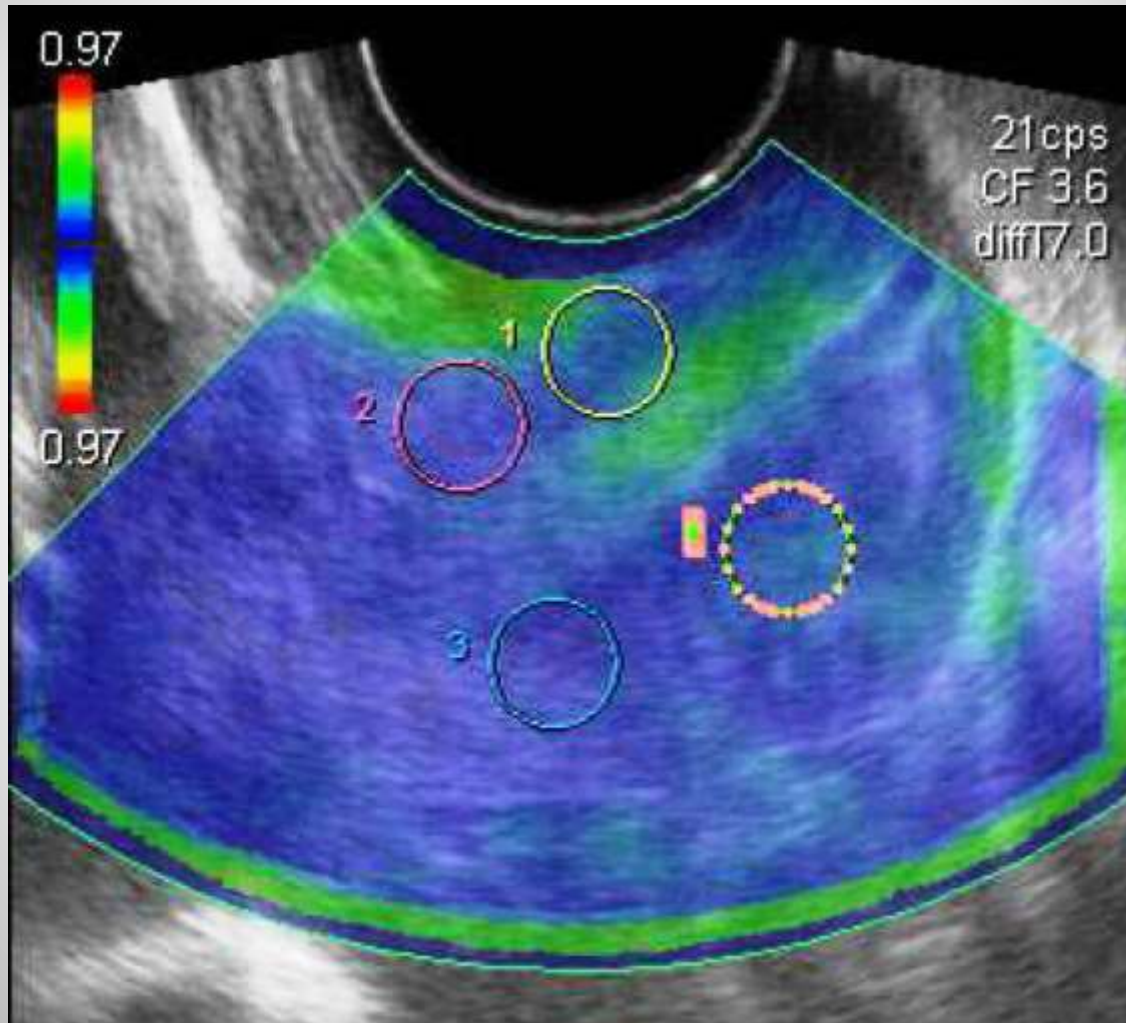


Cervix Elastography

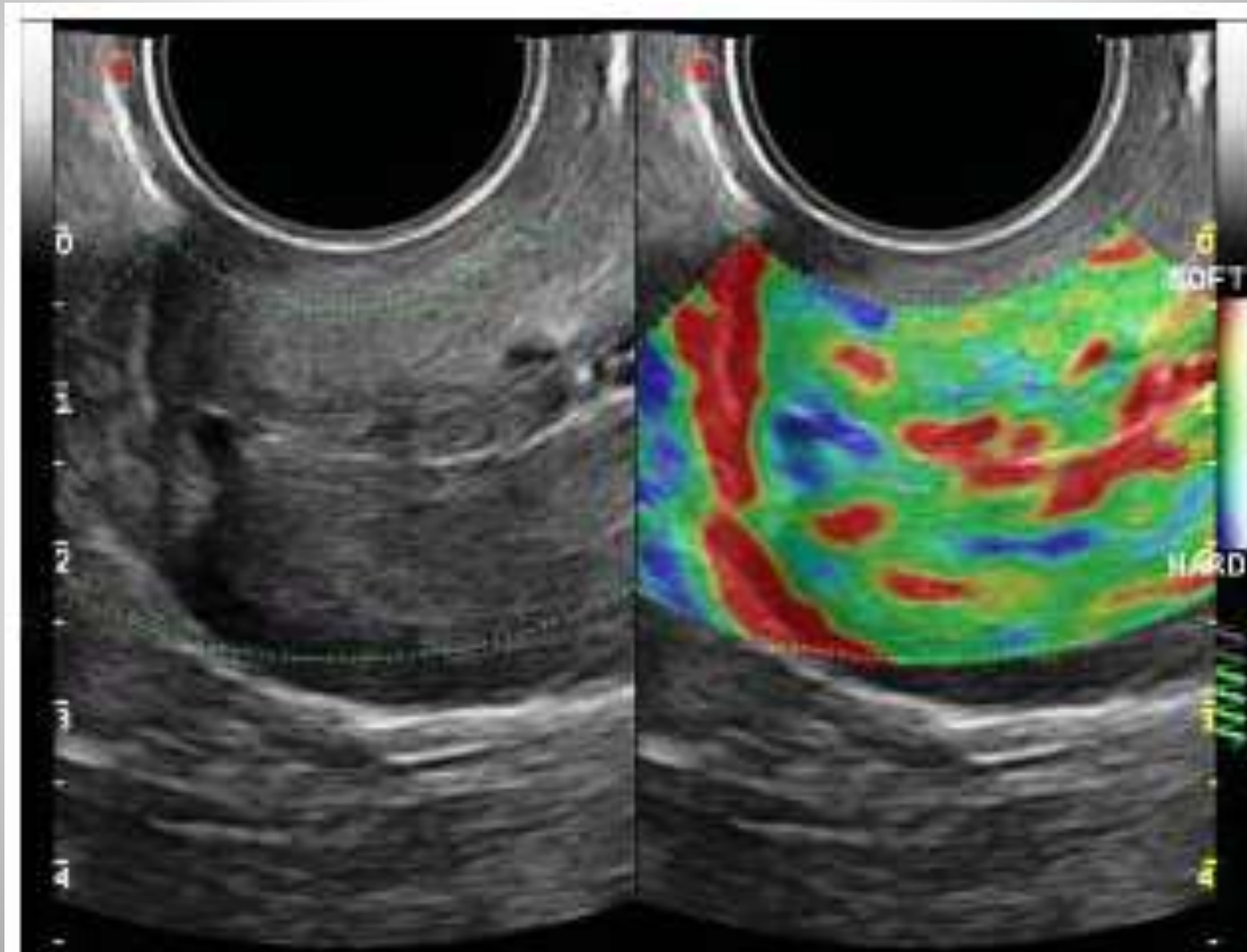
- Elastographic assessment of the internal cervical os at 18-22 weeks of pregnancy may identify patients with high risk of preterm delivery in low-risk, asymptomatic women.

Wozniak S, Czuczwar P(1), Szkodziak P, Milart P, Wozniakowska E, Paszkowski T. BMC Pregnancy Childbirth. 2014 Jul 21;14:238

Cervix Elastography



Cervix Elastography



Cervix elastography – labor induction

- Preliminary data show the possible usefulness of quantitative cervical elastography in the prediction of labor induction failure. *Fruscalzo A, Londero AP, Fröhlich C, Meyer-Wittkopf M, Schmitz R. Ultraschall Med. 2015 Feb;36(1):65-73*

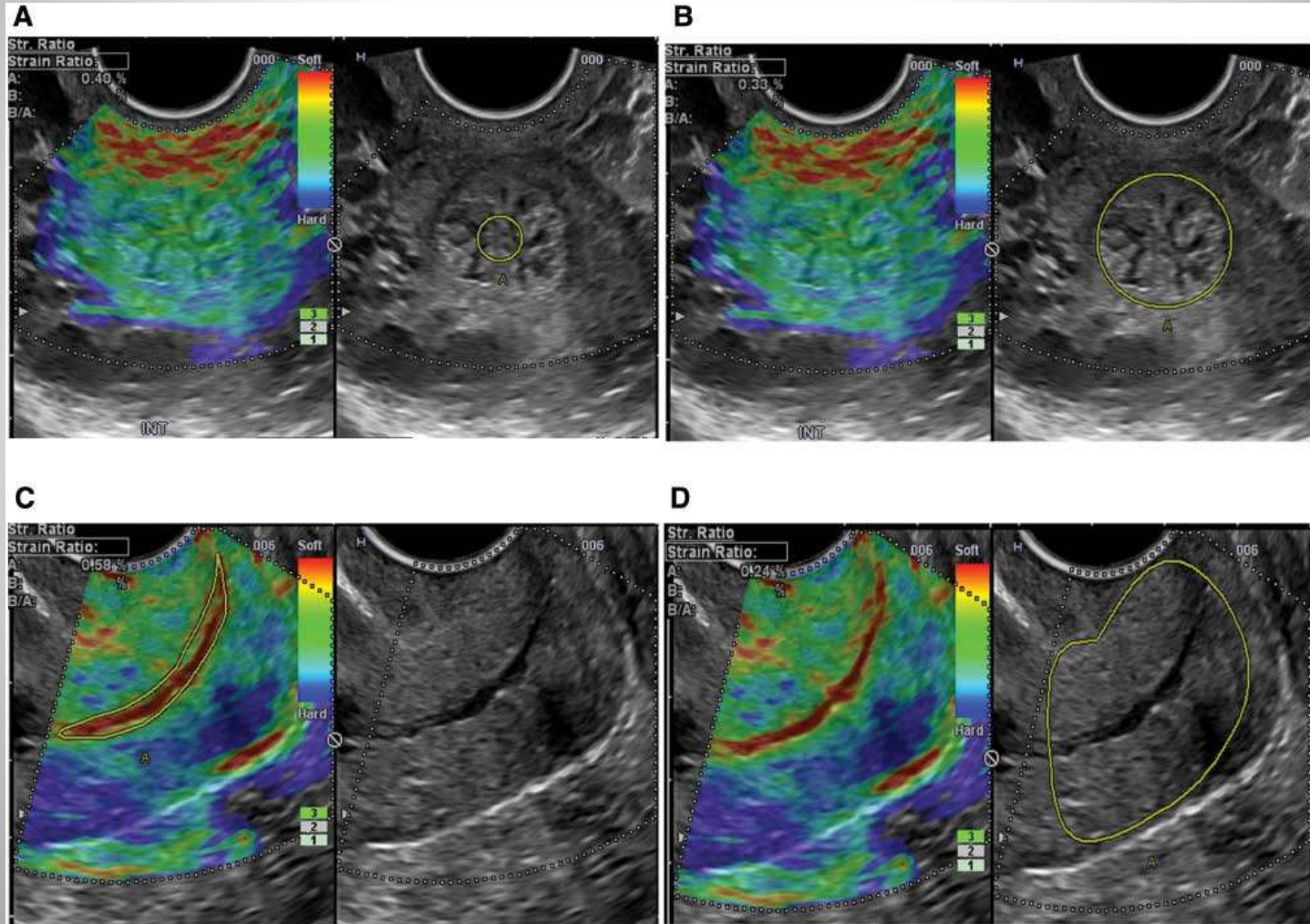
Cervix Elastography

- Elastography of the uterine cervix may be an objective method for assessment of softening of tissue in the region of the internal os before induction of labor. Standardization of the cervical properties observed on elastography during pregnancy may help to guide the use of prostaglandins or oxytocin for induction of labor. *Swiatkowska-Freund M, Preis K. Ultrasound Obstet Gynecol. 2011 Jul;38(1):52-6*

Cervix elastography – Preterm delivery prevention

- Low strain values in the internal cervical OS were associated with a significantly lower risk of spontaneous preterm delivery <37 weeks of gestation.
- Strain values obtained from the external cervical OS and from the sagittal view were not associated with sPTD. *Hernandez-Andrade E, Romero R, Korzeniewski SJ, Ahn H, Auriolles-Garibay A, Garcia M, Schwartz AG, Yeo L, Chaiworapongsa T, Hassan SS. J Perinat Med. 2014 Mar;42(2):159-69*

Cervix elastography – Preterm delivery prevention



Role of cervix elastography for preterm birth prevention

- 182 pregnant women were examined vaginally by ultrasound elastography from a mid-sagittal plane.
- Cervical length was measured and strain was calculated in four regions of interest on the anterior cervical lip.
- Strain ratio $R_{\text{selective}}$ was identified as the best predictor of preterm delivery. $R_{\text{selective}}$ values >0.89 were associated with preterm delivery with a sensitivity of 0.59 and a specificity of 0.86 $P=0.002$
- Ultrasound elastography strain measurement of cervical stiffness is correlated with the predictability of preterm delivery.

K Köbbing, A Fruscalzo, K Hammer, M Möllers, M Falkenberg, R Kwiecien, W Klockenbusch and R Schmitz Journal of Perinatology 34, 774-780 (October 2014)

THANK YOU!