

PELVIC ULTRASOUND  
A case of  
Retained Fetal Products  
or  
Retained Foreign Body

Liz Lawrence  
RDMS, RDCS, RVT

# History

35 year old female presents with pelvic pain and heavy menses x 3 yr

# History

35 year old female presents with pelvic pain and heavy menses x 3 yr

3 years ago she was forced to have an abortion while living in Turkey



# History

35 year old female presents with pelvic pain and heavy menses x 3 yr

3 years ago she was forced to have an abortion while living in Turkey

She has never had an IUD

Based on symptoms, the physician suspects Endometriosis –  
Orders Pelvic Ultrasound

Z-----

B	F	P	G	70%
TEI	D	12 cm		
	PRC	15-3-H	PRS	5
	PST	3		

GYNECOLO PA230

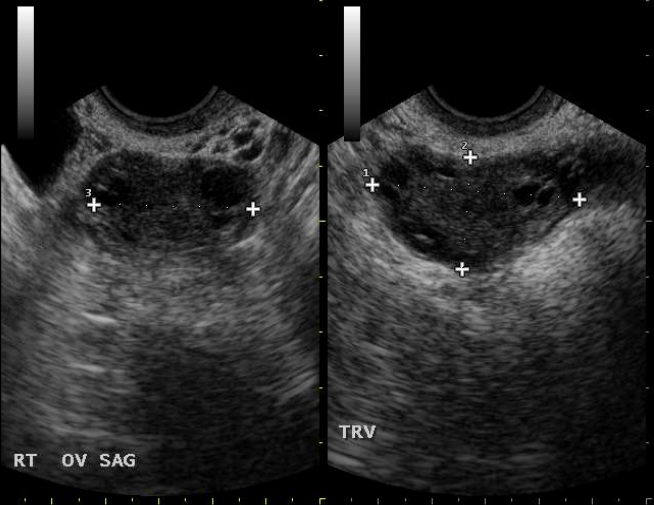


SAG UT ML

B F 6.6 MHz G 79%  
D 9 cm  
PRC 15-3-H PRS 5  
PST 3

FACTORY EC123

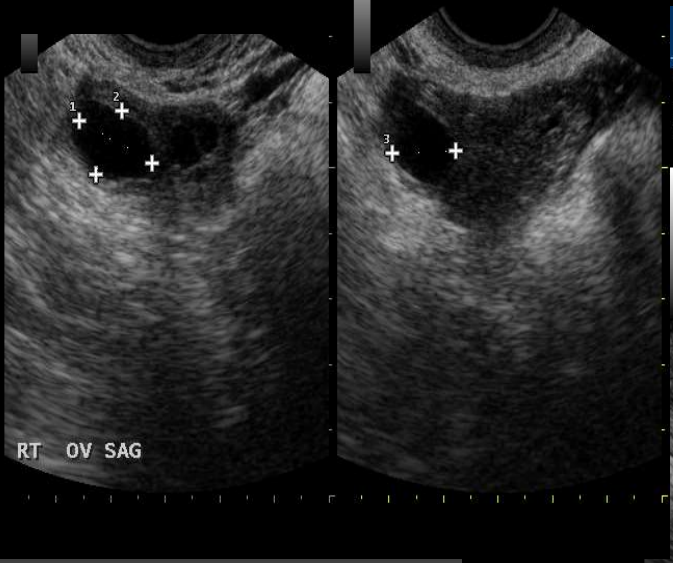D 1 3.88 cm  
D 2 2.03 cm  
D 3 2.98 cm



Right ovary normal with  
small follicular cyst

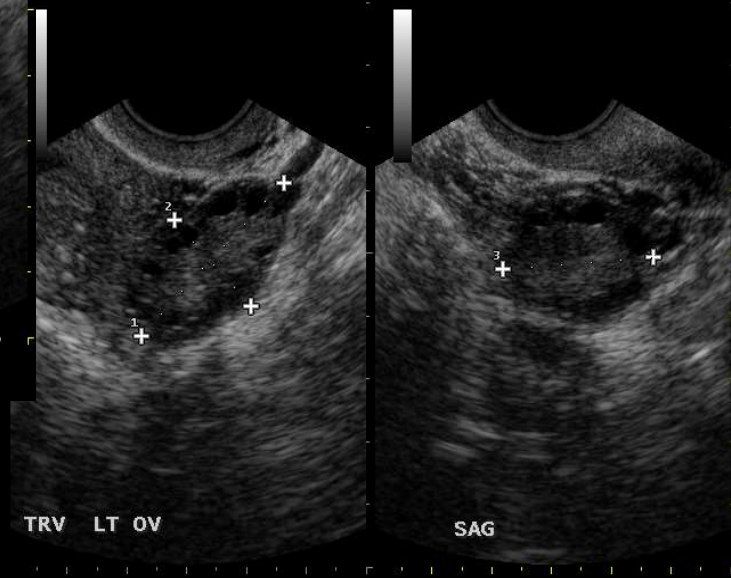
Left Ovary normal

10 08 2015 09:50



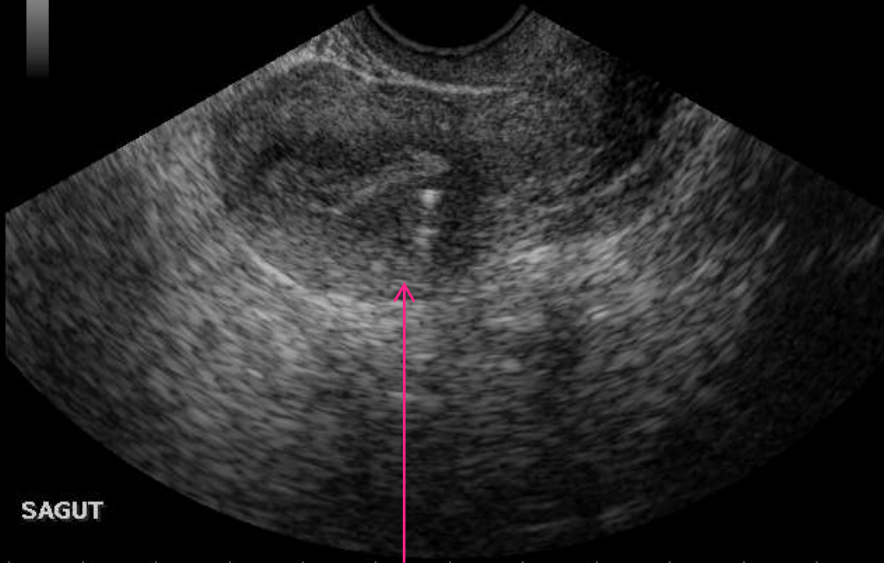
10 08 2015 09:48

6.6 MHz G 79%  
9 cm  
15-3-H PRS 5  
3



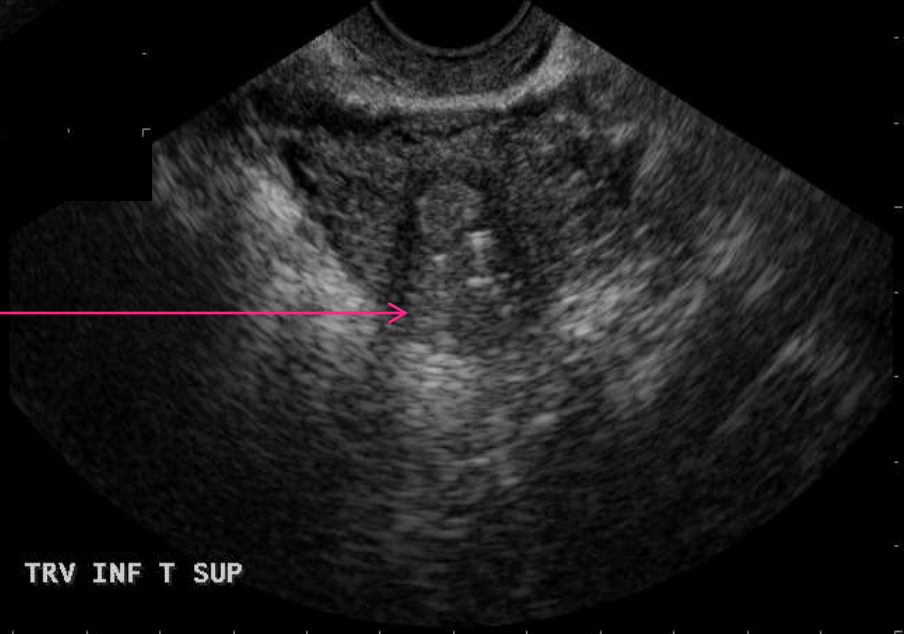
B F 6.6 MHz G 79%  
D 9 cm  
PRC 15-3-H PRS 5  
PST 3

FACTORY EC123



SAGUT

G 79%  
PRS 5



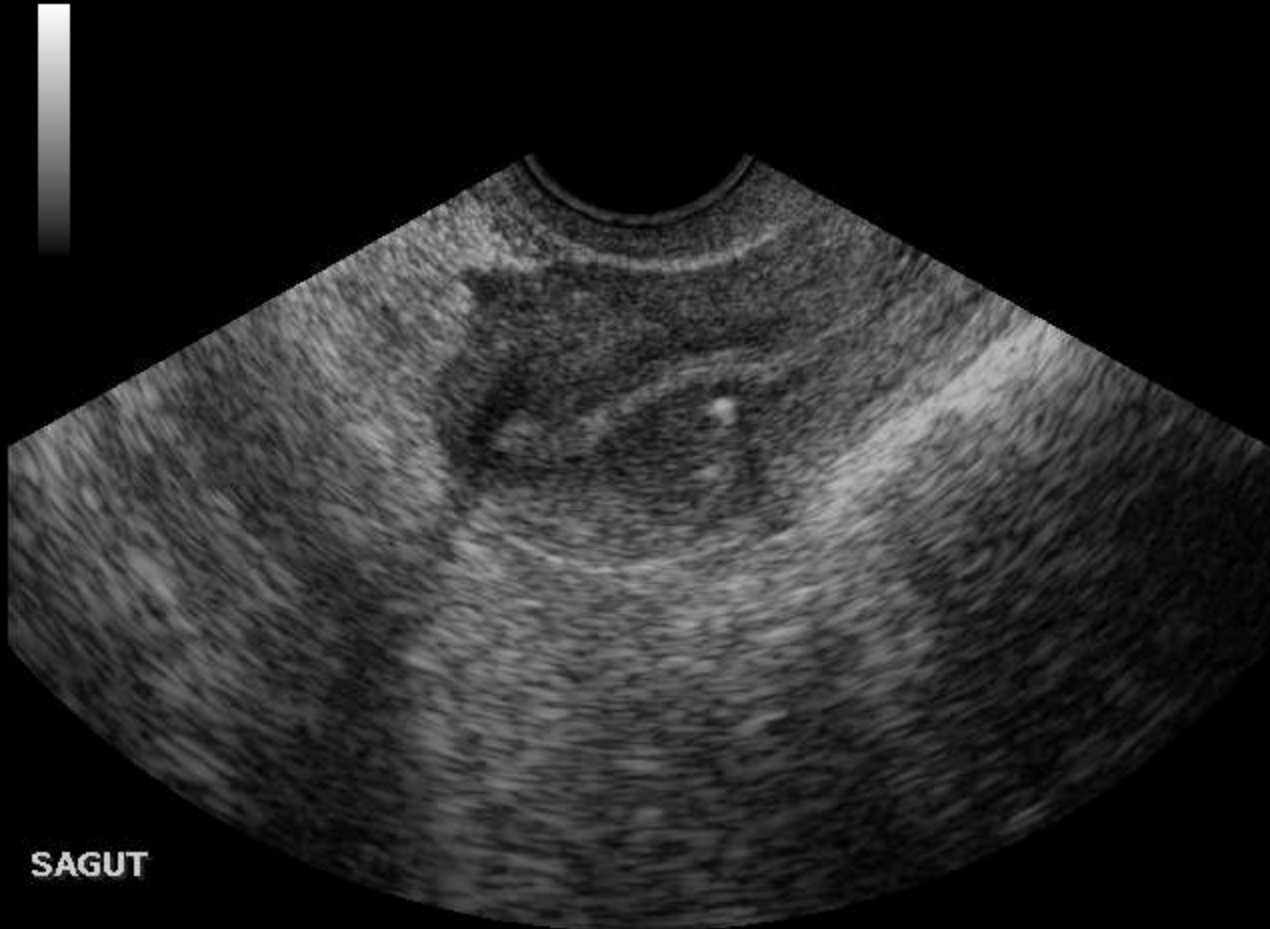TRV INF T SUP

Multiple echogenic foci  
lodged in the  
myometrium



Z-----  
B F 6.6 MHz G 79%  
D 9 cm  
PRC 15-3-H PRS 5  
PST 3

FACTORY EC123



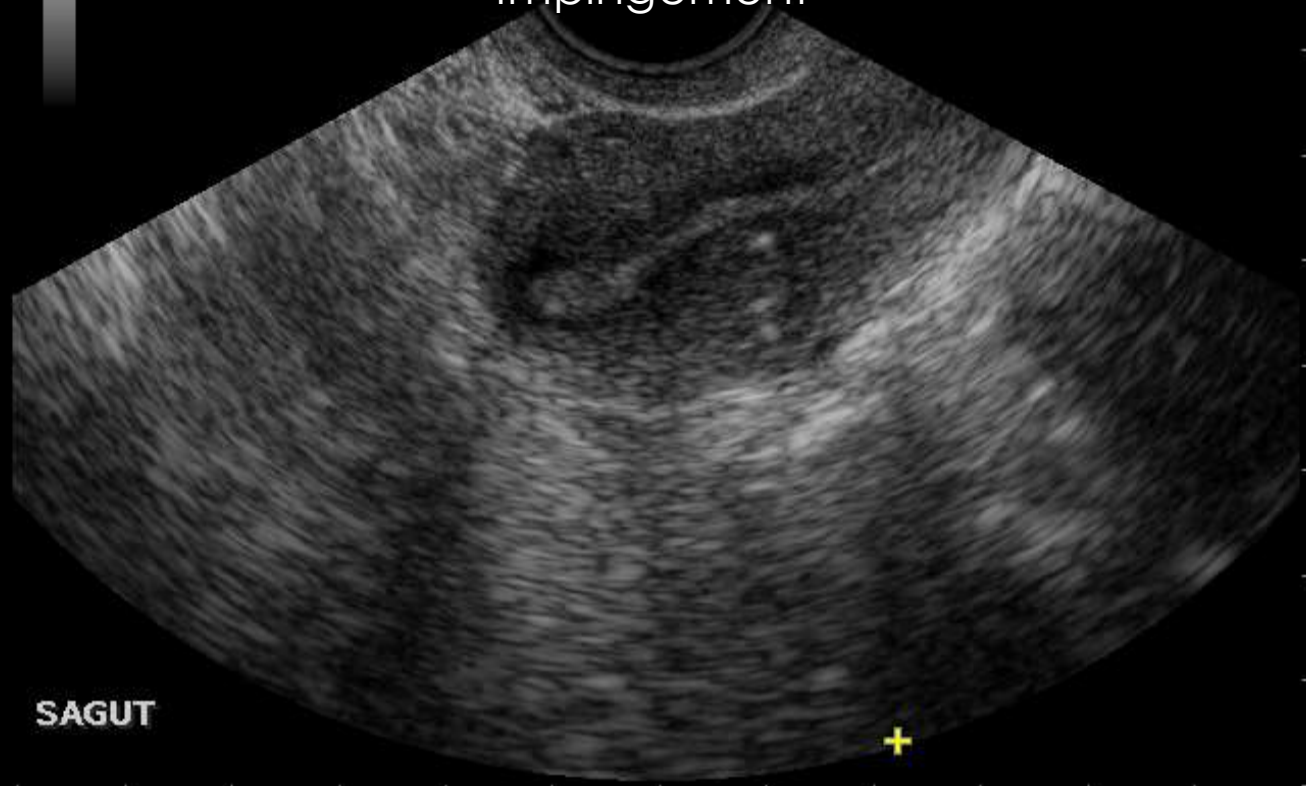
SAGUT

B F 6.6 MHz G 79%  
D 9 cm  
PRC 15-3-H PRS 5  
PST 3


FACTORY EC123  
D --- cm



Changes in the myometrium  
tissue density  
With appearance of endometrial  
Impingement



SAGUT

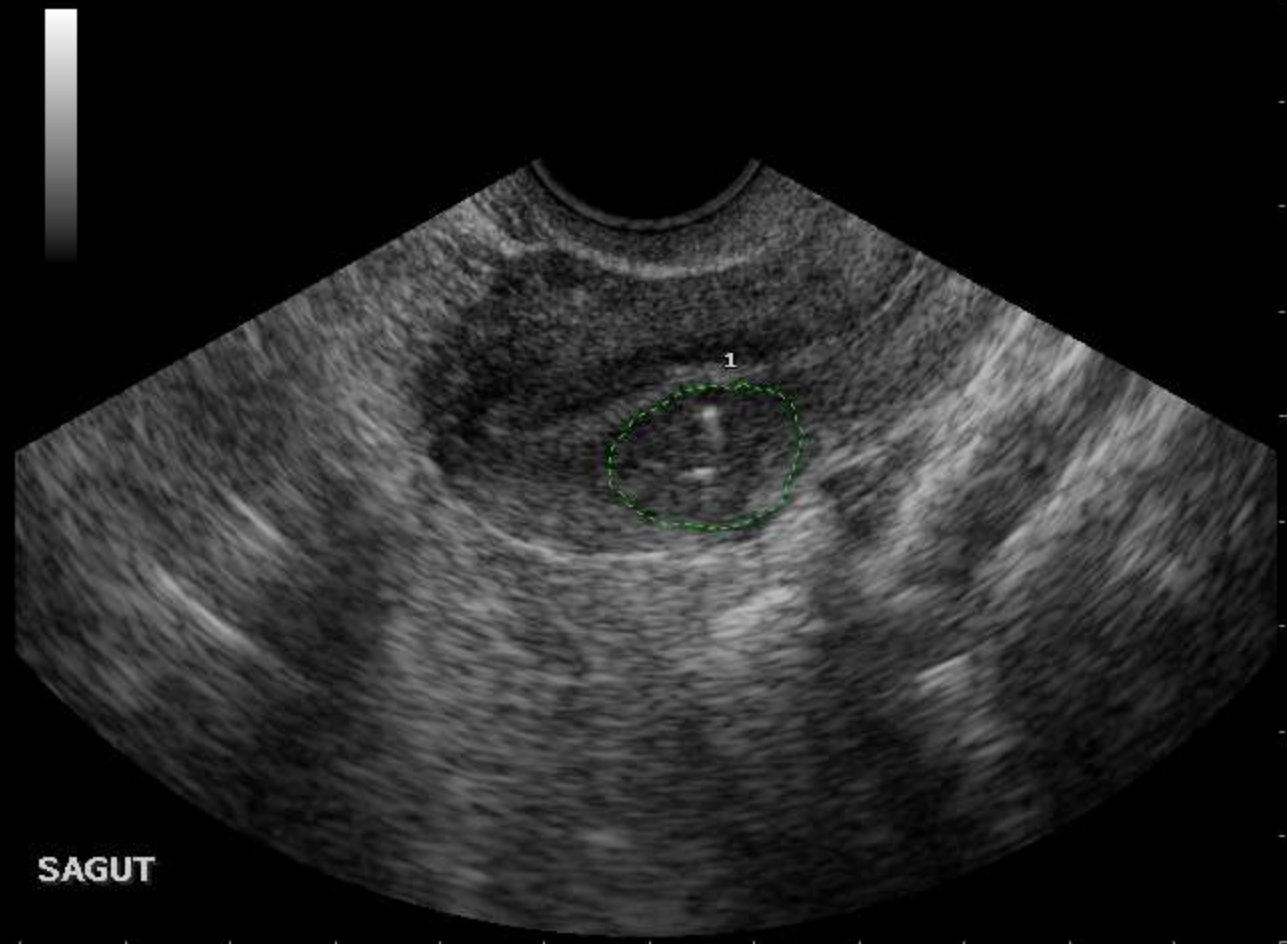


10

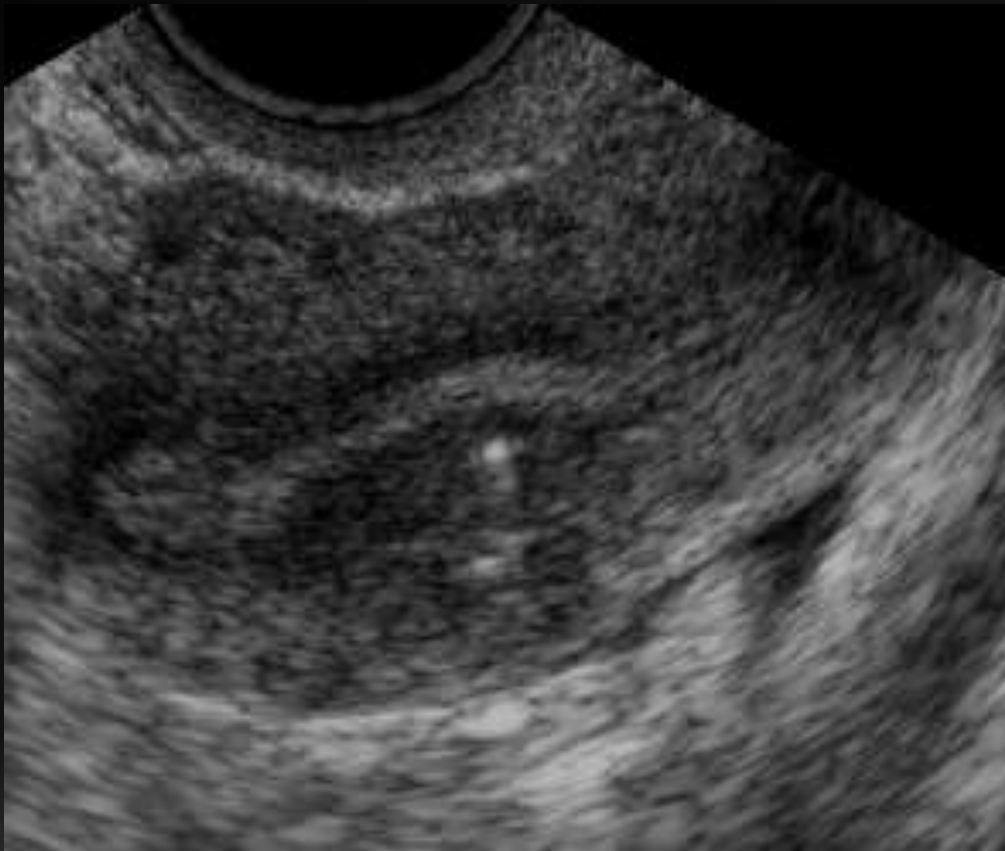Z-----  
B F 6.6 MHz G 79%  
D 9 cm  
PRC 15-3-H PRS 5  
PST 3

FACTORY EC123

A 1 1.95 cm<sup>2</sup>  
P 1 5.21 cm



SAGUT



X-ray was ordered;  
patient did not follow  
through with the x-ray

OR return to the office  
for physician follow up  
and consultation.

# Probable Diagnosis

**Retained fetal bones from abortion**

# Search of the literature

**Case Report: Retained intrauterine fetal bones: a rare cause of secondary infertility leading to diagnostic dilemma** A. K. Chowhan,<sup>1</sup> N. Rukmangadha,<sup>1</sup> K.V. Sreedhar Babu,<sup>2</sup> Rashmi Patnayak,<sup>1</sup> B.V. Phaneendra,<sup>1</sup> M. Varalakshmi Devi,<sup>3</sup> M. Kumaraswamy Reddy<sup>1</sup> Department of 1 Pathology and 2 Transfusion Medicine, Sri Venkateswara Institute of Medical Sciences, Tirupati and Department of 3 Obstetrics & Gynaecology, Lakshmishore Hospital, Proddatur

# Search of the literature

J Med Case Reports 2008:2:238

Published online 2008 June 17doi:10.1186/1752-1947-1-208

PMCID: PMC 2441636

**Secondary infertility caused by the retention of fetal bones after an abortion: a case report**

Hannah MC Kramer and Johann PT Rhemrev

Ghana Med J. 2006 Sep 40(3) :

105-109 PMCID: PMC 1790852

**Intrauterine Retained Fetal Bones as a cause of Secondary Infertility**

EK Srofenvoh, M Addison, B Dortei and PA Kuffour

# Possible alternative Diagnosis

## **Retained Foreign Body**

ie; surgical implements



# Search of the literature

## **Imaging of Retained Surgical Sponges in the Abdomen and Pelvis.**

Angus R. O'Connor<sup>1</sup>, Fergus V. Coakley<sup>2</sup>, Maxwell V. Meng<sup>3</sup> and Stephen Eberhardt<sup>4</sup>

<http://www.ajronline.org/doi/abs/10.2214/ajr.180.2.1800481>

## **RADIOGRAPHICS May 2003 Volume 23 Issue 3- Special Report: Foreign Bodies**

**Tim B. Hunter, MD, and Mihra S. Taljanovic, MD**

<sup>1</sup>From the Department of Radiology, University of Arizona Health Sciences Center, 1501 N Campbell Ave, Tucson, AZ 85724.

Ann Med Health Sci Res. 2014 Jan-Feb; 4(1): 30–37.

doi: [10.4103/2141-9248.126605](https://doi.org/10.4103/2141-9248.126605)

PMCID: PMC3952293

## **Retained Foreign Bodies: A Serious Threat in the Indian Operation Room**

[G Sharma](#) and [JC Bigelow](#)

**THANK YOU  
QUESTIONS/COMMENTS?**